

A Rare Cause of Pulmonary Embolism: Lead Fracture in an Unexpected Area

Ahmet Taha Şahin, Yakup Alsancak, Ahmet Lütfü Sertdemir, Mertcan Gezer

Department of Cardiology, Necmettin Erbakan University, Meram Faculty of Medicine, Konya, Türkiye

ABSTRACT

Background: Cardiac pacemakers are increasingly used in clinical cardiology practice for various indications. Lead fractures, though undesirable, are potential complications in patients with pacemakers.

Case Report: We present a case of a patient with a cardiac pacemaker, in whom a lead fracture was discovered during an investigation for the etiology of pulmonary embolism.

Conclusion: Cardiac pacemakers are invaluable in clinical practice. However, complications related to lead fractures can lead to additional clinical challenges in patients. Vigilance for such scenarios is crucial in the management of patients with pacemakers.

Keywords: Arrhythmias, CIED, echocardiography, pacemaker, pulmonary embolism.



Cite this article as:

Şahin AT, Alsancak Y, Sertdemir AL, Gezer M. A Rare Cause of Pulmonary Embolism: Lead Fracture in an Unexpected Area. J Clin Pract Res 2024; 46(1): 106–108.

Address for correspondence:

Ahmet Taha Şahin.
Department of Cardiology,
Necmettin Erbakan University,
Meram Faculty of Medicine,
Konya, Türkiye
Phone: +90 332 223 68 50
E-mail: tahasahin94@gmail.com

Submitted: 06.12.2023

Revised: 08.01.2024

Accepted: 12.01.2024

Available Online: 18.01.2024

Erciyes University Faculty of
Medicine Publications -
Available online at www.jcpres.com

INTRODUCTION

A 47-year-old male patient was admitted to our emergency department with symptoms of cough, weakness, and new-onset dyspnea. Initial evaluation revealed a submassive pulmonary embolism on computed tomography. The patient was immediately started on low molecular weight heparin (LMWH) by the emergency team. It was discovered that the patient had a single-chamber pacemaker implanted ten years prior, which was upgraded to a dual-chamber pacemaker in 2017 during a cardiology consultation. Echocardiography showed a normal ejection fraction, severe tricuspid regurgitation, high estimated systolic pulmonary artery pressure (70 mmHg), dilated right heart chambers, and a mobile pacemaker lead in the right ventricle. A chest X-ray revealed a fractured lead in the middle portion, confirming our diagnosis. Fluoroscopic examination observed that the right ventricular lead was broken at the level of the tricuspid valve and displaced towards the ventricle in a curved manner (Fig. 1). As expected, we observed increased threshold and impedance values in the ventricular lead, while the atrial lead remained normal during pacemaker interrogation. The patient's fluoroscopy images also confirmed that the ventricular lead was fractured.

CASE REPORT

During the patient's follow-up, no additional risk factors for pulmonary embolism were identified. Notably, the rationale for upgrading the pacemaker from a single-chamber to a dual-chamber at another hospital could not be determined due to the absence of the patient's old records. The



This work is licensed under
a Creative Commons
Attribution-NonCommercial
4.0 International License.

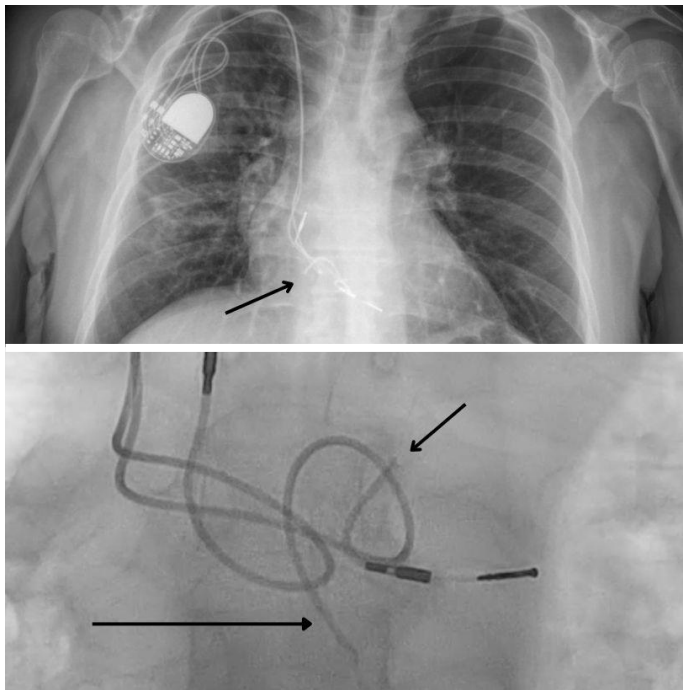


Figure 1. Images of the patient's lead fracture as seen in posteroanterior (PA) and anteroposterior (AP) radiographs and fluoroscopic examination.

patient was not currently pacemaker-dependent. The heart team decided to remove the fractured ventricular lead for two main reasons: firstly, the broken lead was considered the most likely cause of the pulmonary embolism and posed a risk of recurrence; secondly, the patient had chronic severe tricuspid regurgitation due to the lead fractures. The risks associated with pulmonary embolism were explained to the patient. Twelve hours after the last dose of LMWH, the fractured leads were removed, and new leads were implanted. No thrombus was observed on the lead. Throughout the 6-month follow-up, the patient reported no additional complaints, and no abnormalities were detected in subsequent pacemaker checks.

DISCUSSION

The incidence of lead fractures varies between 0.1% and 4.2% per patient-year, with the annual failure rate increasing over time post-implantation.¹ Patients under 50, those engaged in vigorous physical activities, women, and individuals with a higher left ventricular ejection fraction are at increased risk of lead fractures.² The most common area for lead fractures is between the first rib and clavicle, or in any anatomical abnormality that narrows the thoracic outlet, due to extrinsic pressure.³ In this case, the cause of the lead fracture within the atrium and ventricle may have been due to leaving excessive lead length.

Rare cases of pulmonary embolism associated with cardiac implantable electronic devices (CIEDs) have been reported, particularly with cardiac pacemakers used for treating cardiac arrhythmias.⁴ An endocardial lead acts as a foreign object in direct contact with the bloodstream, predisposing it to the development of a blood clot, which can potentially embolize and cause pulmonary embolism.⁵ In this case, the fractured lead, due to its increased mobility beyond the normal range, may have triggered the coagulation cascade by causing endocardial damage, leading to thrombus formation and pulmonary embolism. Thromboemboli associated with leads have been observed to migrate into the pulmonary circulation, resulting in asymptomatic or subclinical pulmonary embolism in as many as 48% of cases involving transvenous CIED leads.⁶

The patient's symptoms, pacemaker dependence, and the potential for additional complications caused by the fracture are important considerations when making decisions in patients with lead fractures.⁷ In some cases, the lead may be removed; in other cases, the fractured lead may be left in place due to the risk of perforating or damaging the tricuspid valve during removal.⁸ However, in such cases, it is important to also consider potential causes of the fractured electrode, including arrhythmias and interference with new leads.⁹

CONCLUSION

While cardiac pacemakers are highly beneficial in routine clinical practice, incidents affecting the leads can introduce additional complexities for patients. Lead fractures are a significant clinical concern in individuals under pacemaker monitoring, emphasizing the importance of prompt diagnosis and intervention to mitigate potential complications.

Peer-review: Externally peer-reviewed.

Informed Consent: Written informed consent was obtained from patient's family who participated in this study.

Author Contributions: Concept – ATŞ; Design – YA; Supervision – ALS; Resource – MG; Materials – ATŞ, MG; Data Collection and/or Processing – ATŞ, MG; Analysis and/or Interpretation – YA; Literature Search – YA, ALS; Writing – ATŞ; Critical Reviews – YA.

Conflict of Interest: The authors have no conflict of interest to declare.

Financial Disclosure: The authors declared that this study has received no financial support.

REFERENCES

1. Ansari M, Udyavar A. Successful resolution of clots on the pacemaker lead by warfarin therapy. *IJH Cardiovascular Case Reports (CVCR)* 2018; 2(1): 1–3. [\[CrossRef\]](#)
2. Coleman DB, DeBarr DM, Morales DL, Spotnitz HM.

- Pacemaker lead thrombosis treated with atrial thrombectomy and biventricular pacemaker and defibrillator insertion. *Ann Thorac Surg* 2004; 78(5): e83–4.
3. Buttigieg J, Asciak R, Azzopardi CM. Pacemaker lead-associated thrombosis in cardiac resynchronisation therapy. *BMJ Case Rep* 2015; 2015: bcr2015210314. [\[CrossRef\]](#)
 4. Voukalis C, Ionescu A, Barry J, Margulescu AD. An unusual cause of cerebral embolism: PFO-Straddling, spontaneously fractured pacemaker lead. *JACC Case Rep* 2022; 4(14): 854–6. [\[CrossRef\]](#)
 5. Noheria A, Ponamgi SP, Desimone CV, Vaidya VR, Aakre CA, Ebrille E, et al. Pulmonary embolism in patients with transvenous cardiac implantable electronic device leads. *Europace* 2016; 18(2): 246–52. [\[CrossRef\]](#)
 6. Martinez-Sellés M, Bueno H, Almendral J, Diaz-Castro O. Pulmonary embolism after pacemaker implantation. *Tex Heart Inst J* 2001; 28(4): 318–9.
 7. Swerdlow CD, Kalahasty G, Ellenbogen KA. Implantable cardiac defibrillator lead failure and management. *J Am Coll Cardiol* 2016; 67(11): 1358–68. [\[CrossRef\]](#)
 8. Howe AJ, McKeag NA, Wilson CM, Ashfield KP, Roberts MJ. Insulation failure of the linx defibrillator lead: A case report and retrospective review of a single center experience. *J Cardiovasc Electrophysiol* 2015; 26(6): 686–9. [\[CrossRef\]](#)
 9. Mulpuru SK, Pretorius VG, Birgersdotter-Green UM. Device infections: management and indications for lead extraction. *Circulation* 2013; 128(9): 1031–8. [\[CrossRef\]](#)