





## Moyamoya Disease with Syphilis: A Case Report

 Burcu Zeytun,<sup>1</sup>  Aylin Güney,<sup>1</sup>  Zeynep Toprak,<sup>1</sup>  Bilge Sena Eşman,<sup>1</sup>  
 Elfin Demirtaş,<sup>1</sup>  Sezgin Kehaya<sup>2</sup>

<sup>1</sup>Trakya University Faculty of Medicine, Edirne, Türkiye

<sup>2</sup>Department of Neurology, Trakya University Faculty of Medicine, Edirne, Türkiye

### ABSTRACT

**Background:** Moyamoya disease is an uncommon cerebrovascular disorder. There is speculation that syphilis may induce Moyamoya disease; however, literature on this association is sparse.

**Case Report:** We describe the case of a 43-year-old female with syphilis who experienced three ischemic strokes. Angiography revealed a “puff of smoke” pattern, diagnostic of Moyamoya. The patient underwent antiplatelet therapy following antibiotic treatment for syphilis. Despite conservative management, there was no clinical improvement. Consequently, the patient was referred for neurosurgical intervention and underwent burr hole surgery to treat Moyamoya disease.

**Conclusion:** There are no definitive conclusions regarding whether the patient’s primary complaints stem from syphilis or Moyamoya disease. To our knowledge, this case represents the second instance where Moyamoya disease and syphilis have been reported concurrently. This case suggests that syphilis should be considered as a potential factor in patients presenting with Moyamoya disease.

**Keywords:** Moyamoya disease, syphilis, stroke, cerebral infarction, internal carotid artery.



#### Cite this article as:

Zeytun B, Güney A, Toprak Z, Eşman BS, Demirtaş E, Kehaya S. Moyamoya Disease with Syphilis: A Case Report. J Clin Pract Res 2024; 46(2): 000–00.

#### Address for correspondence:

Burcu Zeytun.  
Trakya University Faculty of Medicine, Edirne, Türkiye  
**Phone:** +90 284 235 76 41  
**E-mail:** zeytunburcu@gmail.com

**Submitted:** 17.10.2023

**Revised:** 15.01.2024

**Accepted:** 06.03.2024

**Available Online:** 15.04.2024

Erciyes University Faculty of Medicine Publications - Available online at [www.jcpres.com](http://www.jcpres.com)



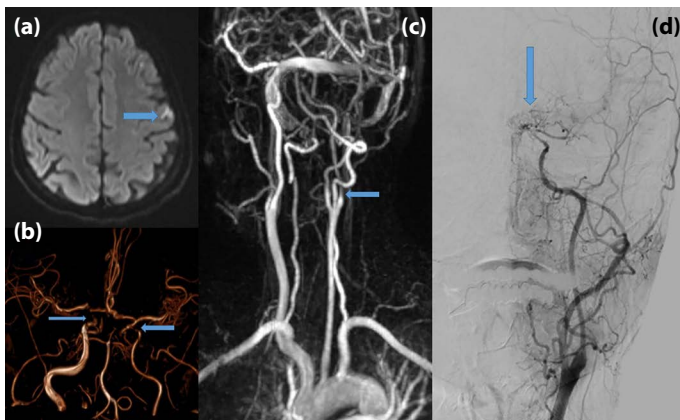
This work is licensed under a Creative Commons Attribution-NonCommercial 4.0 International License.

### INTRODUCTION

Moyamoya disease is a rare anomaly affecting cerebral circulation, characterized by chronic progressive stenosis of the supraclinoid internal carotid artery and the arteries forming the polygon of Willis.<sup>1</sup> This condition results from the blockage or stenosis of the internal carotid arteries on both sides. The collateral fine vascular network system that forms at the base of the brain and at the level of the basal ganglia gives the disease its characteristic “smoky” appearance on angiography. This appearance is defined by the Japanese word “Moyamoya,” which means “blown cigarette smoke.”

The clinical symptoms of Moyamoya disease are variable. In the juvenile form, focal motor and sensory functions are lost due to transient ischemic attacks, while in the adult form, intracranial hemorrhage and cerebrovascular insufficiency are observed.<sup>2</sup>

Although the etiology of Moyamoya disease is still unclear, studies have indicated that it progresses with or follows congenital, genetic, and tumoral diseases.<sup>1</sup> As in our patient’s case,

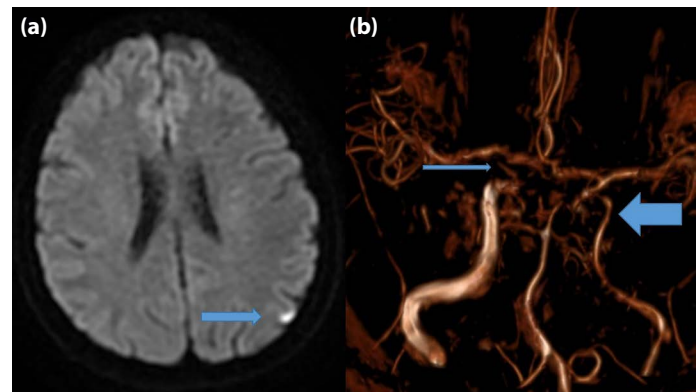


**Figure 1. (a)** DWI MRI showing left cortical hyperintensity. **(b)** TOF MR-Angiography: Arrows pointing to a cavernous ICA. **(c)** Cervical MR-Angiography: Arrow indicating the left ICA at the bifurcation. **(d)** Digital Subtraction Angiography: Arrow highlighting the Moyamoya appearance at the level of the cavernous ICA.

syphilis is another disease that can precede Moyamoya disease. Caused by the bacterium *Treponema pallidum*, syphilis can be transmitted sexually, transplacentally, through contact with an open wound, or by blood transfusion. If left untreated, it can lead to severe complications and internal organ involvement. It is observed in sexually active individuals of both genders.<sup>3</sup>

## CASE REPORT

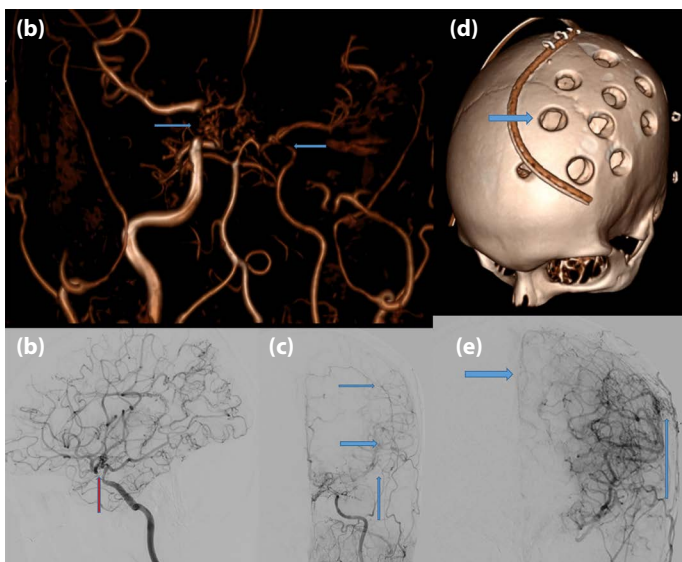
A 37-year-old female patient presented to our Trakya University Training and Research Hospital's neurology clinic with complaints of left-sided throbbing headaches, slurred speech, and a leftward shift in the mouth. The patient reported that the speech lisp lasted for approximately half an hour at a time, occurred several times throughout the day, and that her symptoms had been gradually improving. She has a history of diabetes and has been using Lantus 6 IU and NovoRapid 6-8-10 IU. It was noted that she does not consume alcohol, but she has been smoking a pack of cigarettes every two days for the past 20 years. Based on her symptoms, a preliminary diagnosis of transient cerebral ischemic attacks with motor aphasia was made. She was prescribed dual antiplatelet therapy with clopidogrel 75 mg and acetylsalicylic acid 100 mg daily. Additionally, she was given atorvastatin 20 mg/day for hyperlipidemia, and her insulin levels were regulated. Diffusion-Weighted Magnetic Resonance Imaging (MRI) showed left frontal cortical hyperintensity. Both cavernous internal carotid arteries (ICAs) were narrowed on cerebral angiography, and the left ICA showed low calibration post-bifurcation (Fig. 1a–c). Digital subtraction angiography



**Figure 2. (a)** DWI MRI depicting left cortical hyperintensity. **(b)** TOF MR-Angiography: Thin arrow showing the occluded right cavernous ICA, thick arrow indicating left ICA narrowing.

revealed a Moyamoya-like appearance at the cavernous segment of the ICA (Fig. 1d).

Extensive investigations for etiology revealed no cardiac pathology or diathesis for thrombosis. The patient was tested for vasculitis, with positive Venereal Disease Research Laboratory (VDRL) and Hep-2 Antinuclear Antibody (HEP-2 ANA) results. Given the positive VDRL, a *Treponema Pallidum* Hemagglutination Assay (TPHA) test was conducted and found to be significant. The department of infectious diseases was consulted due to suspicion of infection, despite no reported sexual activity, anamnesis, or chancre in the patient or their partner. Subsequently, a Fluorescent *Treponemal* Antibody Absorption (FTA-ABS) test was sent to an external center for a detailed examination, and a Lumbar Puncture (LP) was performed. The Cerebrospinal Fluid (CSF) protein level was 62 mg/dl, sugar 55 mg/dl, and eight lymphocytes were observed. Thoracic MRI angiography, conducted to assess for vasculitis, showed that the aorta, arcus aorta, and thoracic aorta were normal. After a positive FTA-ABS result, both the patient and her husband underwent antibiotic therapy. The patient was diagnosed with cerebrovascular disease due to syphilis-induced vasculitis. Her dual antiplatelet therapy was reduced to a single agent, continuing with clopidogrel at the third month. Ten months later, she presented with right-sided hemiparesis with 4/5 muscle strength and mild dysarthria. Her headaches persisted, and she continued to smoke. Diffusion-Weighted Imaging (DWI) MRI indicated left cortical acute ischemia, occlusion of the right cavernous ICA, and progression of the left intracranial ICA narrowing on MR angiography (Fig. 2). VDRL tested negative. She was placed back on dual antiplatelet therapy and advised to quit smoking.



**Figure 3.** (a) MR-Angiography showing progression of ICA narrowing. (b) DSA demonstrating progression of ICA narrowing. (c) DSA: Arrows indicating anastomoses between external and internal carotid branches. (d) 3D CT Skull: Image of the patient after surgery. (e) DSA of External Carotid Artery: Showing abundant collaterals to the Middle and Anterior Cerebral Arteries.

Despite optimal medical treatment, she experienced three episodes of right-sided hemiparesis and transient ischemic attacks over two years. Her headaches worsened, and she did not respond to steroid therapy. No rheumatologic or cardiac diseases were diagnosed during this period. The narrowing of the cavernous ICAs progressed (Fig. 3a, b), and intra-extracranial anastomosis developed over time (Fig. 3c). We concluded that the patient had Moyamoya disease and was unresponsive to medical treatment. Therefore, she was referred to neurosurgery, where burr-hole surgery was performed to promote intra-extracranial anastomosis (Fig. 3d). Six months after the surgery, she experienced no ischemic attacks, and her headaches had eased. An increase in collateral anastomoses was observed on her angiography (Fig. 3e).

## DISCUSSION

Moyamoya disease and syphilis are rare causes of strokes in young individuals. Although syphilis is one of the diseases associated with Moyamoya disease, there are insufficient reports in the literature describing the co-occurrence of Moyamoya and syphilis. We present this patient as it represents only the second case to describe both Moyamoya disease and syphilis.<sup>4</sup> The treatment process for Moyamoya lacks definitive guidelines, and this report aims to examine the treatment approach for our patient.

We considered our patient to have experienced a stroke due to syphilitic arteritis, given her young age and the diffuse arterial involvement. However, the arterial narrowing progressed even after treating the infection. This raises the question: Was our case solely Moyamoya disease from the start, or did syphilitic arteritis cause the progressive arterial narrowing? This is a matter of debate.

According to the latest stroke management guidelines, the use of antiplatelet agents is recommended for all ischemic strokes not caused by cardioembolic sources. We administered dual antiaggregant therapy to our patient diagnosed with syphilitic arteritis, who also received antibiotic therapy for syphilis. Syphilis may not have been the primary issue, as the patient's symptoms did not improve despite the medications used. The "puff of smoke" appearance consistent with Moyamoya, observed on cerebral angiography, necessitated treatment for Moyamoya.<sup>5</sup>

Moyamoya disease currently lacks a radical cure, but surgical intervention offers more benefits than conservative treatment, particularly in terms of enhancing cerebral perfusion. Cerebral perfusion significantly affects neurological function. For symptomatic Moyamoya disease, surgical therapy is associated with a lower rate of secondary strokes compared to conservative treatment. The mortality rate from bleeding with conservative treatment was approximately four times higher than with surgical treatment.<sup>6</sup> Burr hole surgery is recognized for its effectiveness in revascularizing ischemic brain tissue in adults. Given these considerations, burr hole surgery was chosen for our patient's treatment of Moyamoya.

From the initial diagnosis to the operation, approximately four years elapsed. During this period, conservative treatment was attempted without any improvement in symptoms, leading to the decision for surgical intervention. Although the general principle is to minimize the time between diagnosis and revascularization current guidelines provide no definitive recommendation on the timing of surgery.<sup>7</sup>

## CONCLUSION

We remain uncertain whether the primary source of the patient's complaints is Moyamoya or syphilis. It is possible that she developed syphilis after acquiring Moyamoya, or syphilis may have precipitated Moyamoya. There are no clear guidelines for treating Moyamoya disease. It is important to increase the reporting of Moyamoya cases to facilitate further research. Additionally, we recommend that clinicians evaluate for syphilis in patients with Moyamoya, as highlighted by the case we have reported.

**Informed Consent:** Written informed consent was obtained from patients who participated in this study.

**Author Contributions:** Concept – BZ, AG, ZT, BSE, ED, SK; Design – BZ, AG, ZT, BSE, ED, SK; Supervision – BZ, AG, ZT, BSE, ED, SK; Data Collection and/or Processing – BZ, AG, ZT, BSE, ED, SK; Analysis and/or Interpretation – BZ, AG, ZT, BSE, ED, SK; Literature Search – BZ, AG, ZT, BSE, ED, SK; Writing – BZ, AG, ZT, BSE, ED, SK; Critical Reviews – BZ, AG, ZT, BSE, ED, SK.

**Conflict of Interest:** The authors have no conflict of interest to declare.

**Use of AI for Writing Assistance:** Not declared.

**Financial Disclosure:** The authors declared that this study has received no financial support.

**Peer-review:** Externally peer-reviewed.

## REFERENCES

1. Aydoğan MS, Yücel A, Özgül Ü, Öztürk E, Konur H, Öztanır MN, et al. Anesthetic approach to adult moyamoya disease: a case report. *Gulhane Med J* 2010; 52: 212–5.
2. Gezen F, İş M. Moyamoya disease. *Turkiye Klinikleri J Surg Med Sci* 2006; 2(16): 180–4.
3. Karaosmanoğlu N, İmren Baskovski IG, Karaaslan E, Kıratlı E, Ekşioğlu HM. Dermatoloji kliniğine son iki yılda başvuran sifiliz olgularının değerlendirilmesi. *Ankara Eğitim ve Araştırma Hastanesi Tıp Dergisi* 2019; 52(1): 69–73.
4. Morgello S, Laufer H. Quaternary neurosyphilis in a Haitian man with human immunodeficiency virus infection. *Hum Pathol* 1989; 20(8): 808–11.
5. Wiśniewski A. Multifactorial background for a low biological response to antiplatelet agents used in stroke prevention. *Medicina (Kaunas)* 2021; 57(1): 59.
6. Li Q, Gao Y, Xin W, Zhou Z, Rong H, Qin Y, et al. Meta-analysis of prognosis of different treatments for symptomatic moyamoya disease. *World Neurosurg* 2019; 127: 354–61.
7. Guey S, Tournier-Lasserre E, Hervé D, Kossorotoff M. Moyamoya disease and syndromes: from genetics to clinical management. *Appl Clin Genet* 2015; 8: 49–68.