

Mapping the Azygos System: An Evaluation from Age and Sex Perspectives

İD Gülsüm Derya Aktaş,¹ İD Mustafa Koplay,² İD Ahmet Kağan Karabulut,³
İD Muzafer Sindel⁴

¹Department of Anatomy, İzmir Democracy University, Faculty of Medicine, İzmir, Türkiye

²Department of Radiology, Selçuk University, Faculty of Medicine, Konya, Türkiye

³Department of Anatomy, Selçuk University, Faculty of Medicine, Konya, Türkiye

⁴Department of Anatomy, Akdeniz University, Faculty of Medicine, Antalya, Türkiye

ABSTRACT

Objective: The azygos system serves as a vital pathway between the superior and inferior vena cava in cases of obstruction. Despite its significance, there is a lack of detailed imaging studies describing its anatomy. Accurate characterization of its appearance and dimensions on computed tomography is essential, as it may be mistaken for lymph nodes or masses. This study aimed to define the azygos system using computed tomography.

Materials and Methods: Thoracic computed tomography images from 300 individuals (aged 18-87 years) were analyzed. The study assessed the level at which the azygos vein drains into the superior vena cava, the highest point of the azygos arch, and the course and diameter of the azygos vein. Additionally, the presence, termination levels, and diameters of the hemiazygos and accessory hemiazygos veins were recorded.

Results: The azygos vein most commonly drained into the superior vena cava at the level of the fifth thoracic vertebra. In only 23 individuals did the azygos vein course on the right of the midline. The mean diameters of the azygos, hemiazygos, and accessory hemiazygos veins were 6.37 mm, 3.95 mm, and 3.12 mm, respectively.

Conclusion: This study is significant in demonstrating that the junction of the azygos vein with the superior vena cava junction most commonly occurs at the level of the fifth thoracic vertebra. Additionally, the azygos vein reaches the midline in 53% of cases and crosses to the left in 39%.

Keywords: Anatomy, azygos vein, computed tomography, thoracic surgery, thorax.



Cite this article as:

Aktaş GD, Koplay M, Karabulut AK, Sindel M. Mapping the Azygos System: An Evaluation from Age and Sex Perspectives. J Clin Pract Res 2025;47(3):252–261.

Address for correspondence:

Muzafer Sindel.
Department of Anatomy,
Akdeniz University Faculty of
Medicine, Antalya, Türkiye
Phone: +90 242 249 60 00
E-mail: sindelm@akdeniz.edu.tr

Submitted: 03.01.2025

Revised: 20.01.2025

Accepted: 02.05.2025

Available Online: 23.05.2025

Erciyes University Faculty of
Medicine Publications -
Available online at www.jcpres.com

INTRODUCTION

The azygos system holds considerable clinical and anatomical importance, as it forms a connection between the inferior and superior vena cava (SVC).^{1,2} This pathway provides collateral circulation, acting as a vital shunt in cases of SVC or inferior vena cava obstruction caused by thrombus, infection, malignant or benign masses, or iatrogenic injury.^{3,4}



This work is licensed under
a Creative Commons
Attribution-NonCommercial
4.0 International License.

The azygos vein (AV), when abnormally widened, is often associated with increased venous blood flow through collateral pathways or elevated right atrial pressure.⁵ Therefore, understanding the normal anatomy of the azygos system is essential for recognizing pathological changes in the AV. Additionally, a precise understanding of its anatomy and variations is important because metastatic lymph nodes can be located along the AV in certain cancers,⁶ and surgical or interventional procedures in this area carry a risk of injury. Knowledge of the AV's location, course, and dimensions is a key prerequisite for surgical planning, particularly for procedures that must consider adjacent anatomical structures. Although injuries to the azygos system are reported less frequently than injuries to major thoracic vessels, they can be equally fatal in terms of morbidity and mortality.⁷ Numerous cadaver studies have documented the considerable variation within the azygos system, reflecting its complex embryological development.^{8–10} However, due to the potential for confusion with lymph nodes or small masses, the computed tomography (CT) appearance and dimensions of these vessels must be clearly defined.¹¹ Notably, there is a lack of CT-based studies in the literature that investigate the course of the AV, the level of the AV-SVC junction, and the AV's diameter at that junction, which is a clinically important feature of the azygos system. The aim of this study is to anatomically analyze these features

KEY MESSAGES

- The AV reaches the midline in most cases and, contrary to traditional understanding, does not typically begin and end on the right side.
- The diameter of the SVC is positively correlated with the diameter of the AV.
- The apex of the AV arch can be found between the middle third of the third thoracic vertebra and the middle third of the sixth thoracic vertebra.

in adults and to investigate possible differences by age and sex. A further aim is to determine the anatomical position of the AV relative to the vertebral column along its course, from its origin to its termination in the SVC, and to assess the effects of sex, age, and the presence of osteophytes on this course.

MATERIALS AND METHODS

This study was approved by the local ethics committee of Selçuk University Faculty of Medicine (approval date: 21/04/2021, approval number: 2021/212). CT images obtained at the Department of Radiology of Selçuk University were retrospectively analyzed. Patients with a history of thoracic surgery, pulmonary masses, or acute coronary disease were

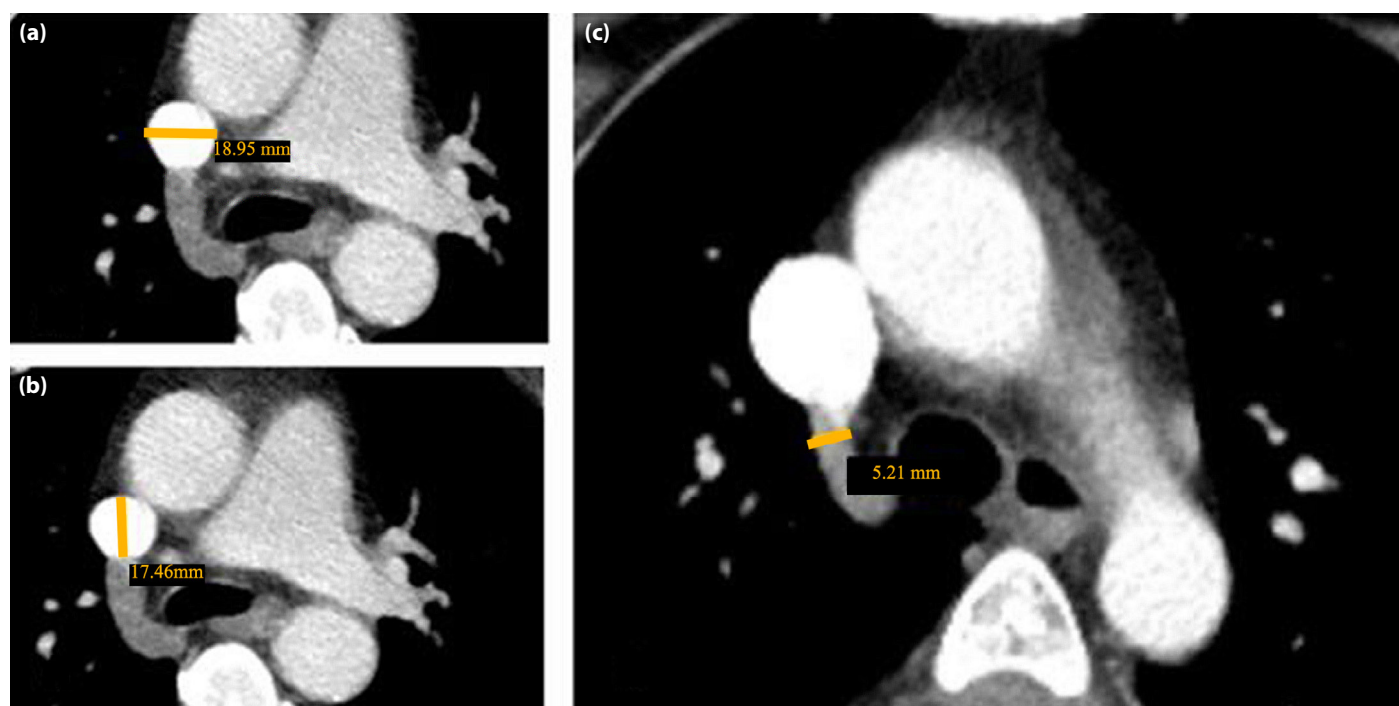

Figure 1. (a–c) Measurement of vein diameters. **(a)** Transverse diameter of the superior vena cava. **(b)** Anteroposterior diameter of the superior vena cava. **(c)** Diameter of the azygos vein.

excluded from the study. A total of 300 patients (150 males and 150 females) aged between 18 and 87 years were randomly selected for inclusion. Examinations were conducted using a 256-slice dual-source CT scanner (Siemens Somatom Definition Flash, Germany) and a 16-slice CT scanner (Siemens Scope, Germany). Thoracic images were acquired with a slice thickness of 3 mm. These images were transferred to the PACS (Picture Archiving and Communication System) and evaluated using the SYNGO-VIA workstation. Multiplanar reconstructions were performed to create axial, coronal, and sagittal images. All procedures performed in this study involving human participants were in accordance with the ethical standards of the institutional and/or national research committee and with the 1964 Helsinki declaration and its later amendments or comparable ethical standards.

The level at which the AV drains into the SVC, as well as the peak of the arch formed by the AV at this junction, were identified. For a more detailed description of these levels, the vertebral bodies were divided into three equal parts: upper, middle, and lower thirds. The diameters of both the AV and the SVC at the drainage point were measured on the obtained images (Fig. 1).

The presence of the hemiazygos vein (HV) and accessory hemiazygos vein (AHV) was recorded, and when present, their diameters and termination levels were measured (Fig. 2). The study also evaluated whether the absence of HV and AHV influenced the diameter of the AV.

To determine the course of the AV, it was traced in transverse sections from the lowest visible point up to its drainage into the SVC. The presence of vertebral osteophytes was assessed, and their potential effect on the course of the AV was analyzed. The collected data were compared by sex and age group. Patients were grouped into two categories: those below and those above the median age of 55 years. Additionally, they were categorized into seven decadal age groups. The aim was to assess the effect of age on the course and diameter of the AV in a comprehensive and multidimensional manner.

Statistical Analysis

Statistical analysis was performed using IBM SPSS Statistics for Windows, Version 23.0 (IBM Corp., Armonk, NY). Continuous data were presented as median (min–max) or mean±standard deviation (SD). Categorical variables were presented as percentages (%) and frequencies (n), and analyzed using Fisher's Exact test, Pearson chi-square test, Fisher-Freeman-Halton test, post hoc Bonferroni test, and Monte Carlo Simulation, as appropriate. The assumption of normality was assessed using the Shapiro-Wilk test. For normally distributed numerical data, independent t-tests were used. Pearson

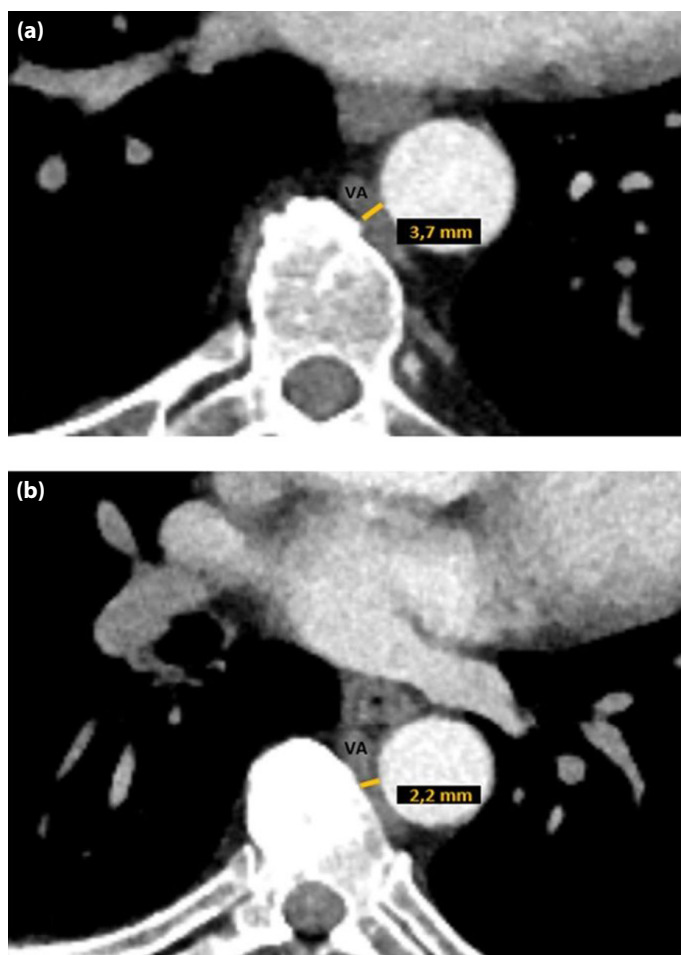


Figure 2. (a, b) Measurement of vein diameters. Diameters of the hemiazygos vein (a) and accessory hemiazygos vein (b), measured at the level where they drain into the azygos vein.

correlation analysis was applied to evaluate relationships between numerical variables. Homogeneity of variances was assessed using Levene's Test. One-way analysis of variance (ANOVA) and post hoc Games-Howell tests were used to analyze differences in AV diameter across seven age groups. Differences in AV diameter between HV and AHV groups were also assessed using one-way ANOVA. A two-sided p-value of less than 0.05 was considered statistically significant.

RESULTS

Data from 300 cases with a mean age of 52 years were analyzed. The AV drained into the SVC at the level of the fifth thoracic vertebra in 59.4% of the cases. The most common location of the AV-SVC junction was the upper third of the fifth thoracic vertebra (26.7%). Patients were divided into two groups based on median age: those younger than 55 years and those ages 55 years or older. No statistically significant difference was

Table 1. Level of AV-SVC junction according to sex and age groups

AV-SVC junction n (%)		Male (n=150)	Female (n=150)	p	Age <55 years (n=148)	Age ≥55 years (n=152)	p
T3	Lower third	0 (0%) ^a	3 (2%) ^a	0.008	2 (1.4%)	1 (0.7%)	0.483
T4	Upper third	7 (4.7%) ^a	7 (4.7%) ^a		8 (5.4%)	6 (3.9%)	
	Middle third	13 (8.7%) ^a	16 (10.7%) ^a		20 (13.5%)	9 (5.9%)	
	Lower third	15 (10%) ^a	33 (22%) ^b		23 (15.5%)	25 (16.4%)	
T4-T5 discus intervertebralis		5 (3.3%) ^a	0 (0%) ^a		4 (2.7%)	1 (0.7%)	
T5	Upper third	39 (26%) ^a	41 (27.3%) ^a		39 (26.4%)	41 (27%)	
	Middle third	28 (18.7%) ^a	26 (17.3%) ^a		25 (16.9%)	29 (19.1%)	
	Lower third	27 (18%) ^a	17 (11.3%) ^a		19 (12.8%)	25 (16.4%)	
T5-T6 discus intervertebralis		3 (2%) ^a	0 (0%) ^a		1 (0.7%)	2 (1.3%)	
T6	Upper third	8 (5.3%) ^a	6 (4%) ^a		6 (4.1 %)	8 (5.3%)	
	Middle third	3 (2%) ^a	0 (0%) ^a		1 (0.7%)	2 (1.3%)	
	Lower third	1 (0.7%) ^a	1 (0.7%) ^a		0 (0%)	2 (1.3%)	
T6-T7 discus intervertebralis		1 (0.7%) ^a	0 (0%) ^a		0 (0%)	1 (0.7)	

AV: Azygos vein; SVC: Superior vena cava; T: Thoracic vertebra; n: Number of cases. Fisher-Freeman-Halton test. Different lowercase letters in the same row indicate a statistically significant difference between groups.

Table 2. Comparison of vein diameters according to sex and age

Diameter	Sex			p	Age		p
	All cases (n=300)	Male (n=150)	Female (n=150)		<55 years (n=148)	≥55 years (n=152)	
	Mean±SD	Mean±SD	Mean±SD		Mean±SD	Mean±SD	
AV	6.37±1.64	6.45±1.66	6.28±1.63	0.363	6.19±1.69	6.54±1.58	0.063
SVC AP	20.74±3.68	20.83±3.89	20.64±3.48	0.666	19.99±3.53	21.46±3.7	0.001
SVC T	15.71±3.71	15.37±3.59	16.05±3.81	0.114	14.93±3.3	16.46±3.93	<0.001
HV	3.95±1.15	4.15±1.14	3.74±1.12	0.003	3.92±1.12	3.97±1.18	0.712
AHV	3.12±1	3.02±0.99	3.21±1	0.422	3.21±1.06	3.02±0.92	0.435

AV: Azygos vein; SVC AP: Superior vena cava anteroposterior diameter; SVC T: Superior vena cava transverse diameter; HV: Hemiazygos vein; AHV: Accessory hemiazygos vein; n: Number of cases; SD: Standard deviation.

found between these two age groups in terms of the AV-SVC junction level. However, the rate of AV termination in the lower third of the fourth thoracic vertebra was significantly higher in females (22%) compared to males (10%) ($p=0.008$) (Table 1).

The highest level at which the apex of the AV arch was identified was the middle third of the third thoracic vertebra, while the lowest was the middle third of the sixth thoracic vertebra. The apex of the AV arch was most commonly located at the lower third of the fourth thoracic vertebra (26%). No significant association was found between the apex level and age ($p=0.408$). The rate of the apex being at the middle third of the fourth thoracic vertebra was higher

in females (23.3% vs. 11.3%), while the apex being at the upper third (23.3% vs. 14.7) and middle third (12.7% vs. 4%) of the fifth thoracic vertebra was more frequent in males ($p=0.006$).

The measured diameters of the vein are presented in Table 2. The anteroposterior and transverse diameters of the SVC were significantly larger in the group aged 55 years and older. No significant differences were found between the two age groups regarding the diameters of the AV, HV, and AHV. However, the HV diameter was significantly larger in males than in females, while no significant sex-based differences were observed for the other vein diameters (Table 2).

Table 3. Evaluation of AV diameter across seven age groups

Age group	n	AV diameter	
		Mean (mm)	SD
Group 2 (18–29 years)	34	6.15	1.79
Group 3 (30–39 years)	32	6.34	2.1
Group 4 (40–49 years)	47	6.15	1.38
Group 5 (50–59 years)	79	6.18	1.63
Group 6 (60–69 years)	75	6.62	1.54
Group 7 (70–79 years)	30	6.74	0.7
Group 8 (80–87 years)	3	7.58	0.74

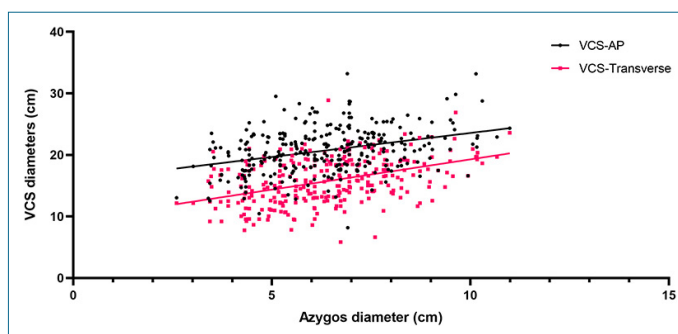
AV: Azygos vein; n: Number of cases; SD: Standard deviation.

The AV diameter, as well as the anteroposterior and transverse diameters of the SVC, tended to increase with age ($p=0.044$, $r=0.116$; $p=0.003$, $r=0.169$; $p<0.001$, $r=0.238$; respectively). HV and AHV diameters showed no significant correlation with age ($p=0.727$ and $p=0.502$, respectively).

The mean AV diameter was further analyzed across seven decadal age groups for more detailed evaluation. Although differences were observed between the means in these groups (Table 3), none of the differences were statistically significant (all p values >0.05). The lowest p value was found in the comparison between the fourth and eighth groups ($p=0.267$), but this result was also not significant.

There was a positive correlation between AV diameter and age ($p=0.044$, $r=0.116$), SVC anteroposterior diameter and age ($p=0.003$, $r=0.169$), and SVC transverse diameter and age ($p<0.001$, $r=0.238$) (Fig. 3). A moderate positive correlation was observed between the transverse and anteroposterior diameters of the SVC ($p<0.001$, $r=0.405$). A weak positive correlation was found between HV diameter and AV diameter ($p<0.001$, $r=0.300$). There were very weak positive correlations between HV diameter and the anteroposterior ($p=0.015$, $r=0.146$) and transverse ($p=0.002$, $r=0.184$) diameters of the SVC. The diameter of the AHV did not correlate with the diameters of the other veins.

The HV was not observed in 21 cases (Table 4). There was no significant relationship between HV prevalence and sex or age. In both sexes and age groups, the HV most commonly drained into the AV at the ninth thoracic vertebral level. The rate of HV termination at the intervertebral disc level between the eighth and ninth thoracic vertebrae was significantly higher in males than in females ($p=0.045$). No statistically significant association was found between age and HV termination level.

**Figure 3.** Scatter plot showing the correlation between the diameter of the azygos vein (AV) and the diameters of the superior vena cava (SVC).

The AHV was observed in 68 cases, with no significant association between its presence and sex or age (Table 4). The AHV most frequently drained into the AV at the eighth thoracic vertebral level in both sexes, and there was no significant relationship between AHV termination level and sex. In the younger group, the AHV most commonly terminated at the ninth (33.3%) and eighth thoracic vertebral levels (33.3%), while in the older group it most frequently terminated at the eighth thoracic vertebral level (59.4%). The rate of termination of the AHV at the eighth thoracic vertebral level in the older group (59.4% vs. 33.3%) and at the ninth thoracic vertebral level in the younger group (33.3% vs. 6.3%) were both found to be statistically significantly higher ($p=0.015$).

In 68 cases, all three veins (AV, HV, and AHV) were present (mean AV diameter: 6.41 ± 1.66). In 211 cases, AV and HV were present but AHV was absent (mean AV diameter: 6.34 ± 1.65). In 21 cases, only the AV was present (mean AV diameter: 6.54 ± 1.51). The presence of HV and AHV did not result in a statistically significant change in AV diameter ($p=0.841$).

The AV was observed to remain on the right side of the midline from its origin to termination in 23 cases (7.7%). In 159 cases (53%), it reached the midline during its course, and in 118 cases (39.3%), it crossed to the left and then turned to the right to drain into the SVC. There was no significant association between AV course and sex ($p=0.130$). However, the rate of reaching the midline was significantly higher in the group younger than 55 years (66.2% vs. 40.1%), while the rate of crossing to the left of the midline was significantly higher in the group older than 55 years (53.3% vs. 25%) ($p<0.001$).

To evaluate the relationship between AV course and age more comprehensively, we categorized the AV course across seven different age groups (Table 5). In the second and third age groups, the AV was most commonly located along the midline

Table 4. Comparison of HV and AHV presence and termination levels by sex and age

Variable n (%)	All cases (n=300)	Sex		p	Age group		p
		Male (n=150)	Female (n=150)		<55 years (n=148)	≥55 years (n=152)	
HV presence				0.497 ¹			0.285 ¹
Present	279 (93%)	141 (94%)	138 (92%)		140 (94.6%)	139 (91.4%)	
Absent	21 (7%)	9 (6%)	12 (8%)		8 (5.4%)	13 (8.6%)	
HV termination level				0.045 ²			0.602 ²
BCV	7 (2.5%)	3 (2.1%) ^a	4 (2.9%) ^a		4 (2.9%)	3 (2.2%)	
T6	1 (0.4%)	0 (0%) ^a	1 (0.7%) ^a		1 (0.7%)	0 (0%)	
T6-T7	1 (0.4%)	1 (0.7%) ^a	0 (0%) ^a		0 (0%)	1 (0.7%)	
T7	10 (3.6%)	4 (2.8%) ^a	6 (4.3%) ^a		4 (2.9%)	6 (4.3%)	
T7-T8	1 (0.4%)	1 (0.7%) ^a	0 (0%) ^a		1 (0.7%)	0 (0%)	
T8	44 (15.8%)	21 (14.9%) ^a	23 (16.7%) ^a		19 (13.6%)	25 (18%)	
T8-T9	13 (4.7%)	12 (8.5%) ^a	1 (0.7%) ^b		9 (6.4%)	4 (2.9%)	
T9	112 (40.1%)	58 (41.1%) ^a	54 (39.1%) ^a		53 (37.9%)	59 (42.4%)	
T9-T10	10 (3.6%)	3 (2.1%) ^a	7 (5.1%) ^a		6 (4.3%)	4 (2.9%)	
T10	61 (21.9%)	32 (22.7%) ^a	29 (21%) ^a		30 (21.4%)	31 (22.3%)	
T10-T11	9 (3.2%)	2 (1.4%) ^a	7 (5.1%) ^a		6 (4.3%)	3 (2.2%)	
T11	10 (3.6%)	4 (2.8%) ^a	6 (4.3%) ^a		7 (5%)	3 (2.2%)	
AHV presence				0.581 ¹			0.499 ¹
Present	68 (22.7%)	32 (21.3%)	36 (24%)		36 (24.3%)	32 (21.1%)	
Absent	232 (77.3%)	118 (78.7%)	114 (76%)		112 (75.7%)	120 (78.9%)	
AHV termination level				0.587 ²			0.015 ²
BCV	1 (1.5%)	1 (3.1%)	0 (0%)		1 (2.8%) ^a	0 (0%) ^a	
T6	1 (1.5%)	1 (3.1%)	0 (0%)		0 (0%) ^a	1 (3.1%) ^a	
T7	15 (22.1%)	9 (28.1%)	6 (16.7%)		7 (19.4%) ^a	8 (25%) ^a	
T7-T8	2 (2.9%)	1 (3.1%)	1 (2.8%)		1 (2.8%) ^a	1 (3.1%) ^a	
T8	31 (45.6%)	13 (40.6%)	18 (50%)		12 (33.3%) ^a	19 (59.4%) ^a	
T8-T9	1 (1.5%)	0 (0%)	1 (2.8%)		1 (2.8%) ^a	0 (0%) ^a	
T9	14 (20.6%)	6 (18.8%)	8 (22.2%)		12 (33.3%) ^a	2 (6.3%) ^b	
T9-T10	2 (2.9%)	0 (0%)	2 (5.6%)		2 (5.6%) ^a	0 (0%) ^a	
T10	1 (1.5%)	1 (3.1%)	0 (0%)		0 (0%) ^a	1 (3.1%) ^a	

HV: Hemiazygos vein; AHV: Accessory hemiazygos vein; BCV: Brachiocephalic vein; T: Thoracic vertebra; n: Number of cases. 1: Pearson chi-square test; 2: Fisher-Freeman-Halton test. Different lowercase letters in a row indicate a statistically significant difference between groups.

(approximately 70%), whereas in older groups (fifth group and above), the incidence of a left-sided course increased significantly. In the seventh and eighth groups, no cases were observed in which the AV remained entirely on the right side (0%). A statistically significant association was found between age group and AV course type (χ^2 (12)=40.423, $p<0.001$), and this was confirmed by a Monte Carlo simulation ($p=0.001$,

99% confidence interval (CI): 0.000-0.001). The strength of this association was moderate, with a Cramér's V value of 0.260.

Osteophytes were present in at least one vertebra in 118 cases (39.3%). The rate of AV crossing to the left of the midline was significantly higher in patients with osteophytes (55.9% vs. 28.6%), while the rate of AV reaching the midline was

Table 5. Course of the azygos vein according to age groups

	Right	Reached the midline	Crossed to the left	Total
Group 2 (18–29 years)				
n	5	25	4	34
%	14.7%	73.5%	11.8%	100%
Group 3 (30–39 years)				
n	3	23	6	32
%	9.4%	71.9%	18.8%	100%
Group 4 (40–49 years)				
n	3	33	11	47
%	6.4%	70.2%	23.4%	100%
Group 5 (50–59 years)				
n	8	35	36	79
%	10.1%	44.3%	45.6%	100%
Group 6 (60–69 years)				
n	4	30	41	75
%	5.3%	40.0%	54.7%	100%
Group 7 (70–79 years)				
n	0	12	18	30
%	0%	40%	60%	100%
Group 8 (80–87 years)				
n	0	1	2	3
%	0%	33.3%	66.7%	100%
Total				
n	23	159	118	300
%	7.7%	53%	39.3%	100%

significantly higher in patients without osteophytes (62.6% vs. 38.1%) ($p < 0.001$).

DISCUSSION

The azygos system, located in the posterior mediastinum, is one of the major venous networks that should be considered during surgical procedures involving the posterior thoracic wall. This system, which forms a collateral network between the SVC and the inferior vena cava, includes the AV, which primarily courses to the right of the midline, and the HV and AHV, which run to the left of the midline.² The AV can drain into the SVC, right atrium, right subclavian vein, intrapericardial part of the SVC, or the right brachiocephalic vein.⁴ In all cases included in our study, the AV was present and terminated by draining

into the SVC. The results of similar studies identifying the level of this junction are presented in Table 6. It is noteworthy that cadaveric studies most frequently report the AV-SVC junction at the third and fourth thoracic vertebral levels, whereas CT and computed tomography angiography (CTA) studies most often identify it at the fifth thoracic vertebral level. This discrepancy may be due to methodological differences or postmortem anatomical changes.

In 75% of chest radiographs, an oval, circular, or teardrop-shaped AV arch can be visualized just above the right main bronchus.¹² However, there is limited data on the course and morphometry of the AV arch, which lies in close proximity to the right lung hilum, phrenic nerve, trachea, and sympathetic trunk.¹³ In our study, the rate of the arch being located at the middle third of the fourth thoracic vertebra was higher in females, while its presence at the upper and middle thirds of the fifth thoracic vertebra was more frequent in males. These findings are valuable in highlighting differences between sexes.

In our study, the mean diameter of the AV was found to be 6.37 mm. This value was reported as 9.6 mm by Koutsouflianiotis et al.¹⁴ and 8.1 mm by Tatar et al.¹⁵ Kutoğlu et al.⁸ found the AV diameter to be 8.56 mm in their study on 48 cadavers; Dahran and Soames¹⁶ reported it as 6.21 mm in a study on 30 cadavers; and Patra et al.¹⁰ reported a diameter of 12.21 mm, also based on 30 cadavers. It is evident that the reported values vary considerably. These discrepancies may be attributed to differences in methodology, materials used, or the lack of accessible medical histories for the patients or cadavers studied. Accurate diagnosis of an enlarged AV is extremely important, as it may indicate the presence of a thrombus in the SVC.¹⁴ Ghuysen et al.¹⁷ suggested that an enlarged AV diameter may increase the risk of death in patients with pulmonary embolism. Therefore, standardized and more comprehensive studies are necessary to better determine normal AV diameter ranges.

Koutsouflianiotis et al.¹⁴ also reported that the SVC diameter was significantly larger in males than in females and showed a slight increase with age. In contrast to their findings,¹⁴ our study found no sex-based differences in SVC diameter. However, both the transverse and anteroposterior diameters of the SVC were significantly larger in the elderly group. This discrepancy between our findings and those of previous studies may be due to variations in the number of individuals included in each age group or differences in the two-dimensional measurement techniques employed. In our study, SVC diameter was positively correlated with AV diameter, which supports the findings of Koutsouflianiotis et al.,¹⁴ who suggested that AV enlargement may serve as a warning sign for SVC enlargement and mediastinal pathologies.

Table 6. Studies determining the AV-SVC junction vertebral level

Study	Year	Method	N	T2	T2-T3	T3	T3-T4	T4	T4-T5	T5	T5-T6	T6
Patra et al. ¹⁰	2019	Cadaver	30	20%	16.7%	53.3%	6.7%	3.3%	–	–	–	–
Raghavendra and Bhosale ¹³	2017	Cadaver	36	–	2.8%	11.1%	13.9%	52.8%	8.3%	11.1%	–	–
Dahran and Soames ¹⁶	2016	Cadaver	30	30%	20%	47%	–	–	–	–	–	–
Krakowiak-Sarnowska et al. ¹⁸	2003	Fetal	32	–	–	12.5%	–	81.3%	–	6.3%	–	–
Tatar et al. ¹⁵	2008	CT	103	–	–	–	–	40%	–	55%	–	5%
Koutsouflianiotis et al. ¹⁴	2020	CTA	51	–	–	2%	–	31.4%	–	56.9%	–	9.8%
This study	2022	CT	300	–	–	1%	–	30.4%	1.7%	59.4%	1%	6.4%

N: Number of cases; T: Thoracic vertebra; AV: Azygos vein; HV: Hemiazygos vein; AHV: Accessory hemiazygos vein; CTA: Computed tomography angiography; CT: Computed tomography.

In our study, the HV was identified in 279 cases (93%) and the AHV in 68 cases (22.7%). This is consistent with Tatar et al.,¹⁵ who reported HV in 87.4% of cases. Krakowiak-Sarnowska et al.¹⁸ found HV in 84.4% and AHV in 80% of cases in a study of 32 human fetuses. The relatively lower detection rate of AHV in our study (22.7%) may be due to the difficulties in visualizing small veins on CT. In cases where the AHV joins the HV after a short course and drains into the AV as a common trunk without a distinct vertical segment on the left side, AHV may be overlooked.

Our study found that the HV most frequently joined the AV at the ninth thoracic vertebral level (40.1%). In contrast, Patra et al.,¹⁰ Kutoğlu et al.,⁸ Dahran and Soames,¹⁶ and Krakowiak-Sarnowska et al.¹⁸ most commonly reported the eighth thoracic vertebral level.

In our study, the AHV most frequently joined the AV at the eighth thoracic vertebral level (45.6%). Patra et al.¹⁰ reported this level as most commonly the sixth thoracic vertebra; Kutoğlu et al.⁸ identified it most frequently at the eighth; Dahran and Soames¹⁶ at the fifth; and Krakowiak-Sarnowska et al.¹⁸ at the seventh thoracic vertebra.

In our study, the HV was the only vein observed on the left side in seven cases where the AHV was absent. In these cases, the HV terminated by draining into the left brachiocephalic vein without establishing a connection with the AV during its course. This variation in the azygos system corresponds to Type 1 in Anson and McVay's classification,¹⁹ with previously reported incidences of 3% by Dahran and Soames,¹⁶ 2.1% by Kutoğlu et al.,⁸ and 3.3% by Patra et al.¹⁰ These are compatible to the 2.3% incidence observed in our study.

In 21 cases in this study, neither the HV nor the AHV was observed. This variation, compatible with Type 3 in the Anson and McVay classification,¹⁹ was reported at rates of 10% by Dahran and Soames,¹⁶ 2.1% by Kutoğlu et al.,⁸ and

6.7% by Patra et al.¹⁰ The 7% rate we found is consistent with those previously reported in the literature.

To evaluate whether the presence of accompanying veins affects AV diameter, we categorized cases into three groups: patients with only the AV; patients with the AV and HV; and patients with the AV, HV, and AHV. Although the mean AV diameter was greater in cases where only the AV was present, the presence of HV and AHV did not lead to a statistically significant difference in AV diameter.

Although the AV is classically described as a vein that passes to the right of the midline, later studies have challenged this traditional understanding.⁹ Tatar et al.¹⁵ reported that the AV was located on the right in 37.9% of cases, along the midline in 39.8%, and on the left in 22.3% of 103 patients with a mean age of 47 years. Koutsouflianiotis et al.¹⁴ found that the AV was located on the right in 5.9% of cases, slightly to the right of the midline in 37.3%, and on the left in 56.9%, based on a CTA study conducted in patients with a mean age of 66 years. In our study, the AV was located solely on the right in 7.7% of cases, reached the midline in 53%, and crossed to the left in 39.3%. When comparing these three CT-based studies evaluating the azygos system, Tatar et al.¹⁵ reported the highest rate of right-sided AV location, observed in the youngest patient population.

We found that the AV reached the midline significantly more often in patients under 55 years of age, while it crossed to the left of the midline significantly more often in patients aged 55 and older. This finding supports the idea that the AV tends to approach the midline and cross to the left with increasing age. Similarly, our analysis by decadal age groups shows a decreasing trend in right-sided localization and an increasing trend in leftward shift with advancing age (Table 5).

Nathan²⁰ reported that osteophytes, which form in the thoracic vertebrae during aging, may contribute to the

leftward shift of the AV. In our study, the rate of AV crossing to the left of the midline was significantly higher in patients with osteophytes (55.9%), while the rate of reaching the midline was significantly higher in patients without osteophytes (62.6%). However, Saito et al.²¹ reported no significant association between AV position and the presence of osteophytes. Kagami and Sakai²² suggested that while the AV can course to the left even in individuals without osteophytes, the position of the AV position is not influenced by osteophytes. Rather, the formation of osteophytes may be affected by the course of vessels such as the AV or the aorta. In our study, the AV passed to the left in 52 cases without the presence of osteophytes. In conclusion, the leftward displacement of the AV appears to be partly a consequence of the aging process,²¹ though multiple factors may contribute to this change, and the exact cause is unclear.

CONCLUSION

Our study is significant in providing a detailed description of the various vertebral levels at which the AV-SVC junction can occur. We demonstrated that the AV reaches the midline in 53% of cases, and contrary to traditional descriptions, it is not a vessel that typically begins and ends on the right side. We believe that determining the mean diameters of the veins forming the azygos system, along with various locations in which they can be found, will help radiologists distinguish between them from lymph nodes or masses, especially on transverse section CT images. We also believe that our findings will aid in preventing iatrogenic injuries and misdiagnoses during interventional procedures and radiologic evaluations involving the thoracic region.

Ethics Committee Approval: The Selçuk University Faculty of Medicine Ethics Committee granted approval for this study (date: 21.04.2021, number: 2021/212).

Author Contributions: Concept – AKK; Design – AKK, MS, GDA; Supervision – MS, AKK, GDA; Resource – MS, MK; Materials – MK; Data Collection and/or Processing – GDA, MK; Analysis and/or Interpretation – GDA, MK; Literature Search – GDA, AKK, MS; Writing – GDA, MS; Critical Reviews – MS.

Conflict of Interest: The authors have no conflict of interest to declare.

Informed Consent: Written informed consent was obtained from patients who participated in this study.

Use of AI for Writing Assistance: Not declared.

Financial Disclosure: The authors declared that this study has received no financial support.

Peer-review: Externally peer-reviewed.

REFERENCES

1. Piciocchi S, Barone D, Sanna S, Dubini A, Goodman LR, Oboldi D, et al. The azygos vein pathway: An overview from anatomical variations to pathological changes. *Insights Imaging* 2014;5(5):619-28. [\[CrossRef\]](#)
2. Moore KL, Dalley AF, Agur AMR. Clinically oriented anatomy. Philadelphia: Lippincott Williams & Wilkins; 2010.
3. Lacout A, Marcy PY, Thariat J, Lacombe P, El Hajjam M. Radio-anatomy of the superior vena cava syndrome and therapeutic orientations. *Diagn Inter v Imaging* 2012;93(7-8):569-77. [\[CrossRef\]](#)
4. Dudiak CM, Olson MC, Posniak HV. CT evaluation of congenital and acquired abnormalities of the azygos system. *Radiographics* 1991;11(2):233-46. [\[CrossRef\]](#)
5. Shin MS, Ho KJ. Clinical significance of azygos vein enlargement: Radiographic recognition and etiologic analysis. *Clin Imaging* 1999;23(4):236-40. [\[CrossRef\]](#)
6. Schröder W, Vallböhmer D, Bludau M, Banczyk A, Gutschow C, Hölscher AH. The resection of the azygos vein--Necessary or redundant extension of transthoracic esophagectomy? *J Gastrointest Surg* 2008;12(7):1163-7. [\[CrossRef\]](#)
7. Wall MJ Jr, Mattox KL, Debaek ME. Injuries to the azygos venous system. *J Trauma* 2006;60(2):357-62. [\[CrossRef\]](#)
8. Kutoglu T, Turut M, Kocabiyik N, Ozan H, Yildirim M. Anatomical analysis of azygos vein system in human cadavers. *Rom J Morphol Embryol* 2012;53(4):1051-6.
9. Bales G. A semi-quantitative approach to variation of the azygos vein course. *Clin Anat* 2014;27(7):1030-7. [\[CrossRef\]](#)
10. Patra A, Singla RK, Kaur H, Malhotra V. Analysis of multiple variations in azygos venous system anatomy with its classification: A cadaveric study. *Eur J Anat* 2019;23(1):9-15.
11. Takasugi JE, Godwin JD. CT appearance of the retroaortic anastomoses of the azygos system. *AJR Am J Roentgenol* 1990;154(1):41-4. [\[CrossRef\]](#)
12. Rivaud Y, Maldjian PD. The azygos vein from a to z. *J Thorac Imaging* 2019;34(5):W100-8. [\[CrossRef\]](#)
13. Raghavendra AY, Bhosale SM. Variations of arch of azygos vein: An anatomical overview with clinical importance. *Int J Anat Res* 2017;5:4251-6. [\[CrossRef\]](#)
14. Koutsouflianiotis K, Daniil G, Paraskevas G, Piagkou M, Chrysanthou C, Natsis K. Computed tomography angiography study of the azygos vein course and termination into superior vena cava: Gender and age impact. *Surg Radiol Anat* 2021;43(3):353-61. [\[CrossRef\]](#)

15. Tatar I, Denk CC, Celik HH, Oto A, Karaosmanoglu DA, Ozdemir BM, et al. Anatomy of the azygos vein examined by computerized tomography imaging. *Saudi Med J* 2008;29(11):1585-8.
16. Dahrán N, Soames R. Anatomical variations of the azygos venous system: Classification and clinical relevance. *Int J Morphol* 2016;34:1128-36. [\[CrossRef\]](#)
17. Ghuysen A, Ghaye B, Willems V, Lambermont B, Gerard P, Dondelinger RF, et al. Computed tomographic pulmonary angiography and prognostic significance in patients with acute pulmonary embolism. *Thorax* 2005;60(11):956-61. [\[CrossRef\]](#)
18. Krakowiak-Sarnowska E, Wiśniewski M, Szpinda M, Krakowiak H. Variability of the azygos vein system in human foetuses. *Folia Morphol (Warsz)* 2003;62(4):427-30.
19. Anson BJ, McVay CB. *Surgical anatomy*. 6th ed. Philadelphia: W.B. Saunders; 1984.
20. Nathan H. Anatomical observations on the course of the azygos vein (vena azygos major). *Thorax* 1960;15:229. [\[CrossRef\]](#)
21. Saito A, Murakami M, Tomioka K, Ezure H, Moriyama H, Mori R, et al. The impact of aging on the course of the azygos vein. *Okajimas Folia Anat Jpn* 2015;92(1):7-10. [\[CrossRef\]](#)
22. Kagami H, Sakai H. The problems in the arrangement of the azygos vein. *Okajimas Folia Anat Jpn* 1990;67(2-3):111-4. [\[CrossRef\]](#)