

## High-Resolution Anterior Segment Optical Coherence Tomography Characteristics of Conjunctival Tumors

Onur Ocaktan,<sup>1</sup> Fatih Horozoglu,<sup>1</sup> Hidayet Sener,<sup>1</sup> Furkan Özer<sup>2</sup>

<sup>1</sup>Department of Ophthalmology, Erciyes University Faculty of Medicine, Kayseri, Türkiye

<sup>2</sup>Department of Ophthalmology, Nevşehir State Hospital, Nevşehir, Türkiye

### ABSTRACT

**Objective:** This study aimed to assess the demographic, clinical, histological classifications, and anterior segment optical coherence tomography (AS-OCT) features of conjunctival malignancies. The goal was to identify factors associated with tumor malignancy.

**Materials and Methods:** This retrospective analysis included 37 patients with conjunctival tumors. Data collected comprised age, gender, tumor coloration, histological type, location, corneal involvement, subepithelial reflectivity of the lesion on AS-OCT, lesion homogeneity on AS-OCT, and the presence of intralesional cysts on AS-OCT. Statistical analysis was performed using chi-square and t-tests, with a significance level of  $\alpha < 0.05$ . The study protocol was approved by the Erciyes University Health Sciences Research Ethics Committee (Approval Number: 2025/365, Date: 09.07.2025).

**Results:** Malignant tumors were identified in significantly older patients. No significant gender differences were found regarding malignancy. Amelanotic appearance was significantly more common in malignant tumors. The types of tumors identified included conjunctival nevus, conjunctival ocular surface squamous neoplasia (OSSN), conjunctival lymphoma, conjunctival melanoma, and conjunctival cyst. No significant relationship was found between tumor location and malignancy. Corneal involvement was significantly associated with malignancy. On AS-OCT, malignant tumors exhibited a hyporeflective subepithelial lesion with homogeneous internal reflectivity. Although benign tumors contained more intralesional cysts on AS-OCT, this finding was not statistically significant.

**Conclusion:** Conjunctival tumors exhibit various characteristics. Advanced age, amelanotic pigmentation, corneal involvement, and a hyporeflective homogeneous lesion on AS-OCT are significant indicators of malignancy, highlighting the importance of detailed examination and increased vigilance.

**Keywords:** Anterior segment optical coherence tomography, conjunctival melanoma, conjunctival neoplasms, optical coherence tomography imaging, ocular oncology, predictors of tumor malignancy



This study was presented at the 59<sup>th</sup> National Congress of the Turkish Ophthalmology Association, held on November 19–23, 2025.

#### Cite this article as:

Ocaktan O, Horozoglu F, Sener H, Özer F. High-Resolution Anterior Segment Optical Coherence Tomography Characteristics of Conjunctival Tumors. J Clin Pract Res 2026;48(0):0-0.

#### Address for correspondence:

Hidayet Sener.  
Department of Ophthalmology,  
Erciyes University Faculty of  
Medicine, Kayseri, Türkiye  
**Phone:** +90 555 719 64 03  
**E-mail:**  
hidayetsener00@gmail.com

**Submitted:** 17.10.2025

**Revised:** 13.03.2026

**Accepted:** 30.03.2026

**Available Online:** 22.04.2026

Erciyes University Faculty of  
Medicine Publications -  
Available online at [www.jcprres.com](http://www.jcprres.com)

Copyright © Author(s)  
This work is licensed under  
a Creative Commons  
Attribution-NonCommercial  
4.0 International License.



## INTRODUCTION

Conjunctival tumors span a wide spectrum, ranging from benign lesions that require follow-up to highly malignant invasive neoplasms. If left untreated, these tumors can lead to vision loss, aesthetic concerns, and, in cases of malignancy, potentially fatal complications.<sup>1</sup> Despite the availability of advanced diagnostic and therapeutic methods in tertiary hospitals, early detection and treatment of malignant conjunctival tumors remain challenging.

Malignant conjunctival tumors are predominantly found in older populations and exhibit distinct clinical characteristics, including amelanotic lesions and corneal involvement. Research indicates that the prevalence and severity of these lesions vary across different communities, emphasizing the need for localized investigations to tailor diagnostic and therapeutic strategies.<sup>1,2</sup> Recent studies suggest that 61.2% of conjunctival tumors are premalignant or malignant, with squamous cell carcinoma (SCC) and conjunctival intraepithelial neoplasia (CIN) being the most common types.<sup>3</sup>

Histopathological and anatomical analysis of these tumors offers valuable insights for clinical management and prognostic assessments. For instance, although conjunctival melanomas are rare, they exhibit aggressive behavior with a high recurrence rate and potential for metastasis.<sup>4</sup> Additionally, genetic and immunohistochemical investigations are increasingly recognized as essential tools for the accurate diagnosis and classification of malignant tumors. Recent research has underscored the importance of genetic alterations, immunological checkpoint markers, and ultraviolet light signatures in the etiology of conjunctival cancers.<sup>5</sup>

High-resolution anterior segment optical coherence tomography (AS-OCT) has become an increasingly important adjunct to slit-lamp examination, enabling better characterization of conjunctival lesions and more precise delineation of their extent. Previous reports have described specific imaging patterns that can support clinical impressions in certain entities—such as epithelial thickening with increased epithelial reflectivity and an abrupt transition zone in ocular surface squamous neoplasia, a smooth, homogeneous subepithelial hyporeflective lesion with internal “dot-like” infiltrates in lymphoproliferative disease, and variable posterior shadowing that can limit the assessment of heavily pigmented lesions.<sup>6</sup>

However, clinicians often encounter a broad spectrum of conjunctival lesions in daily practice, and the literature provides relatively limited guidance on applying a

## KEY MESSAGES

- Advanced age and amelanotic appearance are strong predictors of malignancy in conjunctival tumors (mean age 64.1 years; 93.75% amelanotic).
- Tumor invasion into the cornea is significantly associated with malignant behavior and should raise clinical suspicion.
- On AS-OCT, a hyporeflective, homogeneous subepithelial lesion supports malignancy, while intralesional cysts suggest benign lesions.

standardized set of AS-OCT descriptors across various diagnoses within a single cohort, especially when interpreted alongside routine clinical variables.<sup>7</sup> A pragmatic analysis of these features in a tertiary-care series may help clarify which descriptors are most consistently observed and how they correlate with histopathologic diagnosis and malignancy risk in real-world settings.<sup>6-8</sup>

This study aims to analyze the demographic, clinical, and histological parameters of conjunctival cancers diagnosed at Erciyes University Ophthalmology Clinic, alongside lesion characteristics observed through high-resolution anterior segment OCT imaging. By examining patient age, gender, tumor coloration, location, size, and anterior segment OCT lesion images, the study seeks to identify predictive markers for malignancy and contribute to the existing body of knowledge in ocular oncology. The goal is to improve early detection and management strategies for conjunctival cancers, ultimately enhancing patient outcomes. A pragmatic analysis of these features within a tertiary care setting may help clarify which descriptors are most consistently observed and how they correlate with histopathological diagnosis and malignancy risk in real-world conditions.

## MATERIALS AND METHODS

### Study Design and Setting

This retrospective cohort study examined the demographics, clinical features, histological classifications, and anterior segment optical coherence tomography (AS-OCT) characteristics of conjunctival malignancies in the Ocular Oncology Division of Erciyes University Ophthalmology Clinic. The study included patients who visited the clinic during a 6-month period from August 2024 – June 2025. Anterior segment OCT imaging was performed using the ANTERION system (Heidelberg Engineering, Heidelberg, Germany), operated on the HEYEX platform. Since the lesions were confined to the conjunctival surface, internal fixation was not used. The imaging area, scan length, and

the number of cross-sectional B-scans were selected based on lesion size to ensure complete coverage of the lesion and its clinically relevant margins. To optimize image clarity while balancing rapid acquisition and minimizing motion-related degradation, B-scan averaging was set to ART=2. Images with inadequate quality due to motion or poor alignment were excluded from the analysis.

On AS-OCT, conjunctival lesions were systematically assessed for epithelial and subepithelial “signature” features to assist with the differential diagnosis of various ocular surface entities, including ocular surface squamous neoplasia (OSSN), conjunctival melanoma, conjunctival lymphoma/benign reactive lymphoid hyperplasia, primary acquired melanosis (PAM), conjunctival nevus, conjunctival papilloma, and other simulating lesions. Specifically, we documented: (i) epithelial thickness and epithelial reflectivity (e.g., thickened hyperreflective epithelium), (ii) the transition pattern between adjacent normal and abnormal epithelium (abrupt vs. gradual), and (iii) the presence of a distinct tissue plane/cleavage plane between the lesion and underlying tissue. Additional descriptors included internal reflectivity and homogeneity, intralesional cystic or hyporeflective spaces (indicative of benign melanocytic or papillomatous lesions), posterior optical shadowing (more prominent in heavily pigmented lesions), and subepithelial patterns such as a smooth, homogeneous hyporeflective mass with “dot-like” infiltrates (suggestive of lymphoproliferative lesions). These parameters were interpreted in conjunction with the slit-lamp examination and clinical context.<sup>6-8</sup>

The study adhered to the STROBE (Strengthening the Reporting of Observational Studies in Epidemiology) guidelines to ensure transparency and scientific rigor in observational research.<sup>9</sup> The study protocol was reviewed and approved by the Erciyes University Health Sciences Research Ethics Committee (Approval Number: 2025/365, Date: 09.07.2025).

### Study Population

A retrospective review was conducted on 102 patients diagnosed with ocular oncology-related conditions, including orbital, intraocular, eyelid, and conjunctival cancers. From this group, 37 conjunctival malignancies were selected for examination.

### Inclusion Criteria

- Patients diagnosed with conjunctival tumors during the study period.
- Histopathological confirmation of the conjunctival tumor diagnosis.
- Availability of comprehensive medical records.

### Exclusion Criteria

- Patients diagnosed with other ocular oncology cancers, such as orbital, intraocular, or eyelid malignancies.
- Individuals with insufficient medical documentation.
- Patients with previously managed recurrent conjunctival neoplasms.
- Patients lost to follow-up before biopsy confirmation.

### Data Collection Methods and Sources

Patient data were collected retrospectively from the following sources:

- Medical documentation: including clinical history and examination results.
- Pathology reports: for histopathological confirmation of tumor diagnosis.
- Anterior segment photos: used to characterize tumor attributes, including dimensions, color, and corneal involvement.
- Anterior segment optical coherence tomography (AS-OCT) images: to assess lesion reflectivity, homogeneity, the presence of intralesional cysts, and the abrupt transition zone in the lesion epithelium.

The data covered the period from August 2024, to June 2025. The following variables were documented:

- Demographics: Age, sex.
- Clinical Features:
  - Tumor pigmentation (classified as amelanotic or pigmented).
  - Tumor localization (bulbar, forniceal, palpebral, caruncle).
  - Corneal involvement (present or absent).
- Tumor Size: Measured in millimeters (mm) using slit-lamp biomicroscopy.
- Histopathological Diagnosis: Tumor categorization based on biopsy results.
- AS-OCT Characteristics:
  - Reflectivity of the lesion (hyporeflective or hyperreflective).
  - Homogeneity of the lesion (homogeneous/heterogeneous).
  - Presence of intralesional cysts (present or absent).
  - Abrupt transition zone in the lesion epithelium.

### Statistical Analysis

Statistical analysis was performed using NCSS version 21. Descriptive statistics, including mean, standard deviation, frequency, and percentage distributions, were calculated for clinical and demographic data. The Shapiro–Wilk test was used to assess the normal distribution of continuous variables. Variables that exhibited a normal distribution were analyzed using parametric tests (independent t-test), while categorical variables were compared using the chi-square test. Statistical significance was defined as a p-value of less than 0.05.

### RESULTS

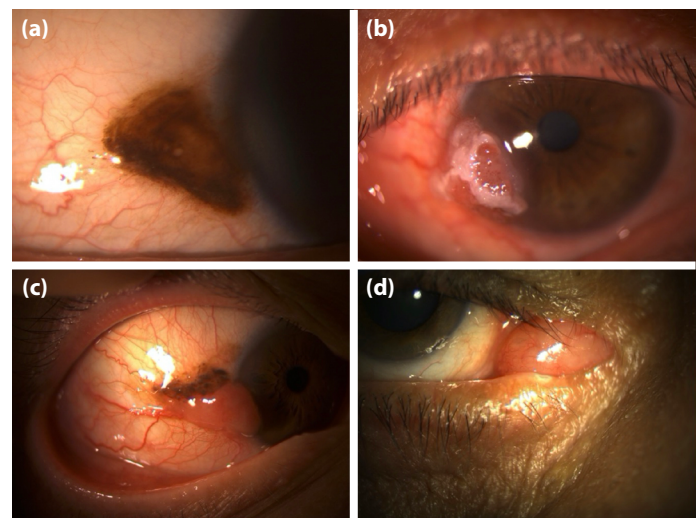
Of the 37 conjunctival tumors examined in this study, 16 were malignant, and 21 were benign. Patients with malignant tumors were significantly older, with a mean age of  $64.1 \pm 16.6$  years ( $p < 0.01$ ), compared to  $26.6 \pm 16.4$  years for patients with benign tumors. The tumor types identified were conjunctival nevus (48.64%,  $n=18$ ), ocular surface squamous neoplasia (27.02%,  $n=10$ ), conjunctival lymphoma (10.81%,  $n=4$ ), conjunctival melanoma (8.10%,  $n=3$ ), and conjunctival cyst (5.40%,  $n=2$ ) (Fig. 1).

#### Analysis of Tumor Size


Benign tumors had an average diameter of  $6.4 \pm 5.4$  mm, while malignant tumors had an average diameter of  $12.7 \pm 8.4$  mm. However, this difference was not statistically significant ( $p=0.09$ ).

#### Tumor Characteristics

- **Pigmentation:** A statistically significant difference ( $p < 0.01$ ) was observed in the likelihood of malignancy between amelanotic tumors (93.75%,  $n=15$ ) and pigmented tumors (6.25%,  $n=1$ ) (Table 1).
- **Location:** Most tumors were located on the bulbar conjunctiva (78.37%,  $n=29$ ), but no significant association between tumor location and malignancy was found ( $p=0.27$ ) (Table 1).
- **Corneal Involvement:** Malignant tumors showed considerably higher rates of corneal involvement (56.25%,  $n=9$ ) compared to benign tumors (4.76%,  $n=1$ ) ( $p < 0.01$ ) (Table 1).
- **AS-OCT Subepithelial Lesion Reflectivity:** In malignant tumors, the lesion was significantly more hyporeflective (72.73%,  $n=8$ ) ( $p=0.01$ ) (Table 1, Fig. 2).
- **AS-OCT Lesion Homogeneity:** The lesion was significantly more homogeneous in malignant tumors (54.5%,  $n=6$ ) compared to benign tumors (15.79%,  $n=3$ ) ( $p=0.02$ ) (Table 1, Fig. 2).



**Figure 1.** (a) Conjunctival nevus, (b) Conjunctival OSSN (c) Conjunctival melanoma, (d) Conjunctival lymphoma.



**Figure 2.** (a) Anterior segment OCT image of a hyperreflective, homogeneous lesion in a case of conjunctival melanoma (arrow), (b) Anterior segment OCT image of a hyporeflective, homogeneous lesion seen in conjunctival lymphoma (arrow) (note that the epithelium over the lesion is hyporeflective in both images).

- **AS-OCT Intralésional Cyst:** Although benign tumors (63.16%,  $n=12$ ) contained more cysts than malignant tumors (27.27%,  $n=3$ ), the difference was not statistically significant ( $p=0.05$ ) (Table 1, Fig. 3, 4).
- **AS-OCT Abrupt Transition Zone in the Lesion Epithelium:** An abrupt transition from normal epithelium to hyperreflective, thickened epithelium was observed in 37.50% ( $n=3$ ) of patients with ocular surface squamous neoplasia. However, since this finding was absent in other conjunctival tumor patients, statistical evaluation could not be performed ( $p=n/a$ ) (Table 1).

In the anterior segment OCT examination, the distribution of subepithelial lesion reflectivity, lesion homogeneity, and the presence of intralésional cysts varied according to tumor types (Table 2).

**Table 1.** Distribution of benign vs. malignant lesion characteristics

Variables	Benign (n=21, 56.75%)	Malignant (n=16, 43.24%)	P
Age (years)	26.6 ± 16.4 (95% CI: 19.4-35.0)	64.1 ± 16.6 (95% CI: 50.9-71.5)	<0.01
Size (mm)	6.4 ± 5.4 (95% CI: 4.0-9.1)	12.7 ± 8.4 (95% CI: 7.7-16.5)	0.09
Gender (male/female)	11 (52.38%) / 10 (47.62%)	10 (62.50%) / 6 (37.50%)	0.53
Pigmentation (amelanotic/pigmented)	8 (38.10%) / 13 (61.90%)	15 (93.75%) / 1 (6.25%)	<0.01
Location			
Exclusively bulbar conj.	17 (80.95%)	12 (75.0%)	0.27
Bulbar conj. and caruncle	2 (9.52%)	1 (6.25%)	
Fornix and tarsus	1 (4.76%)	2 (12.50%)	
Fornix and caruncle	0	1 (6.25%)	
Plica	1 (4.76%)	0	
Corneal involvement (present/absent)	1 (4.76%) / 20 (95.24%)	9 (56.25%) / 7 (43.75%)	<0.01
AS-OCT subepithelial lesion reflectivity	5 (26.32%) / 14 (73.68%)	8 (72.73%) / 3 (27.27%)	0.01
AS-OCT lesion homogeneity (homogeneous/heterogeneous)	3 (15.79%) / 16 (84.2%)	6 (54.5%) / 5 (45.45%)	0.02
AS-OCT intralesional cyst (present / absent)	12 (63.16%) / 7 (36.84%)	3 (27.27%) / 8 (72.73%)	0.05
AS-OCT abrupt transition zone in the lesion epithelium	0 (0%) / 19 (100%)	3 (37.50%) / 8 (62.50%)	n/a

AS-OCT: Anterior segment optical coherence tomography. The first number in each cell indicates the number of patients, while the percentage indicates the proportion of patients.

**Table 2.** AS-OCT characteristics of conjunctival tumors

Variables	Conj. lymphoma	Conj. MM	Conj. nevus	Conj. OSSN	Conj. Cyst
AS-OCT subepithelial lesion reflectivity (hyporeflexive/hyperreflexive)	3 (100%) / 0	0 / 1 (100%)	2 (12.5%) / 14 (87.5%)	5 (62.5%) / 3 (37.5%)	2 (100%) / 0
AS-OCT lesion homogeneity (homogeneous/heterogeneous)	3 (100%) / 0	1 (100%) / 0	1 (6.25%) / 15 (93.75%)	3 (37.5%) / 5 (62.5%)	1 (50%) / 1 (50%)
AS-OCT intralesional cyst (present/absent)	0 / 3 (100%)	0 / 1 (100%)	10 (62.5%) / 6 (37.5%)	3 (37.5%) / 5 (62.5%)	2 (100%) / 0
AS-OCT abrupt transition zone in the lesion epithelium (present/absent)	0 / 3 (100%)	0 / 1 (100%)	0 / 16 (100%)	3 (37.5%) / 5 (62.5%)	0 / 2 (100%)

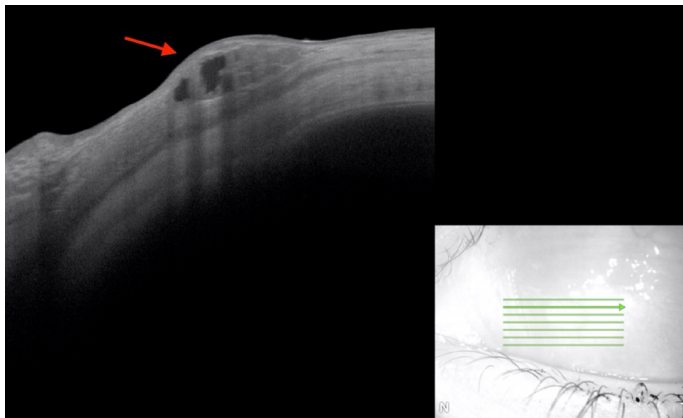
AS-OCT: Anterior segment optical coherence tomography; Conj. lymphoma: Conjunctival lymphoma; Conj. MM: Conjunctival malignant melanoma; Conj. OSSN: Conjunctival ocular surface squamous neoplasia; Conj. Cyst: Conjunctival cyst.

## DISCUSSION

A precise clinical and histological assessment is essential for the diagnosis and treatment of conjunctival tumors, which encompass a diverse range of lesions. Malignant conjunctival tumors were significantly associated with corneal involvement, amelanotic pigmentation, and advanced age. In the anterior segment OCT examination, malignant tumors showed a notable association with a hyporeflexive, homogeneous lesion appearance and were absent of cysts. Although larger

lesion diameters were not statistically significant, they tended to be more common in malignant tumors.

As individuals age, their risk of developing a malignant conjunctival tumor increases. Conjunctival tumors in adolescents and young adults are almost always benign, with malignancies being rare. The average age at which benign tumors are discovered is approximately 11 years, while malignant tumors are typically identified at an average age of 14 years. This suggests that the likelihood of malignancy



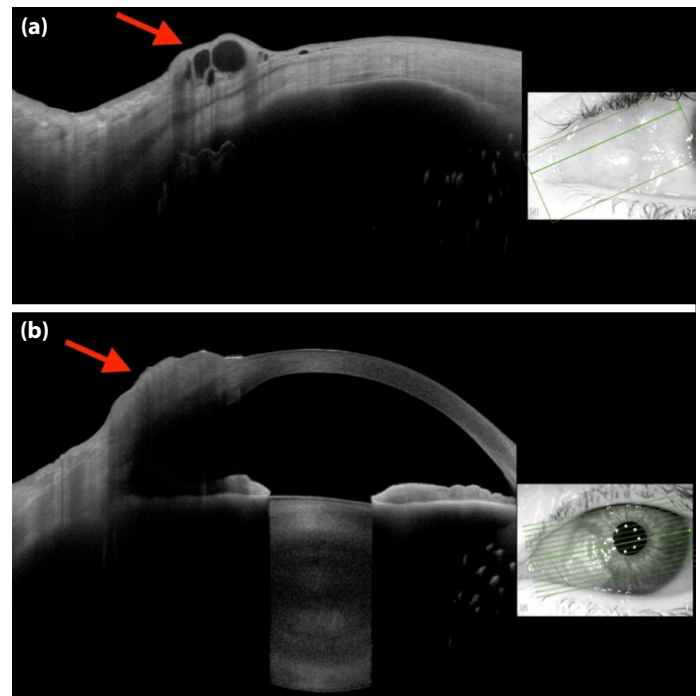
**Figure 3.** Anterior segment OCT image of a case of conjunctival nevus showing lesion heterogeneity, including cyst formations within the lesion.

increases slightly with age.<sup>10</sup> Although malignant tumors remain uncommon in young adults, benign tumors such as nevi are more frequent.<sup>11</sup>

Malignant conjunctival tumors are far more prevalent in middle-aged and older individuals, with the risk of developing cancer increasing substantially after the age of 40.<sup>10-12</sup> Ocular surface squamous neoplasia, in particular, is common in individuals over 60 years, often presenting with larger and more aggressive lesions compared to benign tumors.<sup>10,13</sup> Conjunctival melanoma is also more frequently diagnosed in older patients,<sup>12,14,15</sup> with a higher risk of recurrence and visual acuity loss.<sup>14,16</sup> Lymphoid lesions, including lymphoma, are more common in older adults and tend to present with larger tumor sizes and diffuse involvement.<sup>11,17</sup> Additionally, malignant conjunctival tumors, particularly ocular surface squamous neoplasia and melanoma, are more frequently observed in males than females.<sup>10,13,18</sup>

Studies have shown that conjunctival melanomas with low pigmentation are associated with a worse prognosis. Specifically, low tumor pigmentation is linked to higher risks of metastasis and death. This association is particularly significant in primary conjunctival melanomas, where low pigmentation correlates with increased metastasis and mortality rates.<sup>19</sup>

Malignant conjunctival tumors, such as melanoma and ocular surface squamous neoplasia, typically exhibit larger basal diameters and thicknesses compared to benign lesions, with a median basal diameter of 8 mm.<sup>1</sup> In conjunctival nevi, a larger basal tumor diameter has been statistically associated with an increased likelihood of surgical excision due to concerns about malignant transformation, although histopathological malignancy was not observed in excised cases.<sup>17</sup>



**Figure 4.** (a) Anterior segment OCT image showing intralesional cysts in a case of conjunctival nevus (arrow), (b) Anterior segment OCT image of a case of conjunctival SCC with corneal involvement and hyperreflective epithelium (arrow).

Corneal involvement plays a crucial role in the management of conjunctival tumors. Malignant lesions, including conjunctival squamous intraepithelial neoplasia (CSIN), can exhibit corneal growth, complicating their clinical presentation and necessitating thorough diagnostic evaluation.<sup>1</sup> Similarly, conjunctival melanomas can invade the cornea, sometimes without other conjunctival involvement, emphasizing the need for precise surgical intervention to minimize the risk of recurrence.<sup>20</sup>

Anterior segment optical coherence tomography (AS-OCT) is useful for clearly imaging conjunctival nevi, delineating the lesion's boundaries, and identifying cysts within the lesion. However, a challenge with AS-OCT is the potential for visual ghosting in colored nevi.<sup>22</sup> Shousha et al.<sup>21</sup> demonstrated thicker hyperreflective epithelium and a sudden transition from normal to hyperreflective epithelium in AS-OCT assessments of conjunctival and corneal intraepithelial neoplasia (CCIN) cases. Kieval et al.<sup>22</sup> observed significantly thicker epithelium in cases of epithelial ocular surface squamous neoplasia compared to pterygium when epithelial thickness measured using AS-OCT was compared. Shousha et al.<sup>23</sup> also showed that AS-OCT images offer valuable diagnostic insights when the clinical diagnosis of ocular surface lesions is unclear.

To diagnose corneal and conjunctival disorders, particularly malignant lesions, Nanji et al.<sup>7</sup> investigated the use of high-resolution, spectral-domain optical coherence tomography (HR-OCT). Their study of 82 lesions indicated that HR-OCT can be used to evaluate treatment efficacy, determine the cause of certain ocular surface lesions (such as melanoma, pterygium, nevus, and ocular surface squamous neoplasia), and more. However, pigmented lesions were not as well assessed using this imaging technique. Ocular surface pathology can be identified, and disease resolution can be evaluated with this technology, making it a valuable adjunct to clinical examination and histological diagnosis. A literature review by Janssens et al.<sup>24</sup> demonstrated that AS-OCT and ultrasound biomicroscopy (UBM) are highly effective and complementary modalities for assessing and monitoring corneal and conjunctival tumors, though they cannot replace histological investigation for diagnostic purposes. One drawback of AS-OCT is its limited ability to penetrate pigmented lesions or reach deeper than 1–3 mm. However, AS-OCT offers a more precise technique for small lesions by providing detailed images of the intact cornea, identifying cysts, and aiding in the detection of tumor recurrence. For larger or pigmented lesions, ultrasound biomicroscopy (UBM) provides a more accurate way to assess tumor thickness and define tumor borders.

Venkateswaran et al.<sup>25</sup> demonstrated that high-resolution optical coherence tomography (HR-OCT) can reliably differentiate between epithelial ocular surface tumors, such as ocular surface squamous neoplasia (OSSN), and subepithelial tumors, including conjunctival lymphoma and conjunctival melanoma, in a clinical context. Karp et al.<sup>26</sup> utilized AS-OCT in the surgical treatment of OSSN and showed that the conjunctival tumor margin identified by HR-OCT matched the pathologically confirmed margin in all cases. The high-resolution OCT images of conjunctival lymphoma in Venkateswaran et al.'s<sup>27</sup> research revealed homogeneous, black subepithelial lesions with smooth edges, typically exhibiting monomorphic dot-like infiltrates. These findings provide a foundation for promising areas of future research and potential updates to clinical guidelines.

One of the main barriers to the clinical adoption of AS-OCT as a definitive diagnostic tool is the lack of standardized terminology and reporting protocols.<sup>28</sup> The ongoing development of the Advised Protocol for OCT Study Terminology and Elements for the Anterior Segment (APOSTEL-AS) aims to create a consensus nomenclature. Future studies should use this standardized framework to ensure that findings across different institutions and imaging platforms are comparable. This would facilitate the creation of large, multicenter registries to overcome the sample size limitations of current single-center research.<sup>28</sup>

The application of artificial intelligence (AI) and machine learning (ML) to AS-OCT image analysis represents a frontier with immense potential. Future diagnostic protocols could incorporate AI models trained to automatically segment lesions, measure epithelial thickness with micron-scale precision, and classify internal reflectivity patterns.<sup>29</sup> AS-OCT is increasingly being used intraoperatively to ensure that surgical margins are free of sub-clinical disease. Research has shown that margins identified by high-resolution OCT often coincide with pathologically verified margins, which can reduce the need for repeat surgeries and lower the rate of local recurrence in aggressive malignancies like melanoma and invasive squamous cell carcinoma (SCC). Integrating intraoperative OCT into standardized surgical protocols for ocular surface tumors would represent a significant step toward improving patient outcomes and preserving healthy ocular tissue.<sup>30</sup>

Future protocols may involve a dual-modality approach, using structural AS-OCT to evaluate lesion depth and internal homogeneity, while OCT Angiography (OCTA) assesses metabolic activity and aggressive potential based on vessel density. The transition from a “biopsy-centric” to an “imaging-centric” management model is a key area for development. Future clinical guidelines could leverage AS-OCT for the objective monitoring of treatment response in medically managed OSSN.

This research has several limitations. The retrospective design introduces potential biases associated with incomplete or absent data. The small sample size (37 cases) limits statistical power and generalizability. Additionally, as a single-center study, the findings may not be applicable to broader populations. Another limitation is the absence of conjunctival intraepithelial neoplasia (CIN) cases in our cohort. This likely reflects institutional treatment practices and selection bias rather than a true absence of CIN in the population. At our center, clinically suspected CIN or early ocular surface squamous neoplasia cases are often managed with topical chemotherapeutic agents rather than primary excisional biopsy and histopathological confirmation. As a result, our study population is skewed toward more advanced, invasive, or clinically ambiguous lesions that required surgical intervention, potentially overestimating the prevalence of invasive squamous cell carcinoma (SCC) within the ocular surface squamous neoplasia (OSSN) spectrum. Consequently, such cases may be underrepresented in pathology-based retrospective surgical series. Furthermore, by including only histopathologically confirmed surgical cases, our study does not fully represent the entire spectrum of ocular surface tumors, limiting the generalizability of the results. The single-center design and relatively small sample size also restrict the applicability of our findings regarding tumor distribution

patterns. Only histopathologically confirmed tumors were included, potentially excluding clinically diagnosed cases. The study also lacks long-term follow-up, preventing an assessment of recurrence and metastasis rates. More comprehensive and multicenter studies are needed to establish a consensus on the use of next-generation diagnostic tools in managing conjunctival tumors.

## CONCLUSION

This study provides valuable insights into the demographic, clinical, histopathological types, and anterior segment optical coherence tomography (AS-OCT) features of conjunctival tumors in a tertiary care hospital. Our findings indicate that malignant tumors are associated with several factors, including older age, amelanotic pigmentation, larger lesion diameters, and the presence of corneal involvement. Additionally, the presence of homogeneous and hyporeflexive lesions on AS-OCT suggests the potential diagnostic value of this technology in the context of ocular malignancies. These findings highlight the importance of early and detailed clinical evaluations to improve the detection and management of conjunctival malignancies.

Key predictors of malignancy, such as amelanotic pigmentation and corneal involvement, should be considered critical red flags during clinical assessments. The observed trend of larger lesion diameters in malignant cases further emphasizes the need for heightened vigilance when encountering large conjunctival tumors. By promptly identifying and addressing these risk factors, clinicians can enhance patient outcomes and potentially reduce the morbidity associated with malignant conjunctival lesions.

For clinicians, the primary takeaway is the importance of a multimodal approach. While AS-OCT serves as an exceptional tool for identifying high-risk structural features, it cannot yet replace histopathology, especially in thick or pigmented lesions where shadowing limits posterior visualization. The future of the field lies in the refinement of these non-invasive “optical biopsies” through standardization, artificial intelligence, and vascular biomarkers. By integrating these advanced tools into clinical practice, the ophthalmological community can move toward a more precise, individualized approach to the diagnosis and management of conjunctival malignancies, ultimately improving both visual outcomes and patient survival.

**Ethics Committee Approval:** Ethics committee approval was obtained from Erciyes University Health Sciences Research Ethics Committee (Approval Number: 2025/365, Date: 09.07.2025).

**Informed Consent:** Written informed consent was not required due to the retrospective nature of this study.

**Conflict of Interest:** The authors have no conflicts of interest to declare.

**Funding:** The authors declared that this study received no financial support.

**Use of AI for Writing Assistance:** No use of AI-assisted technologies was declared by the authors.

**Author Contributions:** Concept – OO, FH, HS, FÖ; Design – OO, FH, HS, FÖ; Supervision – OO, FH, HS, FÖ; Resource – OO, HS; Materials – OO, HS; Data Collection and/or Processing – OO, FH, HS, FÖ; Analysis and/or Interpretation – OO, FH, HS, FÖ; Literature Review – OO, FH, HS, FÖ; Writing – OO, FH, HS, FÖ; Critical Review – OO, FH, HS, FÖ.

**Peer-review:** Externally peer-reviewed.

## REFERENCES

- Shields CL, Shields JA. Tumors of the conjunctiva and cornea. *Surv Ophthalmol* 2004;49(1):3-24. [\[CrossRef\]](#)
- Mirzayev I, Gündüz AK, Gündüz ÖÖ, Özalp Ateş FS, Nalçı Baytaroğlu H. Demographic and clinical features of conjunctival tumours at a tertiary care centre. *Clin Exp Optom* 2022;105(7):708-14. [\[CrossRef\]](#)
- Koç İ, Kapucu Y, Kıratlı H. Clinical Features and Treatment Results of Conjunctival Melanoma: Cross-Sectional Study. *Acta Medica* 2023;54(1):54-8. [\[CrossRef\]](#)
- Esmaeli B, Gleber-Netto F, Sagiv O, Pickering C, Gross N, Ning J, et al. Abstract 2501: High mutation burden and ultraviolet light signature in conjunctival squamous cell carcinoma. *Cancer Res* 2024;84(6\_Supplement):2501. [\[CrossRef\]](#)
- Shields CL, Alset AE, Boal NS, Casey MG, Knapp AN, Sugarman JA, et al. Conjunctival Tumors in 5002 Cases. Comparative Analysis of Benign Versus Malignant Counterparts. The 2016 James D. Allen Lecture. *Am J Ophthalmol* 2017;173:106-33. [\[CrossRef\]](#)
- Gündüz AK, Mirzayev I, Okcu Heper A, Kuzu I, Gahramanlı Z, Cansız Ersöz C, et al. Anterior segment optical coherence tomography in ocular surface tumours and simulating lesions. *Eye (Lond)* 2023;37(5):925-37. Erratum in: *Eye (Lond)* 2023;37(5):1045. Erratum in: *Eye (Lond)* 2023;37(16):3517-8. [\[CrossRef\]](#)
- Nanji AA, Sayyad FE, Galor A, Dubovy S, Karp CL. High-Resolution Optical Coherence Tomography as an Adjunctive Tool in the Diagnosis of Corneal and Conjunctival Pathology. *Ocul Surf* 2015;13(3):226-35. [\[CrossRef\]](#)
- Gündüz AK, Mirzayev I, Ersöz CC, Heper AO, Gündüz Ö, Ateş FSÖ. Anterior Segment Swept-Source Optical Coherence Tomography in Ocular Surface Tumors and Simulating Lesions and Correlation with Histopathologic Diagnosis. *Cornea* 2025;44(7):806-18. [\[CrossRef\]](#)

9. Vandembroucke JP, von Elm E, Altman DG, Gøtzsche PC, Mulrow CD, Pocock SJ, et al.; STROBE Initiative. Strengthening the Reporting of Observational Studies in Epidemiology (STROBE): explanation and elaboration. *Epidemiology* 2007;18(6):805-35. [\[CrossRef\]](#)
10. Pellerano F, Gil G, Rosario A, Mañón N, Vargas T, Vizcaíno G. Survey of 138 Conjunctival Tumors in the Dominican Republic. *Ophthalmic Epidemiol* 2020;27(4):278-82. [\[CrossRef\]](#)
11. He LF, Tang SY, Wang YJ, Zhang Y, Huang SM, Huang XJ. Incidence, clinical features, and survival outcomes of primary malignant conjunctival tumor: a US population-based retrospective cohort analysis based on the SEER database (1975-2018). *Transl Cancer Res* 2025;14(3):1609-25. [\[CrossRef\]](#)
12. Besteiro AVM, de Castro Leao RF, da Trindade Junior CJS, Fernandes ACM, Xavier TC, Lima VHA. Epidemiological Profile of Patients with Conjunctival Tumors in a Reference Ophthalmological Hospital in Eastern Amazonia. *BJHR* 2023;6(1):4257-79. Portuguese. [\[CrossRef\]](#)
13. Grossniklaus HE, Green WR, Luckenbach M, Chan CC. Conjunctival lesions in adults. A clinical and histopathologic review. *Cornea* 1987;6(2):78-116. [\[CrossRef\]](#)
14. Dalvin LA, Yaghy A, Vaidya S, Pacheco RR, Perez AL, Lally SE, et al. Conjunctival Melanoma: Outcomes Based on Age at Presentation in 629 Patients at a Single Ocular Oncology Center. *Cornea* 2021;40(5):554-63. [\[CrossRef\]](#)
15. Paridaens AD, Minassian DC, McCartney AC, Hungerford JL. Prognostic factors in primary malignant melanoma of the conjunctiva: a clinicopathological study of 256 cases. *Br J Ophthalmol* 1994;78(4):252-9. [\[CrossRef\]](#)
16. García Onrubia L, Pacheco-Callirgos GE, Portero-Benito A, García-Álvarez C, Carreño Salas E, Muñoz-Moreno MF, et al. Spectrum of conjunctival tumours in a Spanish series: A review of 462 cases. *Eur J Ophthalmol* 2020;30(6):1403-9. [\[CrossRef\]](#)
17. Shields CL, Sioufi K, Alset AE, Boal NS, Casey MG, Knapp AN, et al. Clinical Features Differentiating Benign From Malignant Conjunctival Tumors in Children. *JAMA Ophthalmol* 2017;135(3):215-24. [\[CrossRef\]](#)
18. Brouwer NJ, Marinkovic M, Luyten GPM, Shields CL, Jager MJ. Lack of tumour pigmentation in conjunctival melanoma is associated with light iris colour and worse prognosis. *Br J Ophthalmol* 2019;103(3):332-7. [\[CrossRef\]](#)
19. Levecq L, De Potter P, Jamart J. Conjunctival nevi clinical features and therapeutic outcomes. *Ophthalmology* 2010;117(1):35-40. [\[CrossRef\]](#)
20. Shields CL, Belinsky I, Romanelli-Gobbi M, Guzman JM, Mazzuca D Jr, Green WR, et al. Anterior segment optical coherence tomography of conjunctival nevus. *Ophthalmology* 2011;118(5):915-9. [\[CrossRef\]](#)
21. Shousha MA, Karp CL, Perez VL, Hoffmann R, Ventura R, Chang V, et al. Diagnosis and management of conjunctival and corneal intraepithelial neoplasia using ultra high-resolution optical coherence tomography. *Ophthalmology* 2011;118(8):1531-7. [\[CrossRef\]](#)
22. Kieval JZ, Karp CL, Abou Shousha M, Galor A, Hoffman RA, Dubovy SR, et al. Ultra-high resolution optical coherence tomography for differentiation of ocular surface squamous neoplasia and pterygia. *Ophthalmology* 2012;119(3):481-6. [\[CrossRef\]](#)
23. Shousha MA, Karp CL, Canto AP, Hodson K, Oellers P, Kao AA, et al. Diagnosis of ocular surface lesions using ultra-high-resolution optical coherence tomography. *Ophthalmology* 2013;120(5):883-91. [\[CrossRef\]](#)
24. Janssens K, Mertens M, Lauwers N, de Keizer RJ, Mathysen DG, De Groot V. To Study and Determine the Role of Anterior Segment Optical Coherence Tomography and Ultrasound Biomicroscopy in Corneal and Conjunctival Tumors. *J Ophthalmol* 2016;2016:1048760. [\[CrossRef\]](#)
25. Venkateswaran N, Sripawadkul W, Karp CL. The role of imaging technologies for ocular surface tumors. *Curr Opin Ophthalmol* 2021;32(4):369-78. [\[CrossRef\]](#)
26. Karp CL, Mercado C, Venkateswaran N, Ruggeri M, Galor A, Garcia A, et al. Use of High-Resolution Optical Coherence Tomography in the Surgical Management of Ocular Surface Squamous Neoplasia: A Pilot Study. *Am J Ophthalmol* 2019;206:17-31. [\[CrossRef\]](#)
27. Venkateswaran N, Mercado C, Tran AQ, Garcia A, Diaz PFM, Dubovy SR, et al. The use of high resolution anterior segment optical coherence tomography for the characterization of conjunctival lymphoma, conjunctival amyloidosis and benign reactive lymphoid hyperplasia. *Eye Vis (Lond)* 2019;6:17. [\[CrossRef\]](#)
28. Solebo AL, Ang M, Bellchambers A, Chu CJ, Denniston AK, Downie LE, et al. Development of the advised protocol for OCT study terminology and elements anterior segment OCT extension reporting guidelines (APOSTEL-AS): Study protocol. *PLoS One* 2025;20(11):e0331272. [\[CrossRef\]](#)
29. Enaholo E, Okoye G, Musa M, Suleman A, Ojo O, Foti R, et al. High-resolution optical coherence tomography for screening ocular surface tumors: Historical markers and future directions. *World J Clin Cases* 2025;13(29):108046. [\[CrossRef\]](#)
30. Rajagopal R, Vijayaraghavan M, Jothi Balaji J, Jayavel K. Anterior segment optical coherence tomography in conjunctival ocular surface disorders - A review. *Indian J Ophthalmol* 2025;73(4):543-52. [\[CrossRef\]](#)