



This work is licensed under a Creative Commons Attribution-NonCommercial 4.0 International License.

Interscapular-thoracic Amputation: A Giant Dermatofibrosarcoma Protuberans Tumor

Alberto De Anda-Coronado¹ , Nohemí C. López-Leonar¹ , Eduardo Navarro-Bahena² ,
Gerardo E. Muñoz-Maldonado¹

ABSTRACT

Background: Dermatofibrosarcoma protuberans (DFSP), an uncommon sarcoma of the dermis, is a low-grade, spindle-cell tumor that usually grows slowly and has a high local recurrence rate, but rarely metastasizes to distant sites. The diagnosis is based on histopathology and the standard treatment is wide surgical excision with tumor-free margins.

Case Report: Described is the case of a 75-year-old female who presented with a giant tumor on her upper right arm that had been increasing in size for a year. A biopsy provided the diagnosis of DFSP. Radical surgery was performed and the arm was disarticulated from the scapula.

Conclusion: Treatment for DFSP typically involves surgical excision; however, the size of the tumor in the present case was exceptionally large. Disarticulation offered the best prognosis.

Keywords: Dermatofibrosarcoma protuberans, interscapular-thoracic amputation, oncology surgery, sarcoma

Cite this article as:

De Anda-Coronado A,
López-Leonar NC,
Navarro-Bahena E,
Muñoz-Maldonado GE.
Interscapular-thoracic
Amputation: A Giant
Dermatofibrosarcoma
Protuberans Tumor.
J Clin Pract Res 2023;
45(3): 300-2.

INTRODUCTION

Dermatofibrosarcoma protuberans (DFSP) is a rare cutaneous neoplasm, constituting 1% of all soft tissue sarcomas, with an overall incidence of some 0.8–5 cases per million population per year (1). It is a fibroblastic tumor that commonly appears in adults 35–50 years of age. The majority of DFSPs occur on the thorax/trunk (50%), followed by the upper extremities (20%) and the neck (10%) (2). DFSP is considered a low-grade malignant neoplasm that displays slow growth with local invasion (3). It rarely progresses to distant metastasis (<5%). The lungs are the most common site of metastasis, a consequence of the typical hematogenous spread of sarcomas. Recurrence is frequent, and particularly in cases of resections without an adequate margin (2–3 cm). The tumor develops in the dermis and infiltrates the adjacent subcutaneous tissues. In most cases, it remains localized to these layers; however, in patients with a long growth period or recurrence, invasion of the fascia, muscle, periosteum, and bone has been observed (4).

CASE REPORT

The patient was a 75-year-old female with no known history of chronic diseases. Her medical history included consumption of tobacco and alcohol. She presented with a tumor in the right deltoid region, which she reported had increased in size progressively over the course of a year to approximately 20 cm in diameter. The tumor was violaceous in color with evident purulent secretion and occasional bleeding (Fig. 1).

The patient was referred to the dermatology clinic, which performed a lesion biopsy. The result was a DFSP (8 mitoses per 10 high-power fields, without evidence of necrosis or lymphovascular invasion). She was then referred to the general surgery clinic for surgical treatment.

A thoracoabdominal contrast-enhanced computed tomography scan revealed a tumor with irregular borders of heterogeneous density extending to the shoulder and axillary region through the muscular planes measuring approximately 9x9x20 cm, suggestive of a neoplastic process, without evidence of metastasis (Fig. 2). Magnetic resonance imaging showed evidence of a solid heterogeneous cutaneous and subcutaneous lesion with lobulated edges that was partially defined, extending into the proximal and middle third of the arm, of heterogeneous intensity, hypointense in T-1 and T-2 images. Patchy restriction was visible in diffusion-weighted images, as well as areas suggestive of necrosis in the interior, and infiltration of the deltoid, biceps, and pectoralis major muscles, without bone involvement.

Based on the histopathology and other findings, interscapular-thoracic disarticulation was considered the best approach. The patient provided voluntary consent prior to surgery. Once the structures of the brachial plexus and large axillary vessels had been identified and ligated, the humerus was disarticulated from the scapula and the clavicle, leaving a 3-cm radial margin. A histopathological report confirmed DFSP Grade II with tumor-free surgi-

¹Department of General Surgery, Hospital Universitario Dr. José Eleuterio González, Monterrey, Mexico

²Division of Oncology Surgery, Department of General Surgery, Hospital Universitario Dr. José Eleuterio González, Monterrey, Mexico

Submitted
11.06.2022

Revised
23.06.2022

Accepted
12.07.2022

Available Online
17.10.2022

Correspondence

Gerardo E. Muñoz-Maldonado,
Hospital Universitario Dr.
José Eleuterio González,
Department of General
Surgery, Monterrey, Mexico
Phone: +52 81838911
e-mail: cevam99@gmail.com

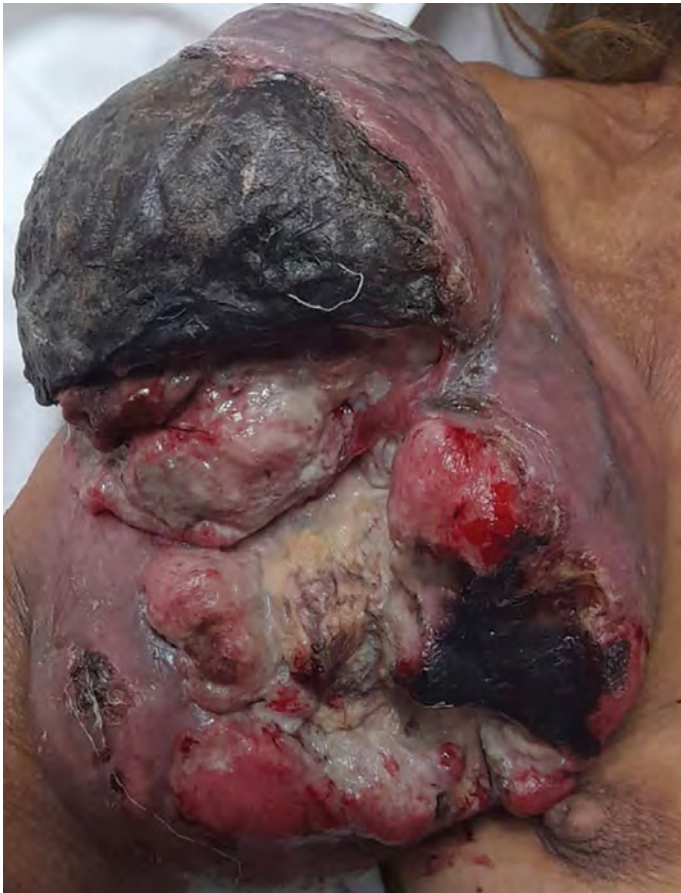

Figure 1. Clinical image of giant dermatofibrosarcoma protuberans located on the right arm

cal margins (Fig. 3). The postsurgical course was favorable and the patient was discharged on the third postoperative day and followed up in the outpatient clinic. The patient was also followed up by the medical oncology team, who elected to pursue a surveillance regime based on the tumor-free surgical margins. One year after surgery, there had been no recurrence.

DISCUSSION

DFSP is an uncommon type of dermal sarcoma that rarely produces metastasis but has a high local recurrence rate. Fibrosarcomatous transformation is seen only in a small percentage of patients, but the incidence can be as high as 80% in patients who develop metastasis (5). The most frequent site of metastasis is the lungs; dissemination to the lymph nodes is rare.

The cornerstone of the diagnosis is the histopathological study. The most frequent findings in the immunohistochemical study are CD34 and Apo D positivity. Molecular analysis, such as fluorescence in-situ hybridization or reverse transcriptase-polymerase chain reaction analysis, may be necessary in some cases. Due to clinical manifestations and histopathological and CD34 staining profiles that can overlap with other tumors, DFSP must be distinguished from other lesions, such as schwannoma, intradermal spindle cell lipoma, solitary fibrous tumor, and dermatofibroma. Careful examination of the clinical presentation and immunohistochemistry is needed for a thorough diagnosis (5).

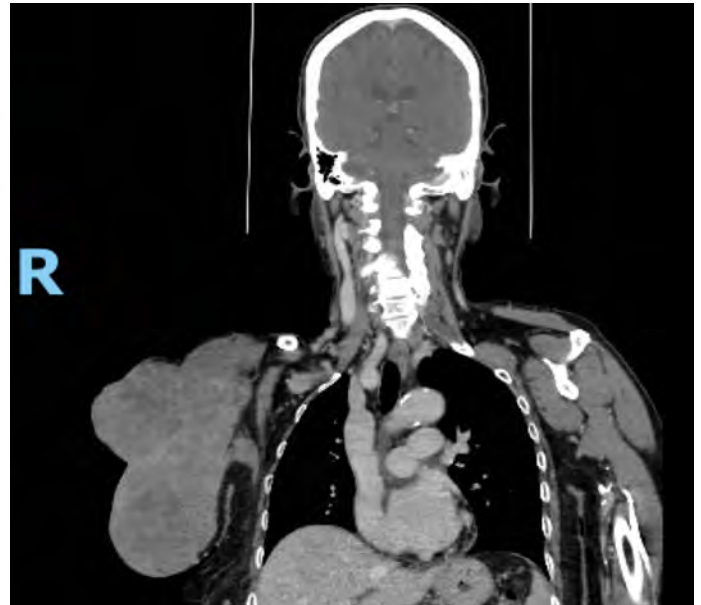


Figure 2. Computed tomography image of the lesion

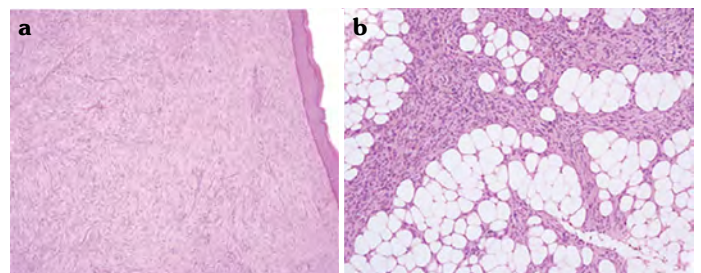


Figure 3. Histopathological specimen, typical of dermatofibrosarcoma protuberans. (a) Panoramic view with hematoxylin and eosin staining, (b) dermal plaque infiltrates in the subcutis

Common clinical features of DFSP include a nodule with an elevated, dome-shaped appearance that is most often seen on the extremities. In the early stages it is often misdiagnosed. Histologically, bland and uniform spindle cells with patternless bands of collagen, chronic inflammatory cells, and large histiocytes may be found in the dermis, and hyperkeratosis may be present in the epidermis. SMA and factor XIIIa expression; CD34, CD99, STAT6, and vimentin positivity; HMB-4 and S-100 negativity; nuclear hyperchromasia, atypia, and pleomorphism are other histological features (6).

Schwannoma, for example, is a round, ovoid, well-circumscribed, solid neoplasm, also most often seen on the limbs. It typically has a fibrous capsule and a biphasic growth pattern: hyperchromatic spindle cells with myxoid hypocellular components, however, schwannoma is diffusely positive for S100 (6).

The standard treatment for DFSP is surgical excision. Mohs micrographic surgery is generally preferred to ensure adequate margins and appears to offer the lowest percentage of recurrence (7). In locations where this technique cannot be performed, a wide excision with margins of 2–3 cm is recommended. There is no evidence that chemotherapy is helpful in this type of lesion. However, it has been reported that soft-tissue sarcomas may demonstrate a good response to radiotherapy (RT).

Adjuvant or neoadjuvant RT can influence surgical margins. RT can be used in stage II and III patients preoperatively to reduce the size of the tumor and facilitate a free margin, surgical resection, or postoperatively. RT may also be used as palliative therapy when the health status or prognosis is poor or when curative excision is not possible, such as in the presence of metastasis (8).

Neoadjuvant therapy with imatinib has also been demonstrated to reduce tumor size to allow for effective surgery in locally advanced cases with very extensive lesions (9, 10).

CONCLUSION

Here we present a patient with an advanced tumor, which progressively increased in size and underwent surgery. A radical treatment performed with interscapular-thoracic disarticulation including soft tissue tumors that invade the brachial plexus, the axillary vascular axis, involvement of the proximal third of the humerus or scapula, tumors that cannot be resected conservatively, as palliative surgery to control pain, bleeding or uncontrolled infection.

Informed Consent: Written informed consent was obtained from patients who participated in this study.

Peer-review: Externally peer-reviewed.

Author Contributions: Concept – AAC, NCLL, ENB, GEMM; Design – AAC, NCLL, ENB, GEMM; Supervision – AAC, NCLL, ENB, GEMM; Data Collection and/or Processing – AAC, NCLL; Analysis and/or Interpretation – AAC, NCLL; Literature Search – AAC, NCLL; Writing – ENB; Critical Reviews – GEMM.

Conflict of Interest: The authors have no conflict of interest to declare.

Financial Disclosure: The authors declared that this study has received no financial support.

REFERENCES

1. Rutkowski P, Debiec-Rychter M. Current treatment options for dermatofibrosarcoma protuberans. *Expert Rev Anticancer Ther* 2015; 15(8): 901–9. [\[CrossRef\]](#)
2. Mujtaba B, Wang F, Taher A, Aslam R, Madewell JE, Spear R, et al. Dermatofibrosarcoma protuberans: Pathological and imaging review. *Curr Probl Diagn Radiol* 2021; 50(2): 236–40. [\[CrossRef\]](#)
3. Llombart B, Serra C, Requena C, Alsina M, Morgado-Carrasco D, Través V, et al. Guidelines for diagnosis and treatment of cutaneous sarcomas: Dermatofibrosarcoma protuberans. *Actas Dermosifiliogr (Engl Ed)* 2018; 109(10): 868–77. [\[CrossRef\]](#)
4. Li Y, Wang C, Xiang B, Chen S, Li L, Ji Y. Clinical features, pathological findings and treatment of recurrent dermatofibrosarcoma protuberans. *J Cancer* 2017; 8(7): 1319–23. [\[CrossRef\]](#)
5. Hao X, Billings SD, Wu F, Stultz TW, Procop GW, Mirkin G, et al. Dermatofibrosarcoma protuberans: Update on the diagnosis and treatment. *J Clin Med* 2020; 9(6): 1752. [\[CrossRef\]](#)
6. Thway K, Noujaim J, Jones RL, Fisher C. Dermatofibrosarcoma protuberans: pathology, genetics, and potential therapeutic strategies. *Ann Diagn Pathol* 2016; 25: 64–71. [\[CrossRef\]](#)
7. Banach BS, Antic T, Bridge JA, Cipriani NA, Frye L, Krausz TN, et al. Fine-needle aspiration of dermatofibrosarcoma protuberans metastasizing to hemithorax with superior vena cava compression: Case report and literature review. *Diagn Cytopathol* 2019; 47(8): 797–802. [\[CrossRef\]](#)
8. Hoefkens F, Dehandschutter C, Somville J, Meijnders P, Van Gestel D. Soft tissue sarcoma of the extremities: pending questions on surgery and radiotherapy. *Radiat Oncol* 2016; 11(1): 136. [\[CrossRef\]](#)
9. Allen A, Ahn C, Sangüeza OP. Dermatofibrosarcoma protuberans. *Dermatol Clin* 2019; 37(4): 483–8. [\[CrossRef\]](#)
10. Ramos Tellez AM, Zarzuel VM, Garcia D, Jara Garcia F, Mairal Sanroman C, Bru Pomer A. Desarticulación interescapulotorácica en cirugía oncológica ortopédica.[Article in French]. *Rev Española Cirugía Osteoart* 2019; 54: 105–8.