

Transient Sinoatrial and Atrioventricular Block in the Acute Phase of COVID-19 Infection

Ömer Ferudun Akkuş, Gökay Taylan, Kenan Yalta

Department of Cardiology, Trakya University Faculty of Medicine, Edirne, Türkiye

ABSTRACT

Background: Ongoing research on Coronavirus Disease 2019 (COVID-19) infection has revealed that it is associated with serious damage to many organs, not only the lungs. This infection can also affect the cardiovascular system and lead to serious cardiac pathologies. In this article, we present a case of transient bradyarrhythmia in a patient who was diagnosed with COVID-19 and recovered spontaneously with treatment.

Case Report: A 74-year-old male patient was hospitalized with symptomatic COVID-19 infection. At the time of hospitalization, the patient was asymptomatic from a cardiac standpoint, but was found to have sinoatrial exit block type 2-2, intermittent Mobitz type 2 atrioventricular block, and sinus bradycardia. The medical team decided to closely monitor the patient, who responded well to COVID-19 treatment and did not develop bradyarrhythmia as his symptoms improved.

Conclusion: Patients with COVID-19 infection should be closely monitored for bradyarrhythmia. Permanent pacemaker should not be rushed in these patients.

Keywords: Arrhythmia, atrioventricular block, bradyarrhythmia, COVID-19, sinus node dysfunction.



Cite this article as:

Akkuş ÖF, Taylan G, Yalta K. Transient Sinoatrial and Atrioventricular Block in the Acute Phase of COVID-19 Infection. J Clin Pract Res 2023; 45(4): 409–12.

Address for correspondence:

Ömer Ferudun Akkuş,
Department of Cardiology,
Trakya University Faculty of
Medicine, Edirne, Türkiye
Phone: +90 284 236 76 41
E-mail:
akkusferudun@gmail.com

Submitted: 27.07.2022

Revised: 17.08.2022

Accepted: 09.10.2022

Available Online: 07.05.2023

©Copyright 2023 by Erciyes
University Faculty of Medicine -
Available online at www.jcpres.com

INTRODUCTION

Coronavirus Disease 2019 (COVID-19) infection causes serious morbidity and mortality due to systemic organ involvement and dysfunction. In 2019, cases of pneumonia with acute respiratory failure were associated with a new type of coronavirus in Wuhan, China. This disease was later named COVID-19 and rapidly spread worldwide, becoming a global epidemic.¹ Ongoing research on COVID-19 has revealed that the infection is associated with serious damage to many organs, not only the lungs. This includes the cardiovascular system, which can lead to severe cardiac pathologies such as acute myocardial infarction, myocarditis, arrhythmia, myocardial injury, pulmonary embolism, and heart failure.²

Arrhythmias are frequently detected in patients with COVID-19 due to reasons such as respiratory distress, fever, and systemic inflammatory response, with tachyarrhythmia being observed more commonly.³ However, cases of bradyarrhythmia associated with COVID-19 infection have also been reported in the literature.^{4,5} In this article, we present a case of transient bradyarrhythmia diagnosed with COVID-19 that spontaneously improved with treatment.



This work is licensed under
a Creative Commons
Attribution-NonCommercial
4.0 International License.

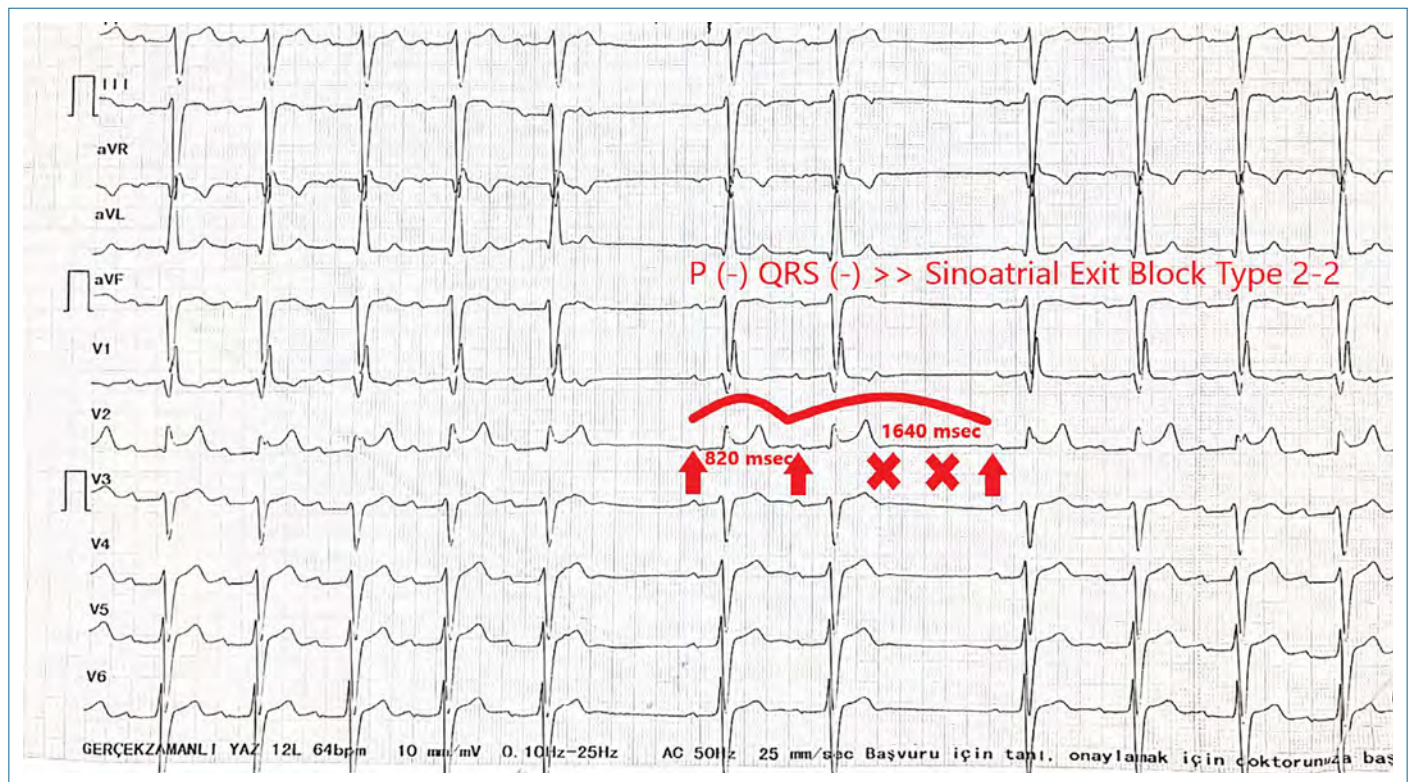


Figure 1. 12 - Lead Electrocardiogram showing Sinoatrial Exit Block Type 2-2.

CASE REPORT

Our 74-year-old male patient was admitted to the emergency department with complaints of fever, malaise, shortness of breath, cough and widespread muscle pains that had been present for 3 days. The patient had a known chronic kidney disease and a history of previous cerebrovascular disease, but no known coronary artery disease, history of arrhythmia, heart failure, or syncope. Laboratory findings showed: C-reactive protein (CRP) 13 mg/L (0–5), lymphocyte count 0.88 (1.32–3.57), hemoglobin 12.9 g/dL (13.7–17.5), urea 57 mg/dL (17–49), creatinine 1.6 mg/dL (0.72–1.25), potassium 4.4 mmol/L (3.5–5.1), high-sensitivity troponin I: 42.2–45.1 ng/L (0–34).

Electrocardiography (ECG) was taken because the patient was bradycardic and was found to be compatible with sinoatrial exit block type 2-2 (Fig. 1). The patient was not using any sinus or atrioventricular (AV) node blocking medications, and serum electrolytes were within normal range. There was no significant valve pathology in the patient, who had an ejection fraction of 60%. The patient's radiological examinations were consistent with COVID-19, and he was placed on telemetry monitoring and hospitalized. Symptomatic treatment was initiated for the patient, whose Severe Acute Respirato-

ry Syndrome Coronavirus 2 (SARS-CoV2) polymerase chain reaction (PCR) test was positive. During hospitalization, intermittent Mobitz type 2 atrioventricular block and sinus bradycardia were detected in the patient, who remained asymptomatic in terms of cardiac symptoms (Fig. 2). No bradyarrhythmia was observed after the tenth day of admission, during which the patient underwent continued cardiac telemetry monitoring throughout the treatment period.

At the end of COVID-19 treatment, a 24-hour ECG and Holter examination were performed. Sinus rhythm and rare atrial extra beats were observed, but bradyarrhythmia was not detected. A medical follow-up decision was made for the patient, who responded well to COVID-19 treatment and did not develop bradyarrhythmia as his symptoms improved.

DISCUSSION

SARS-CoV 2 infection is believed to contribute to the pathophysiology of secondary heart disease through systemic inflammation and resultant myocardial damage.⁶ Hypoxia, shock (cardiogenic or septic), widespread systemic inflammation, electrolyte disturbances (such as hypokalemia), or accompanying myocardial ischemia may play a role in the etiology of arrhythmias in COVID-19 patients.⁷ The mechanism

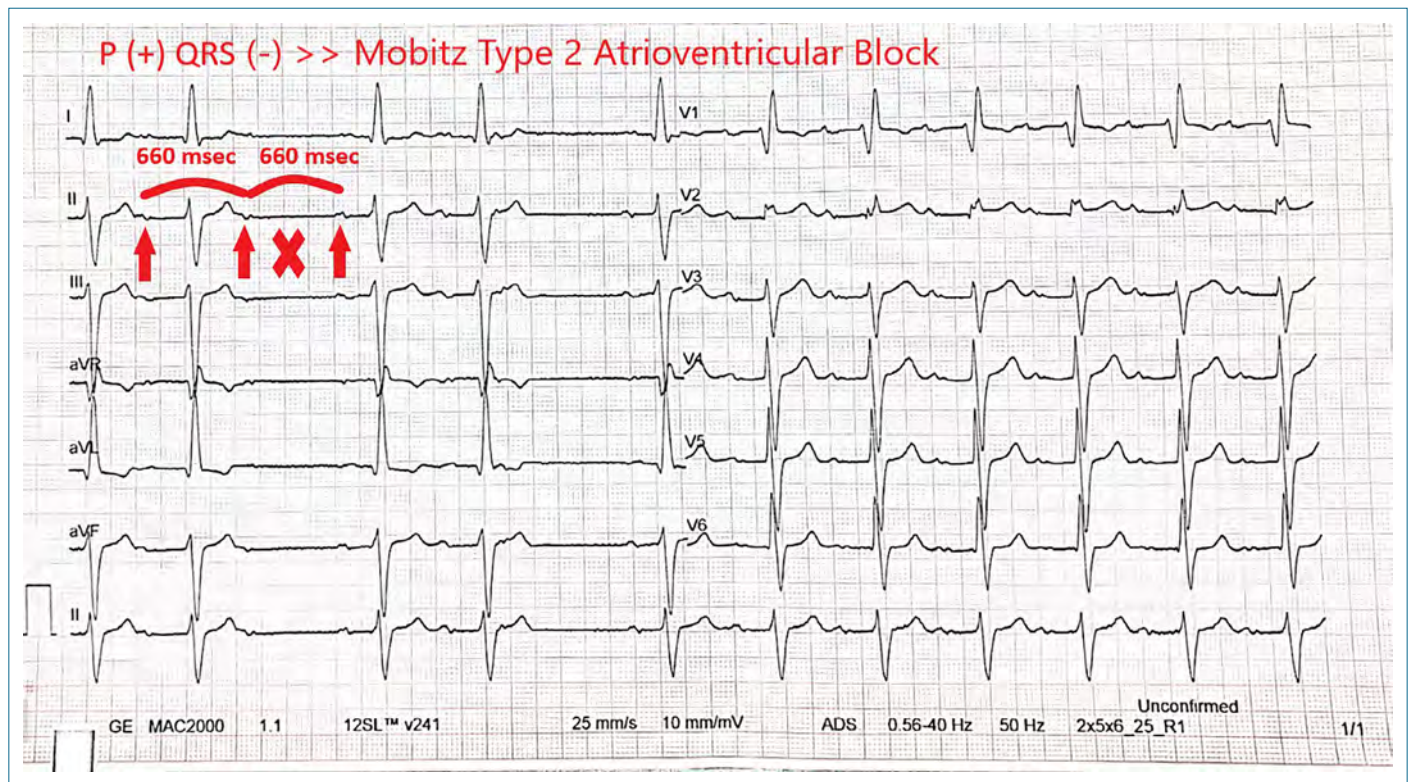


Figure 2. 12 - Lead Electrocardiogram showing Mobitz Type 2 Atrioventricular Block.

by which COVID-19 causes conduction system disorders is not fully understood. Myocardial damage and edema due to viral infection are considered to one mechanism, while nodal or conduction system infiltration is another.⁸

Babapoor-Farrokhran et al.⁴ reported in their case report that bradyarrhythmia seen in COVID-19 patients improved after treatment of the infection without the need for any intervention. Additionally, Elices-Teja et al.⁹ reported a case of sinus node syndrome requiring pacemaker implantation in a COVID-19 patient. In our case, the patient had bradyarrhythmia despite no use of nodal blocking agents, no electrolyte disturbances, and normal echocardiographic findings. However, the patient recovered after COVID-19 treatment, suggesting that bradyarrhythmia developed secondary to viral infection.

CONCLUSION

Patients with COVID-19 infection should be closely monitored for the development of bradyarrhythmia. In these patients, planning for permanent pacemaker implantation should not be rushed. Furthermore, long-term follow-up studies are needed to determine whether recurrent bradyarrhythmia will develop.

Peer-review: Externally peer-reviewed.

Informed Consent: Written informed consent was obtained from patients who participated in this study.

Author Contributions: Concept – ÖFA, GT; Design – ÖFA, GT, KY; Supervision – GT, KY; Data Collection and/or Processing – ÖFA, KY; Analysis and/or Interpretation – ÖFA, GT, KY; Literature Search – ÖFA; Writing – ÖFA, GT; Critical Reviews – GT, KY.

Conflict of Interest: The authors have no conflict of interest to declare.

Financial Disclosure: The authors declared that this study has received no financial support.

REFERENCES

1. World Health Organization. Director-General's remarks at the media briefing on 2019-nCoV on 11 February 2020. Available from: URL: <http://www.who.int/dg/speeches/detail/who-director-general-s-remarks-at-the-media-briefing-on-2019-ncov-on-11-february-2020>. Accessed Feb 12, 2020.
2. Aktoz M, Altay H, Aslanger E, Atalar E, Atar İ, Aytekin V, et al. Turkish Cardiology Association Consensus Report: COVID-19 pandemic and cardiovascular diseases (May 13, 2020). *Turk Kardiyol Dern Ars* 2020; 48(Suppl 1): 1–87.

3. Wang Y, Wang Z, Tse G, Zhang L, Wan EY, Guo Y et al. Cardiac arrhythmias in patients with COVID-19. *J Arrhythm* 2020; 36(5): 827–36. [\[CrossRef\]](#)
4. Babapoor-Farrokhran S, Batnyam U, Wiener PC, Kanjanahattakij N, Khraisha O, Amanullah A, et al. Atrioventricular and sinus node dysfunction in stable COVID-19 patients. *SN Compr Clin Med* 2020; 2(11): 1955–8. [\[CrossRef\]](#)
5. Peigh G, Leya MV, Baman JR, Cantey EP, Knight BP, Flaherty JD. Novel Coronavirus 19 (COVID-19) associated sinus node dysfunction: A case series. *Eur Heart J Case Rep* 2020; 4(F11): 1–6. [\[CrossRef\]](#)
6. Driggin E, Madhavan MV, Bikdeli B, Chuich T, Laracy J, Biondi-Zoccai G, et al. Cardiovascular considerations for patients, health care workers, and health systems during the COVID-19 pandemic. *J Am Coll Cardiol* 2020; 75(18): 2352–71. [\[CrossRef\]](#)
7. Lazzarini PE, Boutjdir M, Capecchi PL. COVID-19, arrhythmic risk, and inflammation: Mind the gap! *Circulation* 2020; 142(1): 7–9. [\[CrossRef\]](#)
8. Babapoor-Farrokhran S, Rasekhi RT, Gill D, Babapoor S, Amanullah A. Arrhythmia in COVID-19. *SN Compr Clin Med* 2020; 2(9): 1430–5. [\[CrossRef\]](#)
9. Elices-Teja J, Bueno-Sacristán Á, Durán-Bobin O, Ferreira-González AM, Gonzalez-Juanatey C. Sinus Node Syndrome in a critical COVID-19 patient. *Rev Port Cardiol (Engl Ed)* 2021; 40(12): 987–8. [\[CrossRef\]](#)