

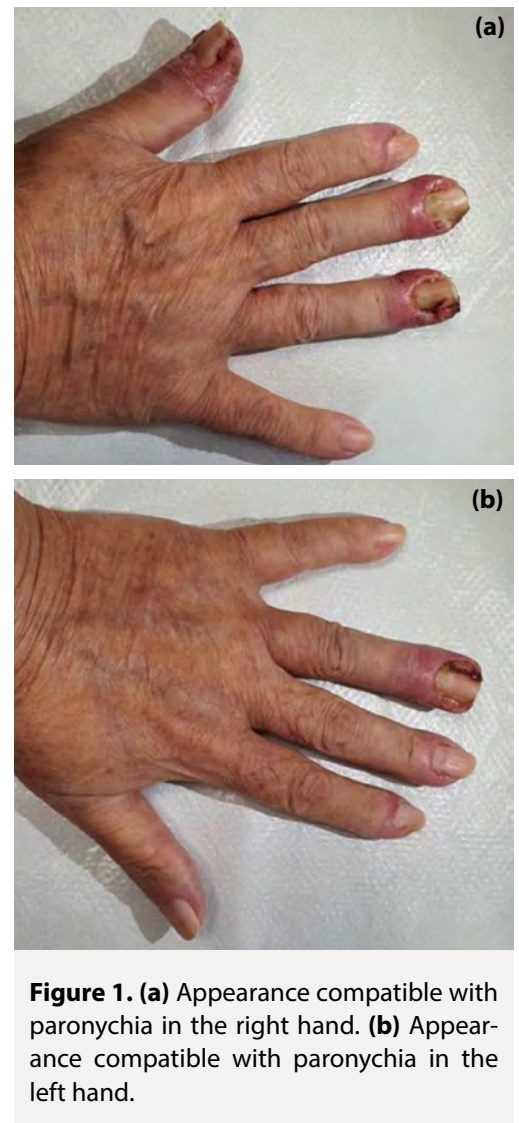
## Panitumumab Induced Paronychia and Trichomegaly

Okday Ünsal, Osman Sütcüođlu, Nuriye Özdemir

Department of Medical Oncology, Gazi University Faculty of Medicine, Ankara, Türkiye

Panitumumab is a recombinant, fully humanized IgG2 monoclonal antibody that targets the epidermal growth factor receptor (EGFR). Panitumumab is indicated in patients with metastatic colorectal cancer with progressive refractory disease. It is well known that targeted therapies are well tolerated; however, they may cause different toxicities than conventional chemotherapeutic agents. Nail-related adverse effects are frequently observed with EGFR inhibitors (EGFRIs). So far, few case reports have been published on the nail-related adverse effects of EGFRIs.<sup>1</sup> While paronychia is a nail-related adverse effect of panitumumab, nail toxicity is one of the distinctive dermatological adverse effects of targeted therapies, especially EGFRIs.<sup>2</sup> Trichomegaly is another very rare adverse effect.<sup>3</sup>

A 55-year-old female patient was admitted to the clinic with ileus in 2021. Metastasis was detected in the liver in the patient during the operation. The colostomy was opened. The patient was diagnosed with colon cancer (T4N2M1 - Stage IV). Upon detection of N-Ras, K-Ras and BRAF wild-type in the pathological examination, FOLFOX-panitumumab treatment was initiated. After the third cycle of the treatment, the patient developed a grade 2 papulopustular rash. Skin lesions were regressed with medical treatment. The treatment was continued because the patient had partial response in the follow-up imaging at the 3<sup>rd</sup> month. In the 5<sup>th</sup> month of treatment, the patient presented with edema and painful erythema in the nail folds of the hands and left feet. The patient had paronychia and eyebrow elongation in both hands and left foot (Fig. 1, 2) (Grade 2). Panitumumab treatment was discontinued. The patient was started on antibiotic therapy. Treatment with FOLFOX was continued after the patient had a partial response.



**Figure 1. (a)** Appearance compatible with paronychia in the right hand. **(b)** Appearance compatible with paronychia in the left hand.



### Cite this article as:

Ünsal O, Sütcüođlu O, Özdemir N. Panitumumab Induced Paronychia and Trichomegaly. J Clin Pract Res 2023; 45(4): 422-3.

### Address for correspondence:

Okday Ünsal.  
Department of Medical Oncology, Gazi University Faculty of Medicine, Ankara, Türkiye  
Phone: +90 312 508 72 04  
E-mail: oktayunsal@gazi.edu.tr

Submitted: 03.01.2023

Revised: 04.01.2023

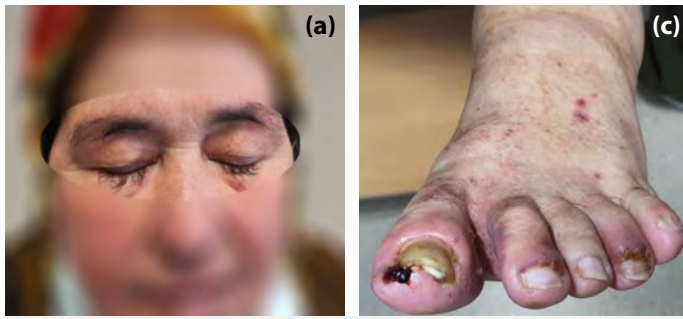
Accepted: 23.02.2023

Available Online: 11.07.2023

©Copyright 2023 by Erciyes University Faculty of Medicine - Available online at www.jcpres.com



This work is licensed under a Creative Commons Attribution-NonCommercial 4.0 International License.



**Figure 2.** (a) Significant elongation of the eyebrows were observed. (b) Image compatible with paronychia on the left toes.

The clinical features of EGFR-induced nail and eyelash toxicity will become better understood as more case reports are published.

**Peer-review:** Externally peer-reviewed.

**Informed Consent:** Written informed consent was obtained from patients who participated in this study.

**Author Contributions:** Concept – OÜ; Design – OÜ; Supervision – NÖ; Materials – OÜ, OS; Data Collection and/or Processing – OÜ, OS; Analysis and/or Interpretation – NÖ; Literature Search – OÜ, NÖ; Writing – OÜ, OS; Critical Reviews – OÜ, NÖ.

**Conflict of Interest:** The authors have no conflict of interest to declare.

**Financial Disclosure:** The authors declared that this study has received no financial support.

## REFERENCES

1. Yorulmaz A, Yalcin B. Panitimumab-Induced Paronychia: A Case Report and a Brief Review of the Literature. *Skin Appendage Disord* 2021; 7(2): 123–6. [\[CrossRef\]](#)
2. Lacouture M, Sibaud V. Toxic side effects of targeted therapies and immunotherapies affecting the skin, oral mucosa, hair, and nails. *Am J Clin Dermatol* 2018; 19(S1): 31–9. [\[CrossRef\]](#)
3. Sarzi Sartori D, Larangeira de Almeida A, Santana Pereira de Oliveira G, de Almeida HL Jr. Scanning electron microscopy of panitimumab-induced eyelash and hair alterations - Pili canaliculi. *An Bras Dermatol* 2022; 97(2): 240–42. [\[CrossRef\]](#)