

Evaluation of the Relationship Between Histopathological Findings in Appendectomy Specimens and *Enterobius vermicularis* Infection

İ Selahattin Aydemir,¹ İ Meryem Gümüş,¹ İ Merve İnceman,² İ Zeynep Taş Cengiz,¹
İ Mehmet Hafit Bayır,³ İ Hasan Yılmaz¹

¹Department of Parasitology, Van Yüzüncü Yıl University Faculty of Medicine, Van, Türkiye

²Department of Infectious Pathology, Van Training and Research Hospital, Van, Türkiye

³Department of Histology and Embryology, Van Yüzüncü Yıl University Faculty of Medicine, Van, Türkiye

ABSTRACT

Objective: This study aimed to assess the relationship between *Enterobius vermicularis* and appendicitis by determining the frequency of *E. vermicularis* in appendectomy specimens obtained after a preliminary diagnosis of appendicitis.

Materials and Methods: Retrospective evaluation was conducted on the results of appendectomy specimens examined histopathologically at Van Training and Research Hospital Pathology Laboratory from March 2016 to March 2022. Hematoxylin-eosin stained slides from 7,814 appendectomy specimens were scrutinized for the presence of *E. vermicularis*, acute inflammation, fecaloid material, lymphoid hyperplasia, obliteration, perforation, phlegmonous appendicitis, and peritonitis. Furthermore, slides stained with hematoxylin-eosin (H&E) from patients testing positive for *E. vermicularis* were re-evaluated by the author in pathology.

Results: *E. vermicularis* was identified in the appendectomy specimens of 50 (0.64%) out of 7,814 patients who underwent appendectomies. In histopathological examinations, the occurrence of lymphoid hyperplasia and fibrous obliteration was higher in *E. vermicularis*-positive patients compared to those who teste negative. Findings revealed that the mean white blood cell count (WBC) was lower in *E. vermicularis*-positive patients than in negative patients, while the mean eosinophil percentage (EO%) was higher.

Conclusion: These findings imply that although the parasite is not a direct causative factor for appendicitis, it may contribute to the development of factors that result in obstruction in certain cases.

Keywords: *Enterobius vermicularis*, lymphoid hyperplasia, fibrous obliteration, eosinophil, appendicitis.



Cite this article as:

Aydemir S, Gümüş M, İnceman M, Taş Cengiz Z, Bayır MH, Yılmaz H. Evaluation of the Relationship Between Histopathological Findings in Appendectomy Specimens and *Enterobius Vermicularis* Infection. J Clin Pract Res 2023; 45(5): 463–70.

Address for correspondence:

Selahattin Aydemir.
Department of Parasitology, Van Yüzüncü Yıl University Faculty of Medicine, Van, Türkiye
Phone: +90 530 777 87 08
E-mail: saydmr23@gmail.com

Submitted: 12.05.2023

Revised: 07.07.2023

Accepted: 23.08.2023

Available Online: 12.09.2023

Erciyes University Faculty of Medicine Publications - Available online at www.jcpr.com



This work is licensed under a Creative Commons Attribution-NonCommercial 4.0 International License.

INTRODUCTION

Appendicitis stands as the most prevalent cause of emergency abdominal surgery. Its hallmark indicators encompass periumbilical pain escalating to the right lower quadrant, along with mild fever, dizziness, and nausea.¹ While the etiological factors and incidence of appendicitis exhibit regional variations, luminal obstruction predominantly emerges as the principal contributor.² This obstruction commonly arises due to fecalitis and lymphoid hyperplasia.³ Additionally, it has been postulated that parasitic infections like enterobiasis, ascariasis, balantidiasis, teniasis, actinomycosis, schistosomiasis, amebiasis, and trichuriasis may also incite obstruction.^{4–6} While the connection between acute appendicitis and parasitic infections remains a topic of debate, various parasites are frequently discovered within the appendiceal lumen post-appendectomy procedures.⁷ Notably, *Enterobius vermicularis* ranks among the most prevalent parasites encountered, particularly within this context.⁸

E. vermicularis, the causal agent of enterobiasis, commonly known as pinworm, is an intestinal parasite exclusive to humans, belonging to the nematode class. While it mainly resides in the large intestine, particularly the cecum and rectal regions, it sporadically survives in sections of the small intestine adjacent to these areas, apart from the stomach or other gastrointestinal sections. Although this parasite is known to take refuge in the appendix, the definitive relationship between *E. vermicularis* and appendicitis continues to be contentious.^{4,7,9}

This study was conducted to assess the correlation between *E. vermicularis* and appendicitis by analyzing the prevalence of *E. vermicularis* in appendectomy specimens obtained following an initial diagnosis of appendicitis.

MATERIALS AND METHODS

The retrospective evaluation encompassed the results of appendectomy specimens that underwent histopathological examination in Van Training and Research Hospital Pathology Laboratory between March 2016 and March 2022. The study included patients ranging from ages 0 to 83, who had undergone appendectomy with surgical intervention following a preliminary diagnosis of appendicitis from various outpatient clinics. Hematoxylin-eosin stained slides from 7,814 appendectomy specimens were examined for the presence of *E. vermicularis*, acute inflammation, fecaloid material, lymphoid hyperplasia, obliteration, perforation, phlegmonous appendicitis, and peritonitis. Additionally, hematoxylin-eosin (H&E) stained slides from patients testing positive for *E. vermicularis* were subject to re-evaluation by the pathology author. The dimensions of the appendix, including length and diameter, were noted. Patient information such as age and gender, clinical findings, white blood cell count (WBC), and eosinophil percentage (EO%) data were retrieved from the hospital automation system.

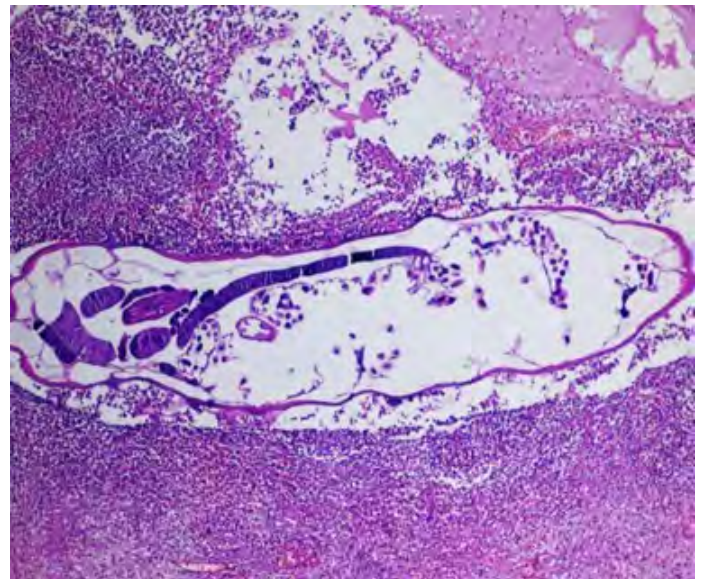


Figure 1. Section of an adult *E. vermicularis* with acute inflammatory cells, including eosinophils, abundant leukocytes with polymorphous nuclei in the appendix lumen (Hematoxylin & Eosin \times 200).

Statistical Analysis

The normality of continuous data was examined using the Kolmogorov-Smirnov test. Given normally distributed data, the independent t-test was applied. For categorical data, statistical analysis involved Fisher's Exact test, Chi-Square test, and Z test. Calculations were conducted using statistical packages such as the Statistical Package for the Social Sciences (SPSS) (IBM SPSS for Windows, version 21) and Minitab (version 14). A statistical significance level of 5% was employed, and all tests were evaluated as two-tailed. Additionally, 95% Confidence Intervals for clinical significance were calculated.^{10,11}

Ethics Committee Approval

The Non-interventional Clinical Research Ethics Committee of Van Yüzüncü Yıl University approved the study protocol (Decision no: 2022/10-01. Date: 14.10.2022).

RESULTS

During routine histopathological examination of appendectomy specimens from a total of 7,814 patients, *E. vermicularis* adult specimens (Fig. 1) and/or eggs (Fig. 2) were identified in 50 (0.64%) cases. Specifically, *E. vermicularis* was found in appendectomy specimens from 23 (0.73%) out of 3,165 female patients and 27 (0.58%) out of 4,648 male patients. A statistical analysis showed no significant difference between *E. vermicularis* positivity and gender ($p=0.437$).

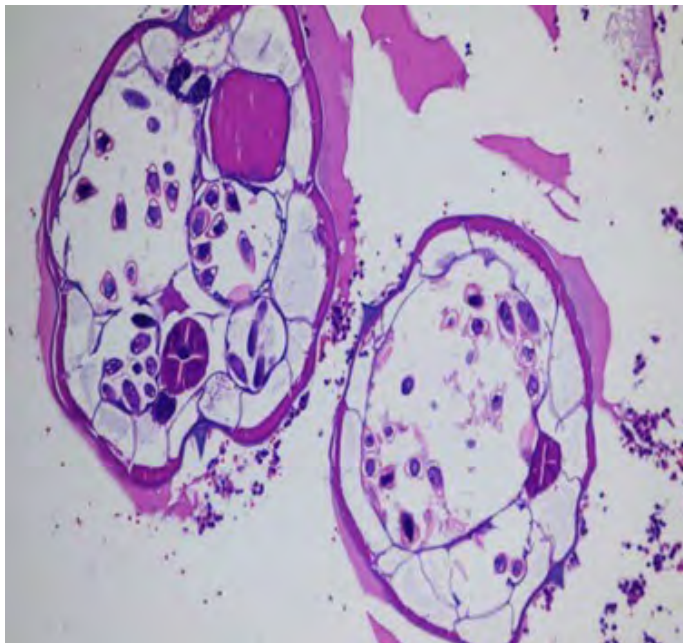


Figure 2. Cross-section of *E. vermicularis* containing eggs with multiple double-layered hyaline chitin shells (Hematoxylin & Eosin × 200).

The age range of patients who underwent an appendectomy was 0 to 86 years (with a mean age of 22.13±13.96 years), and 71.27% of them were older than 18. *E. vermicularis*-positive patients were aged between 6 and 49 years (with a mean age of

Table 1. Relationship between age groups and *E. vermicularis* positivity

Age groups	<i>E. vermicularis</i> negative patients		<i>E. vermicularis</i> positive patients		p*
	n	%	n	%	
0–10	540	97.83	12	2.17 ^a	0.001
11–18	1,671	98.70	22	1.30 ^a	
19–30	2,987	99.63	11	0.37 ^b	
≥31	2,566	99.80	5	0.20 ^b	
Total	7,764	99.36	50	0.64	

*: Chi-Square test; n: Number of patients; a, b: Indicate different groups.

16.86±9.12 years), and 68% of them were younger than 18 (Fig. 3). The statistical analysis revealed a significant difference between *E. vermicularis* positivity and age groups (refer to Table 1). A logistic regression analysis was conducted to determine the impact of age groups on *E. vermicularis* positivity rates. The results indicated that children aged 0–10 are at 1.9 times higher risk (odds ratio) than individuals aged 11–18. Similarly, the risk is 6.4 times higher than that of individuals aged 18–30, and 12.1 times higher than that of individuals older than 30 years.

Appendix length varied between 2 cm and 11 cm, with a mean length 6.56±1.48, while the diameter ranged between 0.2 cm and 3 cm, with a mean diameter of 0.9±0.31 cm across all pa-

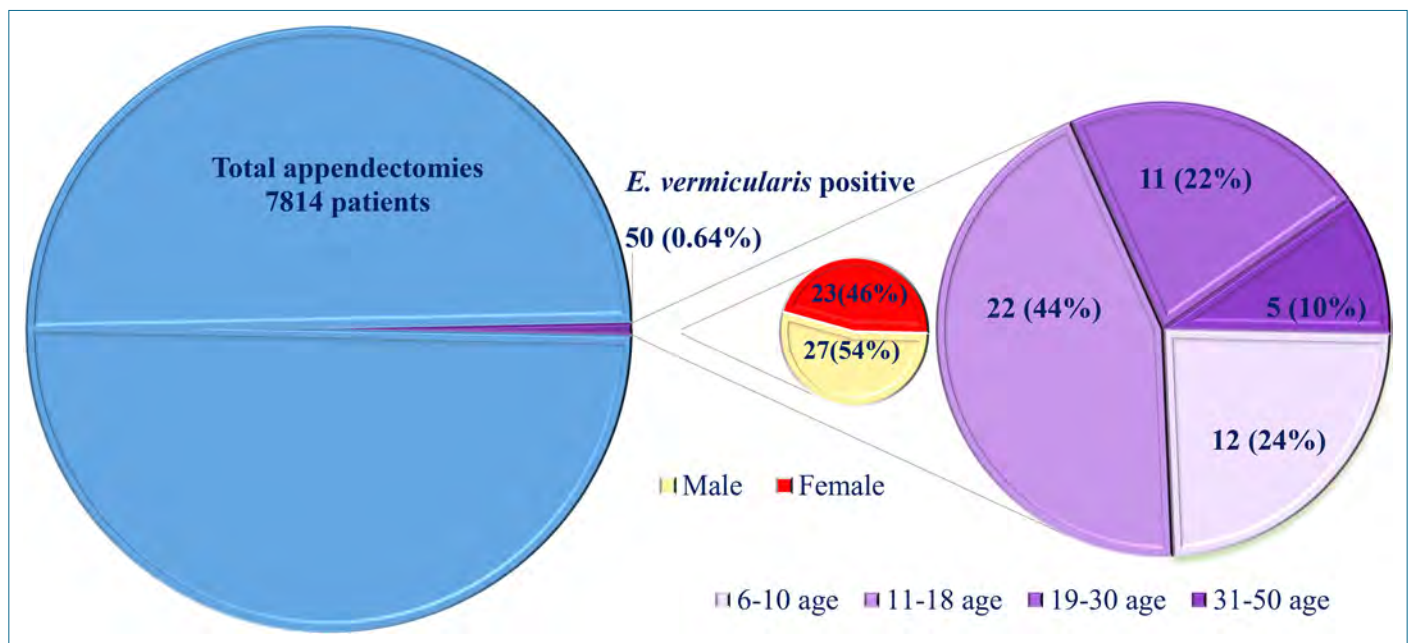


Figure 3. Distribution of *E. vermicularis*-positive patients by gender and age groups.

Table 2. Variation of appendix length and diameter according to age group and *E. vermicularis* positivity

Age groups	Length of the appendix (cm)			Diameter of the appendix (cm)		
	Total patients (Mean±SD)	<i>E. vermicularis</i> positive patients (Mean±SD)	p*	Total patients (Mean±SD)	<i>E. vermicularis</i> positive patients (Mean±SD)	p*
0–10	5.55±1.91	6.5±1.32	0.540	0.75±0.37	0.60±0.10	0.420
11–18	6.36±0.09	6.59±0.25	0.850	0.88±0.41	0.86±0.41	0.521
19–30	6.90±1.90	6.7±2.28	0.786	0.92±0.20	0.86±0.20	0.642
≥31	6.51±2.02	6.93±0.94	0.821	0.93±1.07	0.9±0.55	0.754

*: Independent t-test; SD: Standard deviation.

Table 3. Distribution of patients with acute appendicitis

Age groups	Acute appendicitis	Number of patients (%)	Number of <i>E. vermicularis</i> positive patients (%)	p
0–10	Yes	385 (69.75)	7 (1.82)	0.384*
	No	167 (30.25)	5 (2.99)	
11–18	Yes	1,344 (79.39)	16 (1.19)	0.437*
	No	349 (20.61)	6 (1.72)	
19–30	Yes	2,628 (87.66)	8 (0.30)	0.131*
	No	370 (12.34)	3 (0.81)	
≥31	Yes	2,288 (88.99)	4 (0.17)	0.617**
	No	283 (11.01)	1 (0.35)	
Total	Yes	6,645 (85.04)	36 (0.54)	0.010*
	No	1,169 (14.96)	14 (1.20)	

*: Chi-Square Test; **: Fisher's Exact Test.

tients. When comparing mean appendix length and diameter between *E. vermicularis*-negative and -positive patients based on age groups, no statistically significant differences were observed (Table 2).

Acute appendicitis was diagnosed in 85.04% (6,645/7,814) of the appendectomy cases, and in 72% (36/50) of the cases with *E. vermicularis*. Statistical analysis revealed a significant difference between the two groups ($p=0.010$). However, when the cases were stratified according to age groups, the incidence of acute appendicitis in *E. vermicularis*-positive and *E. vermicularis*-negative cases did not exhibit statistical differences (Table 3).

All patients who underwent an appendectomy presented with abdominal pain. Furthermore, there was no statistical difference observed in the occurrence of clinical symptoms such as sensitivity, rebound tenderness, guarding, nausea, and vomiting between *E. vermicularis*-positive and -negative patients (Table 4).

In histopathological examinations, the frequency of lymphoid hyperplasia and fibrous obliteration was higher in *E. vermicularis*-positive patients compared to negative patients. This disparity between the two groups was statistically significant. The frequencies of fecaloid, perforation, phlegmonous appendicitis, and peritonitis were comparable between the groups (Table 4). Notably, neoplastic lesions were not identified in any of the *E. vermicularis*-positive samples.

Analysis revealed that the mean WBC count in *E. vermicularis*-positive patients was lower than that in *E. vermicularis*-negative patients, and the mean EO% count was higher (Table 4). The differences in WBC ($p=0.008$) and EO% ($p=0.003$) values between the two groups were statistically significant. However, based on Confidence Interval calculations, the differences in WBC and EO values between the two groups were not clinically significant.

Table 4. Distribution of findings in *E. vermicularis* positive and negative patients

Findings	<i>E. vermicularis</i> negative patients		<i>E. vermicularis</i> positive patients		p*
	n	%	n	%	
Histopathological findings					
Lymphoid hyperplasia					0.005
Yes	489	6.30	8	16.00	
No	7,275	93.70	42	84.00	
Fibrous obliteration					0.006
Yes	170	2.19	4	8.00	
No	7,594	97.81	46	92.00	
Fecaloid					0.321
Yes	1,027	13.23	9	18.00	
No	6,737	86.77	41	82.00	
Perforation					0.259
Yes	854	11.00	3	6.00	
No	6,910	89.00	47	94.00	
Phlegmonous appendicitis					0.375
Yes	1,119	14.41	5	10.00	
No	6,645	85.59	45	90.00	
Peritonitis					0.14
Yes	1,769	22.78	7	14.00	
No	5,995	77.22	43	86.00	
Clinical findings					
Sensibility					0.384
Yes	4,814	62.01	34	68.00	
No	2,950	37.99	16	32.00	
Rebound					0.157
Yes	4,193	54.01	22	44.00	
No	3,571	45.99	28	56.00	
Defense					0.510
Yes	3,675	47.33	26	52.00	
No	4,089	52.67	24	48.00	
Nausea					0.156
Yes	2,433	31.34	11	22.00	
No	5,331	68.66	39	78.00	
Vomiting					0.102
Yes	3,054	39.34	14	28.00	
No	4,710	60.66	36	72.00	
Blood findings, Mean±SD, [95% CI]					
WBC (10 ¹² /L)	13.78±4.59 [4,784–22,776]		11.76±4.49 [2,560–20,560]		0.008**
EO (%)	0.7±1.09 [-1,436–2,836]		1.38±2.044 [2,626–5,386]		0.003**

*: Chi-Square Test; **: Independent t-test; n: Number of patients; SD: Standard deviation; CI: Confidence interval.

DISCUSSION

Out of all parasites that infiltrated the human body, *E. vermicularis* is the most commonly detected parasite in the appendix post-surgery.¹² The prevalence of *E. vermicularis* in appendices varies depending on the geographical area under study. In a meta-analysis by Taghipour et al.,¹³ the highest and lowest global rates of appendiceal invasion by *E. vermicularis* were observed in Africa (8%) and the Americas (2%), respectively. On a country-specific basis, Nigeria reported the highest rate (33%), while Venezuela reported the lowest rate (<1%). In studies carried out in Türkiye, *E. vermicularis* was identified in appendectomy specimens at rates ranging from 0.70% and 2.8%.^{3,4,9,14–17} In the current study, *E. vermicularis* was detected in 50 (0.64%) out of the 7,814 appendectomy specimens examined.

E. vermicularis infection constitutes a public health concern in many countries, regardless of socioeconomic status. The infection spreads more easily within childcare centers (including orphanages and kindergartens), schools, and overcrowded households. Among society, the most affected group is children.¹⁸ Hence, the higher infection rate detected in pediatric age groups using the cellophane band method, compared to other age groups, is also anticipated in the histopathological examination of appendectomy specimens. This study reveals that appendiceal invasion is more prevalent in patients under 18 years of age compared to those over 18.

Information about *E. vermicularis* invading the appendix has existed in medical literature for over a century.¹⁹ However, the parasite's role in the etiology of appendicitis remains contentious. Some authors propose that *E. vermicularis* invades the mucosa post-appendectomy to escape hypoxia, while others report that the parasite invades the appendix mucosa in connection with ulceration and inflammation.⁹ Several studies cite inflammation rates ranging from 13% to 37% in appendicitis samples infested with pinworms.⁴ Inflammation has also been noted in certain cases involving *E. vermicularis* in the appendix.^{7,20} Some researchers suggest that *E. vermicularis* might simulate an acute appendicitis-like clinical presentation by obstructing the lumen or inducing a hypersensitivity reaction in the tissue.^{20,21} Certain researchers have also suggested that *E. vermicularis* in the appendix could lead to pathological changes encompassing a spectrum from lymphoid hyperplasia to acute phlegmonous inflammation.²² It is postulated that lymphoid hyperplasia might give rise to a clinical condition that is radiologically indistinguishable from appendicitis and resembles acute appendicitis.⁹ Pehlivanoglu et al.⁹ identified lymphoid hyperplasia in all positive cases of *E. vermicularis*, while da Silva et al.²³ proposed a correlation between the presence of *E. vermicularis* and lymphoid hyperplasia. This study determined that the frequency of lymphoid hyperplasia in histopathological examinations was greater in *E. vermicularis*-pos-

itive patients compared to their negative counterparts. This finding suggests that *E. vermicularis* could be a potential cause of lymphoid hyperplasia, which might consequently result in clinical presentations similar to appendicitis.

In this study, the incidence of fibrous obliteration in histopathological examinations was higher in *E. vermicularis*-positive patients than in negative patients. Fibrous obliteration of the appendix entails the substitution of the mucosa and submucosa with fibrotic tissues due to the loss of normal appendiceal mucosa and Peyer's patches; it is a condition that frequently imitates the symptoms of acute appendicitis. While a patient's physical examination and laboratory findings could aid in differential diagnosis, most cases are confirmed through histopathological examination of the appendectomy specimen.²⁴ It is believed that fibroblastic and neural cells are accompanied by eosinophils and mast cells in fibrous obliteration, with eosinophils potentially contributing to the fibrosis process.⁹ We believe that the relationship between fibrous obliteration and *E. vermicularis* in this study can be explained through the role of eosinophils in the fibrosis process. The fact that eosinophilia was significantly more pronounced in *E. vermicularis*-positive patients compared to their negative counterparts ($p=0.003$) supports our interpretation.

E. vermicularis infection can exhibit clinical features similar to those of acute appendicitis.¹⁹ According to Hammond et al.,²⁵ whether it triggers acute appendicitis or not, *E. vermicularis* may inhabit the appendix and lead to outcomes resembling acute appendicitis. This study noted that the clinical manifestations in *E. vermicularis*-positive patients mirrored those in other patients who underwent an appendectomy.

A limitation of our study lies in its retrospective design. Furthermore, an important constraint is that the study was exclusively conducted using data from a single hospital. Another drawback of the study is the inability to ascertain the density of *E. vermicularis* in the intestines of patients with *E. vermicularis* detected in their appendectomy specimens.

CONCLUSION

This study identified a statistically significant presence of *E. vermicularis* in some appendectomy specimens wherein lymphoid hyperplasia or fibrous obliteration was identified as the cause of obstruction. This outcome suggests that although the parasite does not directly induce appendicitis, it may contribute to factors leading to obstruction in specific cases. Consequently, it was deduced that *E. vermicularis* could potentially be a contributory factor in appendicitis development. Treating positive patients for this parasite as a risk factor could therefore be beneficial. Additionally, conducting etiological studies to more comprehensively elucidate the role of *E. vermicularis* in appendicitis formation and implementing necessary precautions would be advisable.

Peer-review: Externally peer-reviewed.

Ethics Committee Approval: The Van Yüzüncü Yıl University University Non-interventional Clinical Research Ethics Committee granted approval for this study (date: 14.10.2022, number: 2022/10-01).

Informed Consent: Written informed consent was obtained from patients who participated in this study.

Author Contributions: Concept – MG, SA, ZTC, HY; Design – SA, MG, Mİ; Supervision – ZTC; Materials – Mİ, MG; Data Collection and/or Processing – SA, MG, MHB; Analysis and/or Interpretation – SA, MG, MHB, HY; Literature Search – MG, SA, MHB; Writing – SA, MG; Critical Reviews – ZTC, HY.

Conflict of Interest: The authors have no conflict of interest to declare.

Financial Disclosure: The authors declared that this study has received no financial support.

REFERENCES

- Orbatu D, Ekmekci S, Alaygut D, Sayan A, Özdemir T, Küçük Ü. Incidental findings on routine histopathological examination: analysis of pediatric appendectomy specimens J Dr Behcet Uz Child Hosp 2019; 9(3): 211–5. [CrossRef]
- Zaghlool DA, Hassan AA, Ahmed MA, Faidah HS. Incidental parasitic infections in surgically removed appendices: A retrospective analysis. J Egypt Soc Parasitol 2015; 45(3): 571–8. [CrossRef]
- Şahin S, Seçkin S. Histopathological diagnoses detected in appendectomy specimens. Fırat Med J 2018; 23(1): 23–7.
- Akbulut S, Tas M, Sogutcu N, Arikanoglu Z, Basbug M, Ulku A, et al. Unusual histopathological findings in appendectomy specimens: a retrospective analysis and literature review. World J Gastroenterol 2011; 17(15): 1961–70. [CrossRef]
- Wani I, Maqbool M, Amin A, Shah F, Keema A, Singh J, et al. Appendiceal ascariasis in children. Ann Saudi Med 2010; 30(1): 63–6. [CrossRef]
- Hasan A, Elhussiny MEA, Nagaty ME, Eid M, Elias AAK, Abdulmohaymen A, et al. Clinico-pathological profile of schistosomal appendicitis detected in surgically resected appendices: A retrospective study. Int J Surg Open 2023; 54: 100606. [CrossRef]
- Sarıçam G, Karaca G, Pehlivanlı F, Yıldırım K. A rare reason for acute appendicitis: *Enterobius vermicularis*. Van Tıp Derg 2014; 21(2): 114–6.
- Koşmaz K, Senlikci A, Suleyman M, Durhan A. Parasitic infestation in patients undergoing appendectomy: Retrospective analysis of 7,344 cases. Turk J Colorectal Dis 2021; 31(2): 105–9. [CrossRef]
- Pehlivanoğlu B, Aydın Türk B, İşler S, Özdaş S, Abeş M. Findings in appendectomies with *Enterobius vermicularis* infection: Pinworm is not a cause of appendicitis. Turkiye Parazitol Derg 2019; 43(1): 21–5. [CrossRef]
- McNeely ML, Warren S. Value of confidence intervals in determining clinical significance. Physiotherapy Canada 2006; 58(3): 205–11. [CrossRef]
- Ranstrom J. Why the P-value culture is bad and confidence intervals a better alternative. Osteoarthritis Cartilage 2012; 20(8): 805–8. [CrossRef]
- Hasan A, Nafie K, Abbadi O, Ibrahim AA. The utility of routine histopathological examination of the appendectomy specimens. Ann Path Lab Med 2020; 7(7): 320–6. [CrossRef]
- Taghipour A, Olfatifar M, Javanmard E, Norouzi M, Mirjalali H, Zali MR. The neglected role of *Enterobius vermicularis* in appendicitis: A systematic review and meta-analysis. PLoS One 2020; 15(4): e0232143. [CrossRef]
- Gümüş S, Söğütçü N. Parasitic appendicitis in 14,797 cases: A retrospective cohort study. Turkiye Parazitol Derg 2021; 45(2): 113–6. [CrossRef]
- Karaman U, Turkmen E, Meryem I, Karakaş T, Çolak C. Parasitosis in appendectomy cases. Eur J Intern Med 2010; 7(3): 317–20. [CrossRef]
- Yabanoğlu H, Aytaç HÖ, Türk E, Karagülle E, Çalışkan K, Belli S, et al. Parasitic infections of the appendix as a cause of appendectomy in adult patients. Turkiye Parazitol Derg 2014; 38(1): 12–6. [CrossRef]
- Yılmaz M, Akbulut S, Kutluturk K, Sahin N, Arabaci E, Ara C, et al. Unusual histopathological findings in appendectomy specimens from patients with suspected acute appendicitis. World J Gastroenterol 2013; 19(25): 4015–22. [CrossRef]
- Fan CK, Sonko P, Lee YL, Yin AW, Chuang TW, Kios R, et al. Epidemiologic study of *Enterobius vermicularis* infection among schoolchildren in the Republic of Marshall Islands. J Trop Med 2021; 2021: 6273954. [CrossRef]
- Hasan A, Nafie K, El-Sayed S, Nasr M, Abdulmohaymen A, Baheeg M, et al. *Enterobius vermicularis* in appendectomy specimens; Clinicopathological assessment: Cross sectional study. Ann Med Surg (Lond) 2020; 60: 168–72. [CrossRef]
- Panidis S, Paramythiotis D, Panagiotou D, Batsis G, Salonikidis S, Kaloutsis V, et al. Acute appendicitis secondary to *Enterobius vermicularis* infection in a middle-aged man: a case report. J Med Case Rep 2011; 5(1): 1–3. [CrossRef]
- Vleeschouwers W, Hofman P, Gillardin J-P, Meert V, Van Slycke S. Appendicitis-like clinical image elicited by *Enterobius vermicularis*: case report and review of the literature. Acta Chir Belg 2013; 113(2): 139–42. [CrossRef]

22. Efraimidou E, Gatopoulou A, Stamos C, Lirantzopoulos N, Kouklakis G. *Enterobius vermicularis* infection of the appendix as a cause of acute appendicitis in a Greek adolescent: a case report. *Cases J* 2008; 1(1): 376. [\[CrossRef\]](#)
23. da Silva DF, da Silva RJ, da Silva MG, Sartorelli AC, Rodrigues MA. Parasitic infection of the appendix as a cause of acute appendicitis. *Parasitol Res* 2007; 102(1): 99–102.
24. Choi SJ, Jang YJ, Lee D, Cho SH, Kim GC, Bae JH, et al. Two cases of fibrous obliteration of the appendix, mimicking acute appendicitis. *J Korean Radiol Soc* 2014; 70(6): 430–4.
25. Hammood ZD, Salih AM, Mohammed SH, Kakamad FH, Salih KM, Omar DA, et al. *Enterobius vermicularis* causing acute appendicitis, a case report with literature review. *Int J Surg Case Rep* 2019; 63: 153–6. [\[CrossRef\]](#)