





Rare Xanthogranulomatous Inflammation of the Nose

 Satesh Kumaran Ganeson,¹  Dakshaini Ananada Narayanan,²  Norhaslinda Abdul Gani,²
 Farah Dayana Zahedi¹

¹Department of Otorhinolaryngology and Head and Neck Surgery, University Kebangsaan Malaysia Medical Center, Kuala Lumpur, Malaysia

²Department of Otorhinolaryngology, Hospital Tuanku Ja'afar, Jalan Rasah, Seremban, Negeri Sembilan, Malaysia

ABSTRACT

Background: Juvenile xanthogranuloma is an uncommon benign mass that frequently arises among children. Regardless of its juvenile onset, the occurrence among the adult population is usually between the second and third decades of life.

Case Report: We would like to present a case of adult xanthogranuloma in a 30-year-old male and a brief literature review of its etiology, histopathology, and management.

Conclusion: Juvenile xanthogranuloma is a benign disease that is common in childhood but rare in adults. The diagnosis is confirmed by histological studies. The lesion is generally self-limiting and regresses spontaneously; however, surgical excision can be performed for cosmetic or diagnostic purposes.

Keywords: Juvenile xanthogranuloma, nose, multinucleated giant cells, benign neoplasm, histiocytes, non-Langerhans cell.



Cite this article as:

Ganeson SK, Narayanan DA, Gani NA, Zahedi FD. Rare Xanthogranulomatous Inflammation of the Nose. J Clin Pract Res 2023; 45(5): 521–3.

Address for correspondence:

Satesh Kumaran Ganeson.
Department of
Otorhinolaryngology and Head
and Neck Surgery, University
Kebangsaan Malaysia Medical
Center, Kuala Lumpur, Malaysia
Phone: +60172576261
E-mail:
sateshganeson@gmail.com

Submitted: 03.01.2023

Revised: 23.02.2023

Accepted: 04.05.2023

Available Online: 31.07.2023

Erciyes University Faculty of
Medicine Publications -
Available online at www.jcpres.com

INTRODUCTION

Juvenile xanthogranuloma is an uncommon benign mass that frequently arises among children. It was first mentioned by Adamson in 1905 when he described multiple yellow papules in a male child and called it congenital xanthoma multiplex. In 1954, Helwig and Hackney more precisely described the histopathological features of this lesion and coined the term juvenile xanthogranuloma.¹ Regardless of its juvenile onset, the occurrence among the adult population is usually between the second and third decades of life. It is typically characterized by single or multiple cutaneous nodules.²

CASE REPORT

A 30-year-old male presented to the Otorhinolaryngology clinic with a progressively enlarged right nasolabial mass for four months. Initially, the mass had a pustular appearance with minimal pus drainage. Subsequently, the mass grew exponentially with occasional pain. On examination, the mass appeared nodular, had a smooth surface with mild erythema. The mass was mobile and non-tender on palpation (Fig. 1). Anterior rhinoscopy and oral examination were unremarkable.



This work is licensed under
a Creative Commons
Attribution-NonCommercial
4.0 International License.

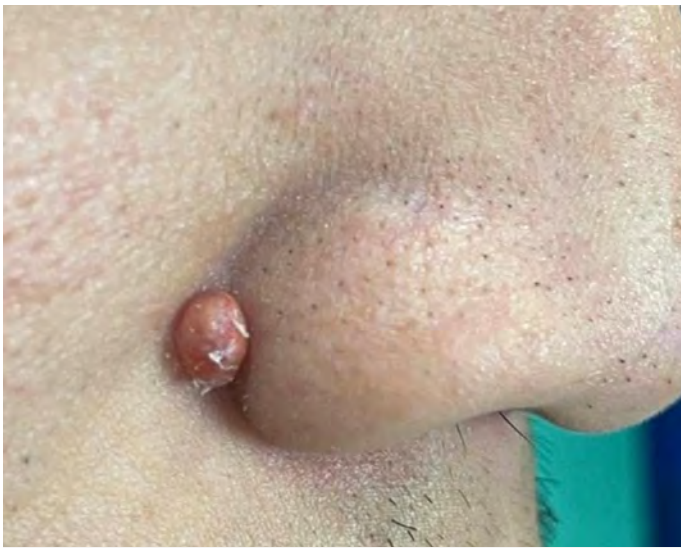

Figure 1. An image showing a smooth-surfaced, yellowish nodule over the nasolabial region.

We proceeded with excision of the nasolabial mass under local anesthesia, and the mass was sent for histopathological examination. Microscopic examination revealed a section of fibromuscular tissue with focal areas of ulceration. The underlying dermis was heavily infiltrated by mixed inflammatory cells, namely lymphocytes, neutrophils, foamy histiocytes, and Touton giant cells (Fig. 2). No malignant cells were present. Thus, the diagnosis of xanthogranulomatous inflammation was made. Subsequent follow-ups showed no recurrence.

DISCUSSION

Juvenile xanthogranuloma is a benign tumor of non-X histiocytosis³ that commonly occurs in childhood, with almost 70% occurring by the age of one year old,⁴ and 35% being congenital. The juvenile form has a male preponderance, while the 10–30% of cases that occur among adults show an equal sex distribution.⁵ The mass is usually a single or multiple lesions that are typically nodular or papular in appearance with yellowish-brown discoloration.⁶ It commonly occurs in the head and neck region, followed by the torso, back, and extremities.⁴ The extracutaneous sites frequently involved include the eye (most common), lungs, liver, testes and pericardium, oral cavity, larynx and temporal bone.²

Histologically, juvenile xanthogranulomas comprise of giant cells, histiocytes, and scarce acute inflammatory cells. Histiocytes, which predominate, commonly contains lipid and grow in solid sheets. Varying numbers of Touton type of multinucleated giant cells are also seen, with a wreath of nuclei arranged around eosinophilic foamy cytoplasm, characteristic of xanthogranuloma. Scanty inflammatory cells usually comprise of lymphocytes and polymorphonuclear leukocytes.⁴ Strongly

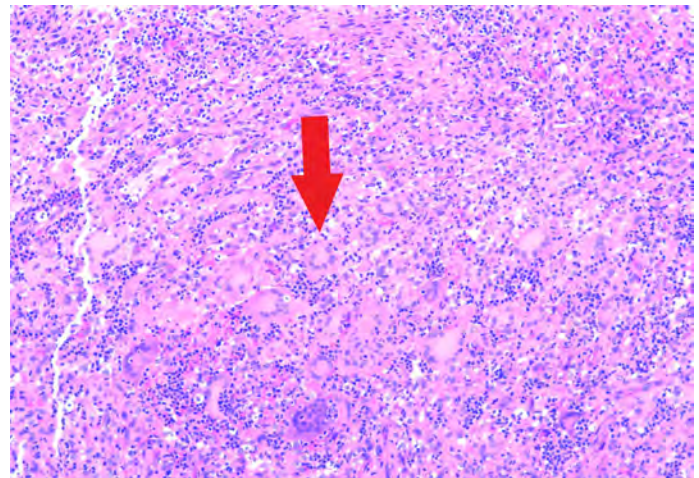


Figure 2. A histopathological image showing a section of fibromuscular tissue with focal areas of ulceration and infiltration by lymphocytes, neutrophils, foamy histiocytes, and Touton giant cells (indicated by the red arrow).

positive immunohistochemical analysis of xanthogranuloma is seen for Factor XIIIa, KP1, KiM1P, HAM 56, HHF 35, and vimentin, whereas S-100 protein, anti-Macrophages antibody (MAC 387), Leu M1, and desmin show a negative result.^{2,7}

Histiocytosis X has a close resemblance to juvenile xanthogranuloma. It is characterized by the presence of indented nuclei with invasion of the overlying epidermis seen on light microscopy. However, it is distinguished from juvenile xanthogranuloma by the presence of Birbeck granules on electron microscopy and positive staining for S-100 protein.^{1,4} Other differential diagnoses include papular xanthoma, xanthoma disseminatum, tubercous xanthoma, benign cephalic histiocytosis, and generalized eruptive histiocytosis. Malignant tumours include rhabdomyosarcoma, fibrosarcoma, and malignant fibrohistiocytoma, which may be mistaken for deep-seated juvenile xanthogranuloma.²

Adult xanthogranulomas are generally managed conservatively with frequent follow-up due to their self-limiting nature and spontaneous regression.² Almost 54% of cases of adult xanthogranuloma have spontaneous resolution.⁸ However, surgical excision is usually done for diagnosis or cosmesis. Other treatment options include steroid therapy and cryosurgery.²

CONCLUSION

Juvenile xanthogranuloma is a benign disease that is commonly seen in childhood, with rare occurrence in adults. The mass typically appears as painless yellowish papules. However, diagnosis can only be made through histological examination. The lesion is generally self-limiting and regresses spontaneously. Surgical excision can be performed for cosmetic or diagnostic purposes.

Peer-review: Externally peer-reviewed.

Informed Consent: Written informed consent was obtained from patients who participated in this study.

Author Contributions: Concept – SG, DAN, NAG, FDZ; Design – SG, DAN, FDZ; Supervision – NAG, FDZ; Data Collection and/or Processing – SG, DAN; Analysis and/or Interpretation – SG, DAN, NAG, FDZ; Literature Search – SG, DAN, FDZ; Writing – SG, DAN; Critical Reviews – NAG, FDZ.

Conflict of Interest: The authors have no conflict of interest to declare.

Financial Disclosure: The authors declared that this study has received no financial support.

REFERENCES

1. Saravanappa N, Rashid AM, Thebe PR, Davis JP. Juvenile xanthogranuloma of the nasal cavity. *J Laryngol Otol* 2000; 114(6): 460–1. [\[CrossRef\]](#)
2. Gedela VR, Roy D, Swift AC. Juvenile xanthogranuloma of the nose in an adult. *Hosp Med* 2002; 63(9): 564–5. [\[CrossRef\]](#)
3. Chu T, D’Angio GJ, Favara BE, Ladisch S, Nesbit M, Pritchard J. Histiocytosis syndromes in children. *Lancet* 1987; 2(8549): 41–2. [\[CrossRef\]](#)
4. Sonoda T, Hashimoto H, Enjoji M. Juvenile xanthogranuloma. Clinicopathologic analysis and immunohistochemical study of 57 patients. *Cancer* 1985; 56(9): 2280–6. [\[CrossRef\]](#)
5. Adya KA, Inamadar AC, Palit A, Pattar RS. A Translucent Yellow-brown Papule on the Nose. *J Cutan Aesthet Surg* 2019; 12(4): 255–7. [\[CrossRef\]](#)
6. Hernandez-Martin A, Baselga E, Drolet BA, Esterly NB. Juvenile xanthogranuloma. *J Am Acad Dermatol* 1997; 36(3 Pt 1): 355–67; quiz 368–9. [\[CrossRef\]](#)
7. Zelger B, Cerio R, Orchard G, Wilson-Jones E. Juvenile and adult xanthogranuloma. A histological and immunohistochemical comparison. *Am J Surg Pathol* 1994; 18(2): 126–35. [\[CrossRef\]](#)
8. Gu A, Guo H, Zhang L, Ma F. Facial multiple xanthogranuloma in an adult. *Indian J Dermatol Venereol Leprol* 2017; 83: 696–8. [\[CrossRef\]](#)