



Effect of Nd:YAG Laser Capsulotomy on Refraction and Anterior Segment Parameters in Patients with Posterior Capsular Opacification

Ender Sırakaya¹ , Alperen Ağadayı¹ , Bekir Küçük¹ , Mustafa Hepokur²

ABSTRACT

Objective: This prospective study aimed to determine the effect of neodymium-doped yttrium aluminum garnet (Nd:YAG) laser capsulotomy on spherical equivalent (SE), mean keratometry (Km), intraocular pressure (IOP), and changes in the anterior segment parameters, namely, anterior chamber depth (AChD), anterior chamber volume (AChV), anterior chamber angle (AChA), and central corneal thickness (CCoT).

Materials and Methods: Thirty-five pseudophakic eyes with posterior capsular opacification (PCO) of 35 patients (19 male and 16 female; mean age: 64.2±7.2 years) were included in this study. SE with automated refractometer, IOP with Goldmann applanation tonometry, Km, AChD, AChV, AChA, and CCoT measurements were performed using the Scheimpflug imaging system (Pentacam, Oculus) before laser capsulotomy and one day (first visit), one week (second visit), and one month (third visit) after laser capsulotomy.

Results: SE values significantly differed postoperatively over the course of the 3 visits ($p=0.005$, $p=0.002$, and $p=0.002$, respectively). IOP exhibited a statistically significant increase for the first and second visits, but not for the third visit ($p<0.001$, $p=0.004$, and $p=0.44$, respectively). AChD values significantly increased over the course of the 3 visits after laser capsulotomy ($p=0.038$, $p=0.037$, and $p=0.022$, respectively). No statistically significant differences were observed in the Km, AChV, AChA, and CCoT values before and after laser capsulotomy over the course of the 3 visits ($p=0.91$, $p=0.41$, $p=1.00$, and $p=1.00$, respectively).

Conclusion: Nd:YAG laser capsulotomy is a procedure with higher success rates that can change the anterior segment parameters. Our study revealed an increase in the SE, IOP, and AChD values after laser capsulotomy.

Keywords: Posterior capsule opacification, pentacam, YAG laser capsulotomy, anterior chamber depth

Cite this article as:
Sırakaya E, Ağadayı A, Küçük B, Hepokur M. Effect of Nd:YAG Laser Capsulotomy on Refraction and Anterior Segment Parameters in Patients with Posterior Capsular Opacification. Erciyes Med J 2019; 41(3): 316-20.

INTRODUCTION

Posterior capsule preservation in phacoemulsification surgery not only supports the intraocular lens (IOL) position but also prevents several complications by functioning as a barrier between the anterior and posterior segments (1, 2). The preserved posterior capsule may opacify over time. Posterior capsule opacification (PCO) is a common complication that causes vision defects after phacoemulsification (3). While the incidence of PCO varies from study to study, the cumulative incidence of Nd:YAG capsulotomy was found to be 13.2% 5 years after cataract surgery (4). The decision to perform capsulotomy treatment usually involves decreased visual acuity and visual impairment (5).

Since its introduction in 1980, neodymium-doped yttrium aluminum garnet (Nd:YAG) has been a successful gold standard therapy applied in the cases of decreased visual acuity due to PCO (2, 6). Although it is frequently applied and has a low risk of complication, serious complications such as increased intraocular pressure (IOP), corneal, and IOL injuries, IOL dislocation, pupil block, anterior vitreous prolapse, vitritis, retinal tear, and retinal detachment may occur (7–10). The evaluation of alteration in the parameters of the anterior segment after Nd:YAG laser capsulotomy may prove helpful in providing comprehensive information on ocular dynamics, refractive alteration, and mechanisms of potential complications.

Pentacam (Oculus Optikgeräte GmbH, Wetzlar, Germany) is a powerful, rapid, and noncontact anterior segment imaging system, which employs a rotational Scheimpflug camera system, provides quantitative information about the anterior and posterior corneal surfaces, anterior chamber depth (AChD), anterior chamber volume (AChV), anterior chamber angle (AChA), and central corneal thickness (CCoT).

This prospective study aims to evaluate the effect of Nd:YAG laser capsulotomy on spherical equivalent (SE), IOP, mean keratometry (Km), CCoT, AChD, AChV, and AChA values, as well as the use of a Pentacam Scheimpflug camera system in PCO patients.

¹Department of Ophthalmology, Kayseri City Training and Research Hospital, Kayseri, Turkey

²Department of Ophthalmology, İstanbul Medeniyet University Faculty of Medicine, İstanbul, Turkey

Submitted
25.03.2019

Accepted
01.07.2019

Available Online Date
27.08.2019

Correspondence
Ender Sırakaya,
Department of Ophthalmology,
Kayseri City Training and
Research Hospital, Şeker
Neighborhood, Molu Street,
Kocasinan, Kayseri, Turkey
Phone: +90 352 315 77 00
e-mail: esirakaya@gmail.com

©Copyright 2019 by Erciyes
University Faculty of Medicine -
Available online at
www.erciyesmedj.com

MATERIALS and METHODS

This prospective study was carried out in the Department of Ophthalmology at Kayseri City Hospital. The study was approved by the Regional Ethics Committee and it adhered to the tenets of the Declaration of Helsinki (Erciyes University 2019/92). Written and verbal informed consent was obtained from all the patients before enrollment. Power analysis was performed considering the earlier studies before starting the research, and 30 participants were considered to be sufficient. Only 40–80-year-old pseudophakic patients were included in this study. In this study, 35 eyes of 35 individuals who underwent YAG laser capsulotomy due to PCO were enrolled. All the eyes under consideration were subjected to Nd:YAG laser posterior capsulotomy, which was carried out in one session. All the patients underwent cataract surgery at least six months prior in Kayseri City Hospital without any complications, and all the participants had remarkable visual loss and visual symptoms (8/10 and lower visual acuity as per the Snellen chart, glare, and reduced contrast sensitivity). Patients were implanted with a single-piece hydrophobic acrylic intraocular lens (AcrySof SA60 IOL, Alcon, Fort Worth, TX, USA). The patients were evaluated one day (first visit), one week (second visit), and one month (third visit) after laser capsulotomy.

Exclusion Criteria

Patients with a history of any intraocular surgery—except for uneventful phacoemulsification, cornea pathology, ocular injury, glaucoma, uveitis, and contact lens use—were excluded from this study. Extraocular exclusion criteria included any history of systemic diseases, such as diabetes mellitus or connective tissue disease.

Examination Protocol and Measurements

Each participant received a complete ophthalmic evaluation that involved the best-corrected visual acuity with a Snellen chart, Goldmann applanation tonometry to measure the IOP, slit-lamp biomicroscopy examination, and dilated stereoscopic fundus examination; further, a Pentacam Scheimpflug camera was used to measure the anterior segment parameters. The objective refraction value was measured twice with an autorefractometry device (Topcon, RM-KR-8800, Tokyo, Japan) 40 min after 2.5% phenylephrine and 1% tropicamide eye drops. SE was calculated by adding the sphere power and half the cylinder power. The axial lengths for all the participants were measured before the YAG laser capsulotomy procedure with an optical biometer (IOLMaster 500; Carl Zeiss Meditec, Jena, Germany).

Operation Technique

Nd:YAG laser capsulotomy was performed with the Ultra Q Reflex laser device (Ellex, Australia) and a standard capsulotomy lens (Volk Optical Inc. Mentor, Ohio, USA). After pupil dilation, 4-mm-wide central capsulotomy was performed by focusing power at the posterior capsule level. The energy level began at 0.8 millijoules (mJ) and increased to 1.6 mJ and firing 33–72 shots, all of which were accomplished by the same ophthalmologist (ES). No antiglaucomatous application was made before or after the procedure. To prevent postoperative inflammation, the patients were prescribed 0.1/5.0 ml dexamethasone (Dexa-sine, Alcon, Hünenberg, Switzerland) 5 times daily and 0.3% nepafenac (Nevanac, Alcon,

Table 1. Clinical and demographic characteristics

Age (years)±SD	64.2±7.2 (42–76)
Gender, female, n (%)	16 (46%)
Side, right, n (%)	21 (60%)
Axial length (mm)	23.46±0.74 (21.82–24.76)
SD: Standard deviation	

Fort Worth, TX, USA) 4 times daily for a week. No intraoperative complications developed

Pentacam Scheimpflug Camera Measurements

A standard dim light was utilized for all the Pentacam measurements, which were carried out between 9 and 11 a.m. without pupil dilation to avoid any effects on the anterior segment parameters. In the present study, for the reconstruction of the anterior segment parameters, 25 Pentacam images obtained in the capture mode were utilized. After screening, a three-dimensional image of the anterior segment was constructed using the Pentacam software V.6.02r29. The AChD, AChV, AChA, CCoT, and Km measurements were undertaken. AChD was measured as the distance from the central cornea at the endothelial level to the IOL anterior surface without including the corneal thickness. AChA measurements denoted the angle between the cornea's posterior surface and the horizontal line of the anterior surface of the iris, wherein the narrower angle of either the nasal or temporal measurement was accepted. Km was automatically calculated by Pentacam from the circular area located 4.0 mm away from the cornea center. An average of the three measurements was taken and the best value was adopted for analysis, which was evaluated by the same ophthalmologist (AA). The tests were conducted on the first, second, and third visits after Nd:YAG laser capsulotomy.

Statistical Analyses

All the statistical analyses were carried out via the SPSS software for Windows v. 21.0 (IBM, Armonk, NY, USA). Categorical variables were evaluated by using the chi-squared test. Shapiro–Wilk's test was used for establishing the homogenous distribution of the variables, while continuous variables for descriptive statistics were stated as mean±standard deviation. The homogeneity of variance was evaluated by using Levene's test. Repeated-measures analysis of variance was performed to ascertain if the difference in the changes to the anterior segment parameters was statistically significant. Bonferroni adjustments were used as post hoc tests for multiple comparisons between the groups. Here, $p < 0.05$ was considered to be statistically significant.

RESULTS

The study sample consisted of 35 eyes of 35 individuals with PCO, whose mean age was 64.2±7.2 years. Here, 16 participants were female and 21 right eyes were included (Table 1). The IOP and SE values are listed in Table 2 and Table 3, respectively, while the Km values before and after performing the YAG capsulotomy procedure are listed in Table 4.

These findings reveal that an increase in the IOP value on the first

Table 2. Association of preoperative, first day, first week, and first month data with the IOP values

	IOP (mmHg)			
	Before laser	After laser 1 day	After laser 1 week	After laser 1 month
Mean (\pm SD)	14.5 \pm 1.9	16.1 \pm 2.4	15.2 \pm 1.8	14.7 \pm 1.8
Difference (mmHg)		+1.6	+0.7	+0.2
p-value*		<0.001 ^a	0.004 ^b	0.44 ^c

IOP: Intraocular pressure; SD: Standard deviation; *Repeated measures analysis of variance; Adjustment for multiple comparisons: Bonferroni test; a: Comparison of preoperative and first day; b: Comparison of preoperative and first week; c: Comparison of preoperative and first month

Table 3. Distribution of SE values over time

	SE (D)			
	Before laser	After laser 1 day	After laser 1 week	After laser 1 month
Mean (\pm SD)	-0.74 \pm 1.18	-0.31 \pm 0.78	-0.26 \pm 0.66	-0.25 \pm 0.66
Difference (D)		+0.43	+0.48	+0.49
p-value*		0.005 ^a	0.002 ^b	0.002 ^c

SE: Spherical equivalent; SD: Standard deviation; *Repeated measures analysis of variance; Adjustment for multiple comparisons: Bonferroni test; a: Comparison of preoperative and first day; b: Comparison of preoperative and first week; c: Comparison of preoperative and first month

Table 4. Association of preoperative, first day, first week, and first month data with the Km, AChV, AChA, and CCoT values

	Before laser	After laser, 1 day	After laser, 1 week	After laser, 1 month	*p
Km (D)	42.99 \pm 0.98	42.96 \pm 0.99	42.97 \pm 0.99	42.99 \pm 1.00	0.91
AChV (mm ³)	172.4 \pm 36.1	174.6 \pm 38.3	173.3 \pm 35.9	173.5 \pm 35.5	0.41
AChA (degree)	41.5 \pm 4.4	41.8 \pm 4.3	41.9 \pm 4.4	41.8 \pm 4.2	1.00
CCoT (μ m)	534.3 \pm 25.8	535.1 \pm 24.3	533.6 \pm 24.8	534.0 \pm 24.8	1.00

Km: Mean keratometry; AChV: Anterior chamber volume; AChA: Anterior chamber angle; CCoT: Central corneal thickness; SD: Standard deviation; *Repeated-measures analysis of variance. Comparison of preoperative and the three postoperative visits

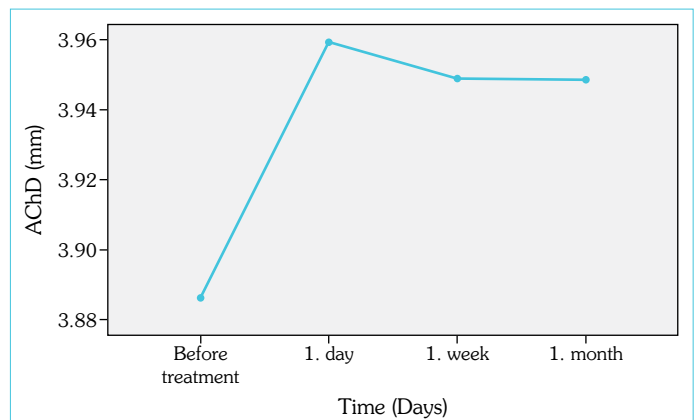
Table 5. Association of preoperative, first day, first week, and first month data with the AChD values

	AChD (mm)			
	Before laser	After laser 1 day	After laser 1 week	After laser 1 month
Mean (\pm SD)	3.89 \pm 0.53	3.96 \pm 0.59	3.95 \pm 0.60	3.95 \pm 0.59
Difference (mm)		+0.07	+0.06	+0.06
p-value*		0.038 ^a	0.037 ^b	0.022 ^c

AChD: Anterior chamber depth; SD: Standard deviation; *Repeated measures analysis of variance; Adjustment for multiple comparisons: Bonferroni test; a: Comparison of preoperative and first day; b: Comparison of preoperative and first week; c: Comparison of preoperative and first month

visit was statistically significant ($p < 0.001$). This trend continued into the second visit ($p = 0.004$). However, the difference in the IOP noted on the third visit was no longer significant ($p = 0.44$). In addition, the procedure resulted in a statistically significant decrease in SE ($p = 0.005$, $p = 0.002$, and $p = 0.002$). The hyperopic shift in SE began at the first visit. However, the SE measurements for the subsequent visits were not statistically significant ($p = 1.00$ and $p = 0.98$). Moreover, no significant differences in the Km values before and after the surgery were noted ($p = 0.91$).

AChD changes are listed in Table 5, whereas the repeated measurements and comparisons of AChV, AChA, and CCoT values are listed in Table 4. As compared to the preoperative values, there was a significant increment in AChD post-treatment ($p = 0.038$, $p = 0.037$, and $p = 0.022$). However, differences in the AChD

**Figure 1.** Repeated measurements of AChD before and after Nd:YAG laser treatment

measurements across the 3 visits were not statistically significant ($p = 1.00$). Figure 1 shows the AChD measurements before and after the capsulotomy procedure. The procedure did not yield statistically significant changes in AChV, AChA, and CCoT ($p = 0.41$, $p = 1.00$, and $p = 1.00$, respectively).

DISCUSSION

Cataract surgery is the most common procedure performed by ophthalmic surgeons. Despite considerable advancements in surgical techniques and IOL design, reduced visual acuity due to PCO is common after cataract surgery (3, 4). Nd:YAG laser treatment is the gold standard method for treating visual acuity loss associated with PCO. Studies have shown alteration in the morphology of the anterior seg-

ment caused by Nd:YAG laser capsulotomy with various techniques. The contactless Pentacam optical system is particularly designed for obtaining the image of the eye's anterior segment. It is easy to use and has been proven to be highly reliable and repeatable (11).

In the present study, there was a statistically significant increment in the IOP levels on the first and second visits, but none of the participants received any antiglaucomatous treatment. One month after capsulotomy, there was no significant difference in terms of IOP change. Ozkurt et al. found no significant increase in the IOP value hours or days after the procedure. However, these authors attributed this finding to the single drop of apraclonidine applied after the laser treatment (12). Hu et al. determined the IOP value 30 min and weeks after the surgery and did not find any significant increase as compared to the postoperative measurements. In the aforementioned study, a single drop of timolol or betaxolol was administered (13). Waseem et al. suggested that high-energy doses during YAG laser capsulotomy may cause increased IOP (14). Postoperative antiglaucomatous drops were not administered in our study. The mild increase in the IOP value may be attributed to the low cumulative dose of laser energy used in the procedure. In terms of refraction, a decrease in the SE value occurred in the participants. This hyperopic shift began during the first visit and continued throughout the second and third visits. Some studies found no significant change in the SE values (12, 13) or observed a hyperopic shift (15) following YAG laser capsulotomy. Karahan et al. observed 0.16–0.36 D hyperopic shift depending on the width of the YAG laser capsulotomy (16). The posterior movement of the IOL due to YAG capsulotomy might be responsible for the hyperopic shift. Similar to other studies, we found no statistically significant changes in the Km values (17, 18). This is most likely a result of the laser focal point being far from the cornea.

AChD increased in all the three visits after the laser procedure. This might be due to the movement of the IOL toward the vitreous. Similarly, Findl et al. reported that YAG laser capsulotomy caused an average posterior movement of 25 micron of the IOL, which caused an increase in the depth of the anterior chamber (19). Eliacik et al. reported posterior movement of 60 micron of the IOL and an increase of 0.06 ± 0.04 mm in AChD in their study, which was conducted with optic coherence tomography (AS-OCT) (20). However, studies have also reported no changes in AChD (13, 14) and a decrease in depth (19, 21). The research by Oztas et al. was performed by using a three-piece IOL (Sensar, AMO, USA); they found a decrease in AChD after capsulotomy (17). Our study was performed with a one-piece hydrophobic acrylic intraocular lens (AcrySof SA60 IOL, Alcon, Fort Worth, TX, USA). Different optic and haptic structures of the IOLs may explain these conflicting results in the anterior chamber parameters after YAG laser capsulotomy. Olsen et al. indicated that every 0.1 mm change in the AChD might cause a 0.1 D difference in the IOL calculation and noted the importance of a change in the anterior chamber depth with changes in refraction (22).

The present study found no significant differences in the AChV and AChA values. In a study conducted with Pentacam, Oztas et al. found a statistically significant increase in AChA one week after the operation, but no significant increase one month after the operation. This same study reported no significant difference in the AChV value (17). Eliacik et al. conducted a study with AS-OCT

and reported a 2.8%–2.9% increase in AChA (20). Changes in AChV and AChA may be caused by changes in the iris plane. Further studies evaluating the iris plane may help shed light on this subject. After capsulotomy, there was no obvious change in CCoT. This showed that the YAG laser operation had no effect on the corneal thickness. Further studies with advanced evaluation of corneal endothelium and other corneal layers may provide more detailed information.

The relatively small sample size and the follow-up period of only one month were the limitations of our study. In addition, further studies evaluating various IOL types, posterior capsule opacity density, and effect of capsulotomy width are necessary.

CONCLUSION

PCO, which commonly develops following cataract surgery, can be successfully treated with YAG laser capsulotomy. Following Nd:YAG posterior capsulotomy, we found statistically significant changes in the AChD, IOP, and SE values. YAG laser capsulotomy is a significant procedure, which may cause changes in the IOL position, leading to increased AChD and refractive changes. The changes that may develop after the procedure should be considered.

Ethics Committee Approval: This prospective study was approved by the local ethics committee (Ethics committee decision: Erciyes University 2019/92).

Informed Consent: Written informed consent was obtained from the patients who participated in this study.

Peer-review: Externally peer-reviewed.

Author Contributions: Designed the study: ES. Collected the data: ES, AA, BK, MH. Analyzed the data: ES, AA. Wrote the paper: ES, AA, BK, MH. All authors have read and approved the final manuscript.

Conflict of Interest: The authors have no conflict of interest to declare.

Financial Disclosure: The authors declared that this study has received no financial support.

Data Availability: The data used to support the findings of this study are available from the corresponding author upon request.

REFERENCES

1. Smith RT, Moscoso WE, Trokel S, Auran J. The Barrier Function in Neodymium-YAG Laser Capsulotomy. *Arch Ophthalmol* 1995; 113(5): 645–52. [\[CrossRef\]](#)
2. Wormstone IM, Wang L, Liu CS. Posterior capsule opacification. *Exp Eye Res* 2009; 88(2): 257–69. [\[CrossRef\]](#)
3. McDonnell PJ, Zarbin MA, Green WR. Posterior capsule opacification in pseudophakic eyes. *Ophthalmology* 1983; 90(12): 1548–53. [\[CrossRef\]](#)
4. Lindholm J-M, Laine I, Tuuminen R. Five-Year Cumulative Incidence and Risk Factors of Nd: YAG Capsulotomy in 10 044 Hydrophobic Acrylic 1-Piece and 3-Piece Intraocular Lenses. *Am J Ophthalmol* 2019; 200:218–23. [\[CrossRef\]](#)
5. Lu C, Yu S, Song H, Zhao Y, Xie S, Tang X, et al. Posterior capsular opacification comparison between morphology and objective visual function. *BMC Ophthalmol* 2019; 19: 40. [\[CrossRef\]](#)
6. Aron-Rosa D, Aron JJ, Griesemann M, Thyzel R. Use of the neodymium-YAG laser to open the posterior capsule after lens implant surgery:

- a preliminary report. *J Am Intraocul Implant Soc* 1980;6(4):352–4.
7. Whitman J. Differentiating retinal tear and detachment rate by axial length to identify at-risk patients having neodymium: YAG capsulotomy. *J Cataract Refract Surg* 2017; 43(12): 1618. [\[CrossRef\]](#)
 8. Shetty NK, Sridhar S. Study of Variation in Intraocular Pressure Spike (IOP) Following Nd-YAG Laser Capsulotomy. *J Clin Diagn Res* 2016; 10(12): NC09–NC12. [\[CrossRef\]](#)
 9. Wesolosky JD, Tennant M, Rudnisky CJ. Rate of retinal tear and detachment after neodymium:YAG capsulotomy. *J Cataract Refract Surg* 2017; 43(7): 923–8. [\[CrossRef\]](#)
 10. Grzybowski A, Kanclerz P. Does Nd:YAG Capsulotomy Increase the Risk of Retinal Detachment? *Asia Pac J Ophthalmol* 2018; 7(5): 339–44.
 11. Barkana Y, Gerber Y, Elbaz U, Schwartz S, Ken-Dror G, Avni I, et al. Central corneal thickness measurement with the Pentacam Scheimpflug system, optical low-coherence reflectometry pachymeter, and ultrasound pachymetry. *J Cataract Refract Surg* 2005; 31(9): 1729–35. [\[CrossRef\]](#)
 12. Ozkurt YB, Sengör T, Evciman T, Haboğlu M. Refraction, intraocular pressure and anterior chamber depth changes after Nd:YAG laser treatment for posterior capsular opacification in pseudophakic eyes. *Clin Exp Optom* 2009; 92(5): 412–5. [\[CrossRef\]](#)
 13. Hu CY, Woung LC, Wang MC, Jian JH. Influence of laser posterior capsulotomy on anterior chamber depth, refraction, and intraocular pressure. *J Cataract Refract Surg* 2000; 26(8): 1183–9. [\[CrossRef\]](#)
 14. Waseem M, Khan HA. Association of raised intraocular pressure and its correlation to the energy used with raised versus normal intraocular pressure following Nd: YAG laser posterior capsulotomy in pseudophakes. *J Coll Physicians Surg Pak* 2010; 20(8): 524–7.
 15. Zaidi M, Askari SN. Effect of Nd: YAG laser posterior capsulotomy on anterior chamber depth, intraocular pressure, and refractive status. *Asian J Ophthalmol* 2003; 5(4):2–5.
 16. Karahan E, Tuncer I, Zengin MO. The Effect of ND: YAG Laser Posterior Capsulotomy Size on Refraction, Intraocular Pressure, and Macular Thickness. *J Ophthalmol* 2014; 2014: 1–5. [\[CrossRef\]](#)
 17. Oztas Z, Palamar M, Afrashi F, Yagci A. The effects of Nd: YAG laser capsulotomy on anterior segment parameters in patients with posterior capsular opacification. *Clin Exp Optom* 2015; 98(2): 168–71. [\[CrossRef\]](#)
 18. Khambhiphant B, Liumsirijarern C, Saehout P. The effect of Nd: YAG laser treatment of posterior capsule opacification on anterior chamber depth and refraction in pseudophakic eyes. *Clin Ophthalmol* 2015; 9: 557–61. [\[CrossRef\]](#)
 19. Findl O, Drexler W, Menapace R, Georgopoulos M, Rainer G, Hitzinger CK, et al. Changes in intraocular lens position after neodymium: YAG capsulotomy. *J Cataract Refract Surg* 1999; 25(5): 659–62.
 20. Eliaçık M, Bayramlar H, Erdur SK, Demirci G, Güllük G. Anterior segment optical coherence tomography measurement after neodymium-yttrium-aluminum-garnet laser capsulotomy. *Am J Ophthalmol* 2014; 158(5): 994–8. [\[CrossRef\]](#)
 21. Shin MH, Kang HJ, Kim SJ, Chung IY, Seo SW, Yoo JM, et al. Effect of Nd: YAG Laser Capsulotomy on Anterior Segment Parameters in Patients with Posterior Capsular Opacification after Phacovitrectomy. *Korean J Ophthalmol* 2018; 32(5): 369–75. [\[CrossRef\]](#)
 22. Olsen T, Corydon L, Gimbel H. Intraocular lens power calculation with an improved anterior chamber depth prediction algorithm. *J Cataract Refract Surg* 1995; 21(3): 313–9. [\[CrossRef\]](#)