



Arthritis in Hand Joints due to Acitretin: A Rare Case Report

Selami Aykut Temiz¹ , Recep Dursun² 

ABSTRACT

Background: Lichen planus is a skin disease that may last for years, mainly affecting the skin surface and mucous membranes (such as the oral and genital mucosa), and more rarely, on the nails and hairs. Systemic acitretin is an effective therapeutic agent used in the treatment of lichen planus. The skeletal toxicity of retinoids is controversial. Because skeletal toxicity cannot be demonstrated with acitretin, radiological monitoring is not recommended.

Case Report: A 24-year-old male patient was admitted to our dermatology outpatient clinic with hand metacarpophalangeal, proximal interphalangeal joint swelling, and pain, who was in the third month of systemic acitretin treatment for oral lichen planus. In our case, another cause of etiologic could not be detected, and arthritis due to acitretin was considered.

Conclusion: As a result, it should not be forgotten that acute arthritis may rarely occur during the use of acitretin and should not be overlooked by the clinician.

Keywords: Lichen planus, acitretin, acute arthritis

INTRODUCTION

Lichen planus is an inflammatory mucocutaneous dermatosis seen in approximately 1% (1). Mucosal involvement of the lichen planus has special importance since it carries a risk of malignancy (2). Acitretin is an effective therapeutic agent used in the treatment of lichen planus (3).

The skeletal toxicity of retinoids is controversial. However, in patients with Hypervitaminosis A, plain radiography changes that have resulted in arthralgia and bone pain and resembling skeletal hyperostosis have been described (4). Again, cases of arthritis due to isotretinoin from retinoids have been identified (5).

In the literature, although arthritis cases related to retinoids have been reported, to our knowledge, there have been no cases of hand joint arthritis. Herein, we present a 24-year-old male patient who developed arthritis in his bilateral hand joints while receiving acitretin therapy.

CASE REPORT

A 24-year-old male patient was admitted to our dermatology outpatient polyclinic with hand metacarpophalangeal (MCP) proximal interphalangeal (PIP) joint swelling (Fig. 1), and pain in the third month of systemic isotretinoin treatment for oral lichen planus (Fig. 2). Myalgia, other joints of arthralgia and inflammatory back pain were not described by the patient.

At the time of admission, our patient had been receiving 35 mg/day acitretin for three months for oral lichen planus treatment. Our patient had complaints of swelling and pain in his hand joints in the third month of treatment, and we learned that his complaints had been present for approximately one month. There was no drug use other than acitretin. Respiratory, urogenital, and gastrointestinal infections were not detected. The physical examination revealed tenderness with palpations in both hand joints and PIP joints.

His medical history had no additional features other than oral lichen planus. The case was referred to the Rheumatology outpatient clinic with preliminary diagnoses of rheumatoid arthritis and drug-induced arthritis. In the MRI (magnetic resonance imaging) examination, synovial hypertrophy, and effusion were present in the hand MRI (Fig. 3).

In the laboratory observations performed: Aspartate Aminotransferase (AST): 33 U/L, Alanine Aminotransferase (ALT): 21 U/L, Creatinine (Cre): 0.72 mg/dL, Rheumatoid factor (RF): 11.5 IU/ml, Anti-cyclic citrullinated peptide

Cite this article as:
Temiz SA, Dursun R.
Arthritis in Hand Joints
due to Acitretin: A Rare
Case Report. Erciyes Med J
2020; 42(3): 343-5.

¹Department of Dermatology,
Konya Ereğli State Hospital,
Konya, Turkey

²Department of Dermatology,
Necmettin Erbakan University
Meram Faculty of Medicine,
Konya, Turkey

Submitted
22.03.2020

Accepted
20.04.2020

Available Online Date
16.06.2020

Correspondence
Selami Aykut Temiz,
Konya Ereğli State Hospital,
Department of Dermatology,
Konya, Turkey
Phone: +90 332 223 62 04
e-mail: aykutmd42@gmail.com

©Copyright 2020 by Erciyes
University Faculty of Medicine -
Available online at
www.erciyesmedj.com

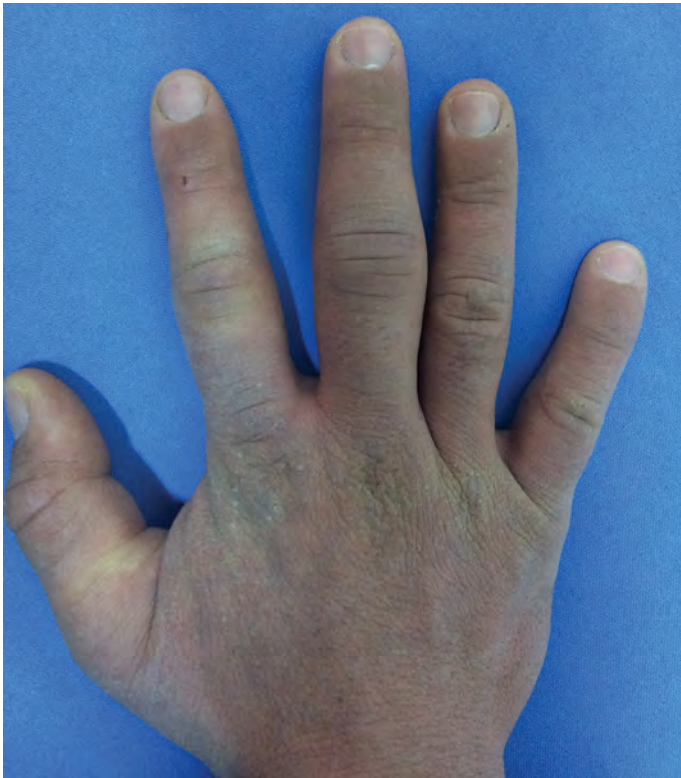

Figure 1. Metacarpophalangeal (MCP) and Proximal interphalangeal (PIP) joint swelling

(A.CCP): <0.5 U/mL, C-reactive protein (Crp): 4.3 mg/L, Anti-nuclear antibody (ANA): negative. In our case, rheumatoid arthritis and other rheumatological diseases were not detected. No other etiologic cause could be detected, so arthritis due to acitretin was considered, and treatment was discontinued. Naproxen sodium 750 mg/day and 16 mg systemic prednisolone were started. The systemic prednisolone was reduced and discontinued within one month. The patient's complaints ceased almost completely within 2–3 months. The case's follow-up continues. Informed consent was obtained from the patient for the publication of this case report and images.

DISCUSSION

Isotretinoin, etretinate, and acitretin are known as retinoids and are synthetic vitamin A analogs. They are mainly used in dermatological diseases with psoriasis, acne and other keratinization disorders (6). Rheumatological symptoms, such as seronegative spondyloarthropathy, common idiopathic skeletal hyperostosis, arthritis, and myopathy, may occur during retinoid use (4). Many cases of arthritis were reported with isotretinoin, one of the retinoids (5, 7); however, it is very rare with acitretin.

Mucocutaneous side effects are the most common group of side effects during retinoid use, among which cheilitis is the most common finding, and is present in approximately 100% of patients (8). Most of these side effects can be tolerated, and they are predominantly dependent on the dose. Side effects are usually regressed by stopping retinoid therapy. Approximately 15% of the cases have myalgia and joint pain (7). Acute arthritis pattern is uncommon, mostly mono or oligoarthritic. Knee joint involvement is the most common, but recently, sacroiliac joint involvement has increased (7). Interest-

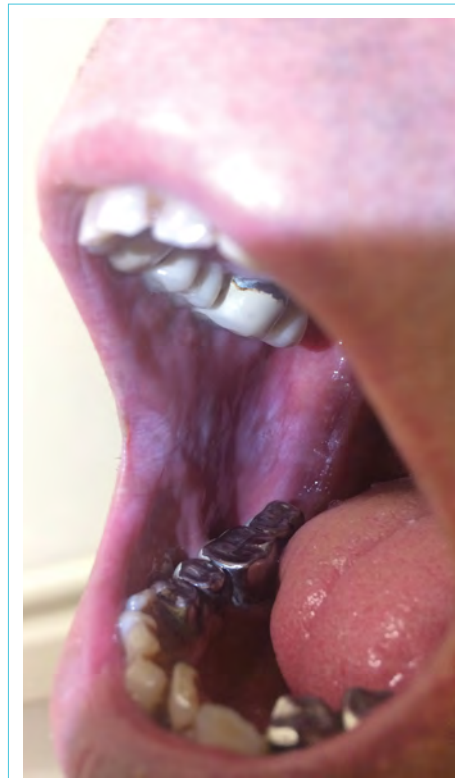


Figure 2. Lichen planus plaque with the reticular pattern on the right buccal mucosa

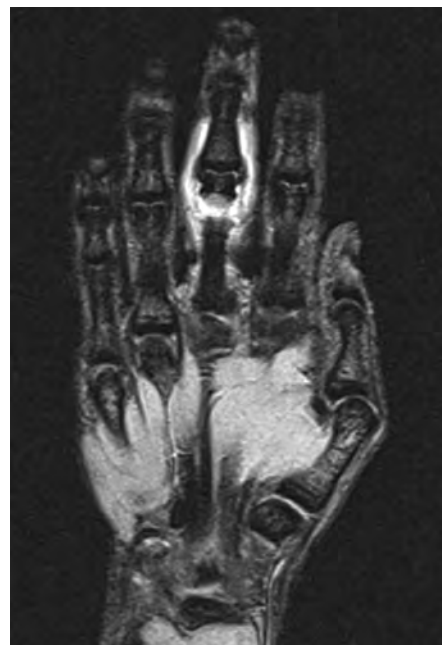

Figure 3. Synovial hypertrophy and effusion were present in the hand MRI

ingly, in our case, arthritis was only present in the hand joints.

The mechanisms of retinoid-induced arthritis have yet to be explained, and there are different hypotheses. The first hypothesis is that retinoid increases matrix metalloproteinase-2, which leads to damage to the basal membrane type 4 collagen (9). The other hypothesis suggested that retinoid may cause solubilization of the liposomal membrane, and last of all, cytopathic destruction of the synovium, causing arthritis as a side effect (9).

It has been reported that arthritis over a short period of time can be self-limited or controlled by nonsteroidal anti-inflammatory (NSAID) drugs (9). However, some cases have been reported that persist for years (9). In our case, bilateral hand MCP and PIP joints were affected and had a dramatic response to drug removal.

Baykal et al. (5) found symptoms of lower back pain in a study of sacroiliitis prevalence during oral isotretinoin use observed within 2–3 months after treatment initiation. In our case, it was approximately three months after the administration of the acitretin symptoms began. Based on the chronology of events and the absence of additional conditions, in the described case, the arthritis was associated with the acitretin.

CONCLUSION

As a result, it should not be forgotten that acute arthritis may rarely occur during the use of retinoids and should not be overlooked by the clinician.

Informed Consent: Written informed consent was obtained from patients who participated in this study.

Peer-review: Externally peer-reviewed.

Author Contributions: Concept – SAT, RD; Design – SAT, RD; Supervision – SAT, RD; Resource – SAT, RD; Materials – SAT, RD; Data Collection and/or Processing – SAT, RD; Analysis and/or Interpretation – SAT, RD; Literature Search – SAT, RD; Writing – SAT, RD; Critical Reviews – SAT, RD.

Conflict of Interest: The authors have no conflict of interest to declare.

Financial Disclosure: The authors declared that this study has received no financial support.

REFERENCES

1. Schwager Z, Stern M, Cohen J, Femia A. Clinical epidemiology and treatment of lichen planus: A retrospective review of 2 tertiary care centers. *J Am Acad Dermatol* 2019; 81(6): 1397–9. [[CrossRef](#)]
2. Giuliani M, Troiano G, Cordaro M, Corsalini M, Gioco G, Lo Muzio L, et al. Rate of malignant transformation of oral lichen planus: A systematic review. *Oral Dis* 2019; 25(3): 693–709. [[CrossRef](#)]
3. Husein-ElAhmed H, Gieler U, Steinhoff M. Lichen planus: a comprehensive evidence-based analysis of medical treatment. *J Euro Aca Derma Venereology* 2019; 33(10): 1847–62. [[CrossRef](#)]
4. Neshet G, Zuckner J. Rheumatologic complications of vitamin A and retinoids. *Semin Arthritis Rheum* 1995; 24(4): 291–6. [[CrossRef](#)]
5. Baykal Selçuk L, Aksu Arıca D, Baykal Şahin H, Yaylı S, Bahadır S. The prevalence of sacroiliitis in patients with acne vulgaris using isotretinoin. *Cutan Ocul Toxicol* 2017; 36(2): 176–9. [[CrossRef](#)]
6. Sarkar R, Chugh S, Garg VK. Acitretin in dermatology. *Indian J Dermatol Venereol Leprol* 2013; 79(6): 759–71. [[CrossRef](#)]
7. McLane J. Analysis of common side effects of isotretinoin. *J Am Acad Dermatol* 2001; 45(5): S188–94. [[CrossRef](#)]
8. Katz HI, Waalen J, Leach EE. Acitretin in psoriasis: an overview of adverse effects. *J Am Acad Dermatol* 1999; 41(3 Pt 2): S7–12. [[CrossRef](#)]
9. Alkan S, Kayiran N, Zengin O, Kalem A, Kimyon G, Kilinc EO, et al. Isotretinoin-induced Spondyloarthritis-related Symptoms: A Prospective Study. *J Rheumatol* 2015; 42(11): 2106–9. [[CrossRef](#)]