








The Pharmacokinetics of F-18 Fluorocholine in Detecting Breast Cancer Patients

Shaharuddin Shazreen¹ , Hassan Hishar² , Abdullah Suhaimi Shahrin Niza³ , Mustapha Farida Aimi⁴ , Ahmad Saad Fathinul Fikri⁵ 

ABSTRACT

Objective: The abnormal expression of choline (Cho) metabolism is one of the factors that may contribute to the development of breast cancer. Earlier studies proved that Cho uptakes are varied among the different subtypes of breast cancer. Apart from the ubiquitous 18F-Fluorodeoxyglucose (18F-FDG), the F-18 Fluorocholine (F-18 FCH) has also been proved to be one of the oncologic markers for PET imaging modality. However, it is never been tested on breast cancer patient. Therefore, this study aims to evaluate the distribution of F-18 FCH in breast cancer patient.

Materials and Methods: The biodistribution of 18F-FCH was obtained at two different time points; six minutes and 30 minutes after administration 18F-FCH. The biodistribution data were collected within the first-hour post-injection from the attenuation-correction of whole-body PET scans. The estimation of radiation dosimetry was then calculated using human biodistribution data assuming no redistribution of tracer after one hour.

Results: The F-18 FCH uptake on the malignant tissues was distinguished compared to the uptake in surrounding normal tissue, but much lower than in the liver as the time increases. The 18F-FCH showed a significant difference with high uptake in malignant breast cancer as compared to benign breast cancer with 18F-FCH uptake of $(1.66 \pm 0.26$ vs. 0.56 ± 0.14 ($p=0.007$)).

Conclusion: Although F-18 FCH was never tested on breast cancer patient on PET imaging, the results showed higher SUVmax uptake in the malignant breast tissue as the time increases.

Keywords: Breast cancer imaging, positron emission tomography, F-18 Fluorocholine.

Cite this article as:
Shazreen S, Hishar H, Niza ASS, Aimi MF, Fikri ASF. The Pharmacokinetics of F-18 Fluorocholine in Detecting Breast Cancer Patients. Erciyas Med J 2020; 42(4): 447-51.

¹Department of Physiology, National Defence University of Malaysia Faculty of Medicine and Defence Health, Kuala Lumpur, Malaysia

²Centre for Diagnostic and Nuclear Imaging, University Putra Malaysia, Malaysia

³Department of Surgical, University Kebangsaan Faculty of Medicine, Malaysia

⁴Department of Imaging, University Technology Mara, Malaysia

⁵Department of Imaging, University Putra Malaysia, Faculty of Medicine and Health Sciences, Malaysia

Submitted
27.11.2019

Accepted
30.06.2020

Available Online Date
20.10.2020

Correspondence
Shaharuddin Shazreen,
Department of Physiology,
National Defence University of
Malaysia Faculty of Medicine
and Defence Health, Kuala
Lumpur, Malaysia
Phone: +603-9051 3028
e-mail: fir_reen@yahoo.com

©Copyright 2020 by Erciyas
University Faculty of Medicine -
Available online at
www.erciyesmedj.com

INTRODUCTION

As the number of patients with breast cancer has significantly increased over the year, studies have reported that a strong and accurate diagnostic was needed to detect breast cancer patients (1–3). There are very limited numbers of studies around the globe using F-18 FCH for breast cancer diagnosis in PET imaging (4, 5). The level of choline and phosphorylcholine are found tremendously increased in a variety of tumor cells, which represents the activation of choline uptake and phosphorylation in tumor cells (6–9). Recent studies reported that overexpression of choline metabolism is found in the epithelial of aggressiveness breast tissue (10, 11). The overexpression of choline levels in malignant cells can be an important indicator in detecting breast cancer. Specific cancer cases, such as the brain, neuroendocrine, or prostate, demonstrated that the use of F-18 FDG was pointless in PET/CT technique due to cancer cell behavior (12, 13). Therefore, using F-18 FCH could be a surrogate marker in detecting the phosphorylation in cancerous breast cells.

The C-11 choline was developed for PET/CT imaging and extensively been used to detect the aggressiveness of cancer. However, the short half-life of only 20 minutes limits the clinical applicability of 11C-choline in centers without an onsite cyclotron (14, 15). Therefore, the new ligand was developed, which is Fluorine-18 with a relatively long half-life of 110 minutes (16). As a consequence, the 18F-FCH was developed and successfully made a debut in the diagnosis of prostate ca and other cancer by enables the distribution of the 18F-FCH uptake, making it suitable to use as diagnostic imaging.

The highest intensity of F-18 FCH uptake was shown in the liver, pancreas, kidney, and bladder. This is due to an accumulation of tracer in the body (17, 18). There was a moderate-to-high intense of F-18 FCH uptake observed in the spleen and lachrymal glands. However, the F-18 FCH uptake was shown less intense in the bone marrow, small intestine, and large intestine. Meanwhile, the F-18 FCH uptake in the brain was usually negligible, except in the choroid plexus and pineal gland, which could occasionally be visualized in PET imaging (19, 20).

To our knowledge, there is not any study that was performed using F-18 FCH in detecting breast cancer. Thus, this study aims to evaluate the distribution of F-18 FCH in detecting the uptake of the lesion in breast cancer patients according to the selection of breast regions.

MATERIALS and METHODS

This study was conducted prospectively using simple random sampling, 21 breast cancer patients were selected from the Endocrinology Clinic, PPUKM with BIRADS 4 or 5 from the mammogram results, histopathology has proven breast mass and recurrent breast cancer. All patients underwent 18F-Fluorocholine PET/CT whole-body; after a week, following a successful of 18F-FCH examination, an MRI spectroscopy examination was performed at the Centre for Diagnostic Nuclear Imaging (PPDN), University Putra Malaysia. Demographic data and biopsy were obtained from the medical record patients at the Endocrinology Clinic, PPUKM. Written informed consent provided to all who participated in this study and were informed of all risks associated with this study. This study was obtained its approval from the Ethics Committee of UPM, and it was supported by the Research University Grant Scheme (RUGS- 6), UPM, and Fundamental Research Grant Scheme (FRGS) from the Ministry of Higher Education, Malaysia.

Production of F-18 FCH

The synthesis of 18F-FCH was prepared in a commercial synthesis module, SCINTOMICS GRP 4V module, using the N-alkylation of dimethylethanolamine (DMEA) with 18F-fluorobromomethane ([18F] BrCH₂F). The production of F-18 FCH was prepared at the Centre for Diagnostic Nuclear Imaging, UPM according to Hassan et al., 2016 (21) protocols. Before patient administration, the 18F-FCH was analyzed for its quality. The appearance, pH, radiochemical purity, residual solvents analysis, sterility test and bacterial endotoxin test of 18F-FCH was thoroughly checked to ensure it complies with all the release criteria and safe for patient administration.

Patient's Preparation for F-18 FCH PET

Once the patient arrived at the center, the intravenous line was inserted to the patients to administered prepared before intravenous injection of F-18 FCH. The F-18 FCH dose administered was 0.11 mCi/kg or 5 MBq/kg following the patient's body weight. In contrast to the F-18 FDG PET protocol, the patients were not required to fast. The imaging protocol started with the dynamic imaging after six minutes of post-injection to observe the dynamic flow of the choline marker in the body and followed by a whole-body imaging protocol for 60 minutes (Fig. 1).

Image Acquisition

Imaging Protocol

All patients' images were acquired using an advanced integrated PET-CT system (Siemens Biograph-64, Germany). The spatial resolution was set at approximately 3 mm in all directions. The dynamic imaging was acquired to include the liver, spleen, and both breasts at one minute per bed position for six consecutive phases of PET acquisition. The delayed scan covered from thorax to abdomen (1-bed position x 3 min per bed position) were acquired after the dynamic phase, which began at approximately six to ten minutes after the administration of F-18 FCH with 15.5 cm field of view and 4.2 mm full width at half maximum spatial resolution in the center field of view (Fig. 1).

Image Reconstruction

From the sequentially 3-D PET image, the lesion at breast, normal

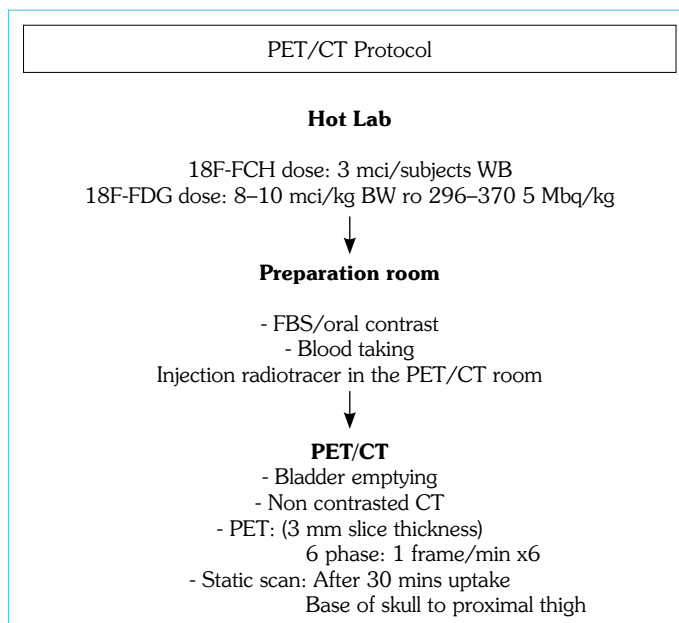


Figure 1. Patients preparation and PET/CT scan protocol

Table 1. The difference means of breast lesion, normal breast and liver in malignant and benign breast cancer

Variables	Group	
	Malignant	Benign
Breast lesion (g/dl)	1.66±0.26	0.56±0.14
Normal breast (g/dl)	0.24±0.18	0.08±0.17
Liver (g/dl)	17.3±0.52	17.1±0.58
P-value (independent t-test)	0.007	0.063

breast tissue, and liver were selected by manually drawing the selected region of interest (ROI) at 10 mm² in each frame of image acquisition. From the ROI drawn, the maximum value of F-18 FCH concentration within organs was recorded for each frame.

Statistical Analysis

The time activity curve (TAC) describes the concentration of the standardized uptake value (SUV_{max}, g/dl) of 18F-FCH in organs at different time points. Table 1 shows the difference between malignant and benign lesion based on the values of 18F-FCH concentrations in the liver, lesion breast and normal breast tissue using an independent t-test. All statistical tests with P-values <0.05 were considered statistically significant.

RESULTS

The tabulation means of benign and malignant for breast lesion, normal breast tissue, and liver is presented according to benign breast lesion and malignant breast lesion.

There is a significant difference between malignant and benign [1.66±0.26 vs. 0.56±0.14 (p=0.007)] with high uptake of 18F-FCH in breast lesion (1.66±0.26 vs. 0.56±0.14), normal breast (0.24±0.18 vs. 0.08±0.17) and liver (17.3±0.52 vs. 17.1±0.58) in malignant as compared to benign.




Figure 2. (a) Image of SUVmax value of FCH dynamic(below) and 18FDG images were used to verified the location of the lesion, normal breast tissue and liver in malignant breast cancer patients. (b) Image of 18F-FCH at 1 minutes in liver with SUVmax: 10.54 g/dl. (c) Image of 18F-FCH at 1 minutes in lesion breast with SUVmax 1.19 g/dl and normal tissue breast with SUVmax: 0.67 g/dl

DISCUSSION

The statistical analysis in Table 1 shows that there was a significant difference between malignant and benign breast cancer with malignant breast cancer showed high F-18 FCH uptake, which was 1.66 ± 0.26 g/dl compared to benign, 0.56 ± 0.14 g/dl. It has been shown that the biodistribution of the affected breast region for benign breast lesion has lower choline concentration in the background as compared to the background activity of the malignant breast. The lack of tissue clearance with F-18 FCH administration may reflect specific metabolic trapping of the tracer through phosphorylation and further incorporation of the radiolabel into phospholipids, as recently shown in cultured prostate cancer cells (22–24), which provides the impression of the choline activation pathway is more remarkable when there is a cellular stressor of a malignant cellular reprogramming.

In our study, we found that malignant breast cancer showed high 18F-FCH uptake in breast lesion and liver (1.66 ± 0.26 , 17.3 ± 0.52) as compared to benign breast cancer (0.56 ± 0.14 , 17.1 ± 0.58). A recent study showed that there are significant interactions between the metabolic of choline and oncogenic pathways (25). The most significant development of oncogenic signaling could be due to the metabolic reprogramming of choline. It is believed that the high glucose and choline concentration is sufficient to trigger the activation of oncogenic pathways and induce a malignant-like phenotype in mammary epithelial cells (26). The choline concentration varies in various organs, and in particular, its concentration in the liver and spleen with elimination using kidneys. The variation of the F-18 FCH tracer uptake could be due to inflammatory effects and physiological changes or oncogenic processes.

As shown in Figure 2 and Figure 3, the F-18 FCH uptake on the malignant tissues was distinguished compared to the uptake in surrounding normal tissue, but much lower than in the liver. The average SUV on the liver was found to be 10 times higher than in malignant tissues. This is consistent with the study led by which observed the concentration of F-18 radioactivity in the liver increased rapidly in the first 10 minutes, but then increased slowly thereafter (26, 27).

Table 2, shows the comparison of F-18 FCH uptake in breast lesions (malignant) and liver in our study as compared with a recent

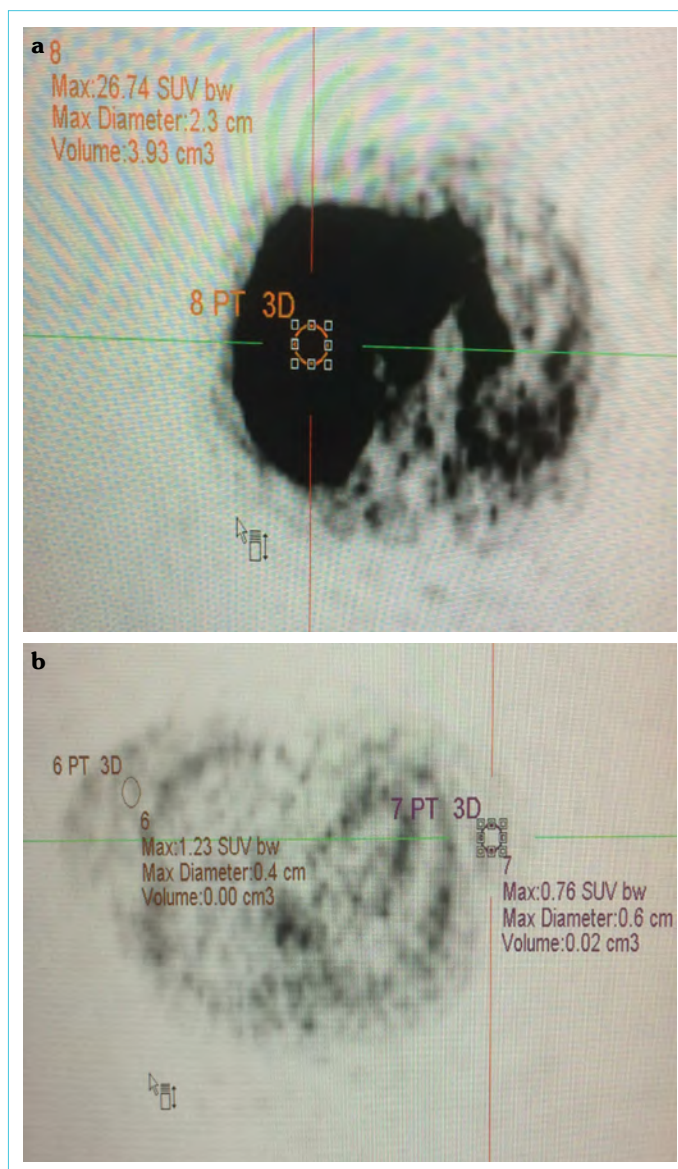


Figure 3. (a) Image of 18F-FCH at 5 minutes in liver with SUVmax: 26.74 g/dl. (b) Image of 18F-FCH at 5 minutes in lesion breast with SUVmax 1.23 g/dl and normal tissue breast with SUVmax: 0.76 g/dl

Table 2. The pharmacokinetic of breast lesion and liver

Organs	Ferdinando et al. (g/dl)	Timothy et al. (g/dl)	Our studies (g/dl)
Liver	12.8±5.5	13.5±4.69	17.3±0.52
Breast	0.8±0.5	0.91±0.37	1.66±0.26

study. Our study reveals that the recurrent breast cancer or metastasis demonstrated a broad range of SUV values in breast lesions, which raises the possibility that the F-18 FCH uptake is reflecting some phenotype of cancer (28). We found that the SUV_{max} value is low in metastasis or recurrent breast cancer with a high F-18 FCH uptake. Therefore, the clinical-translational studies involving tissue genomics or metabolomics could help to ascertain the molecular basis for these variations in tumoral and breast F18 FCH uptake. These results were also provenance by other researchers that found there is low SUV_{max} with 0.91±0.37 in a patient with malignant breast cancer (29). While other studies found that the F-18 FCH uptake with low SUV_{max} value in the breast region, with a mean SUV_{max} of 0.8 (range 0.4–1.1) (30).

CONCLUSION

The biodistribution of F-18 FCH showed higher uptake in malignant breast cancer as the time increasing as compared to benign breast cancer. Therefore, F-18 FCH dynamic imaging protocol can be used to guide future clinical trials in patients with breast cancer to further evaluate the effects of imaging time and other parameters on cancer cell detection, response to therapy, and outcome measure.

Ethics Committee Approval: This study was obtained its approval from the Ethic Committee of UPM date: 21st November 2014, number: JKE-UPM/F2.

Informed Consent: Written informed consent was obtained from patients who participated in this study.

Peer-review: Externally peer-reviewed.

Author Contributions: Concept – SS; Design – MFA; Supervision – SS; Resource – ASFF; Materials – ASSN; Data Collection and/or Processing – ASSN, HH; Analysis and/or Interpretation – ASFF; Literature Search – MFA; Writing – SS; Critical Reviews – HH.

Conflict of Interest: The authors have no conflict of interest to declare.

Financial Disclosure: This work was supported by the Fundamental Research Grant Scheme (FRGS) from the Ministry of Higher Education, Malaysia (28612-61021).

REFERENCES

- Baenke F, Peck B, Miess H, Schulze A. Hooked on fat: the role of lipid synthesis in cancer metabolism and tumour development. *Dis Model Mech* 2013; 6(6): 1353–63. [\[CrossRef\]](#)
- Li B, Lu Y, Wang L, Zhang CX. Folate intake and breast cancer prognosis: a meta-analysis of prospective observational studies. *Eur J Cancer Prev* 2015; 24(2): 113–21. [\[CrossRef\]](#)
- Hugentobler A, Gilbeau L, Talbot JN, Gauthé M. 18F-Fluorocholine PET/CT of Incidental Male Breast Cancer. *Clin Nucl Med* 2017; 42(1): 56–7. [\[CrossRef\]](#)
- Contractor K, Challapalli A, Barwick T, Winkler M, Hellowell G, Hazell S, et al. Use of [11C]choline PET-CT as a noninvasive method for detecting pelvic lymph node status from prostate cancer and relationship with choline kinase expression. *Clin Cancer Res* 2011; 17(24): 7673–83. [\[CrossRef\]](#)
- Contractor KB, Kenny LM, Stebbing J, Al-Nahhas A, Palmieri C, Sinnett D, et al. [11C]choline positron emission tomography in estrogen receptor-positive breast cancer. *Clin Cancer Res* 2009; 15(17): 5503–10.
- Corrigan AJ, Schleyer PJ, Cook GJ. Pitfalls and Artifacts in the Use of PET/CT in Oncology Imaging. *Semin Nucl Med* 2015; 45(6): 481–99.
- Damita T, Marc C, John L, Sandi K. Pilot study of 18F-fluorocholine uptake in normal and malignant breast tissue. *J Nuclear Med* 2011; 52(suppl 1): 249.
- Dorrius MD, de Vries EF, Slart RH, Glaudemans AW. Breast cancer: a new imaging approach as an addition to existing guidelines. *Eur J Nucl Med Mol Imaging* 2015; 42(6): 813–7. [\[CrossRef\]](#)
- Elimova E, Wang X, Etchebehere E, Shiozaki H, Shimodaira Y, Wadhwa R, et al. 18-fluorodeoxy-glucose positron emission computed tomography as predictive of response after chemoradiation in oesophageal cancer patients. *Eur J Cancer* 2015; 51(17): 2545–52. [\[CrossRef\]](#)
- Giordano SH, Temin S, Chandarlapaty S, Crews JR, Esteva FJ, Kirshner JJ, et al. Systemic Therapy for Patients With Advanced Human Epidermal Growth Factor Receptor 2-Positive Breast Cancer: ASCO Clinical Practice Guideline Update. *J Clin Oncol* 2018; 36(26): 2736–40.
- Glunde K, Bhujwala ZM, Ronen SM. Choline metabolism in malignant transformation. *Nat Rev Cancer* 2011; 11(12): 835–48. [\[CrossRef\]](#)
- Sandi K, Caroline J, John L, Marc C. Effect of docetaxel on metastatic tumor 18F-fluorocholine uptake in patients with hormone-refractory prostate cancer. *J Nucl Med* 2011; 52(Suppl 1): 1902.
- Groheux D, Giacchetti S, Moretti JL, Porcher R, Espié M, Lehmann-Che J, et al. Correlation of high 18F-FDG uptake to clinical, pathological and biological prognostic factors in breast cancer. *Eur J Nucl Med Mol Imaging* 2011; 38(3): 426–35. [\[CrossRef\]](#)
- Jaiswal S, Chao MP, Majeti R, Weissman IL. Macrophages as mediators of tumor immunosurveillance. *Trends Immunol* 2010; 31(6): 212–9. [\[CrossRef\]](#)
- Tolvanen T, Yli-Kerttula T, Ujula T, Autio A, Lehtikoinen P, Minn H, et al. Biodistribution and radiation dosimetry of [(11)C]choline: a comparison between rat and human data. *Eur J Nucl Med Mol Imaging* 2010; 37(5): 874–83. [\[CrossRef\]](#)
- Lee JE, Giovannucci E, Fuchs CS, Willett WC, Zeisel SH, Cho E. Choline and betaine intake and the risk of colorectal cancer in men. *Cancer Epidemiol Biomarkers Prev* 2010; 19(3): 884–7. [\[CrossRef\]](#)
- Maskery MP, Hill J, Cain JR, Emsley HCA. The Utility of FDG-PET/CT in Clinically Suspected Paraneoplastic Neurological Syndrome: A Literature Review and Retrospective Case Series. *Front Neurol* 2017; 8: 238. [\[CrossRef\]](#)
- Grinde MT, Skrbo N, Moestue SA, Rødland EA, Borgan E, Kristian A, et al. Interplay of choline metabolites and genes in patient-derived breast cancer xenografts. *Breast Cancer Res* 2014; 16(1): R5. [\[CrossRef\]](#)
- Onodera Y, Nam JM, Bissell MJ. Increased sugar uptake promotes oncogenesis via EPAC/RAP1 and O-GlcNAc pathways. *J Clin Invest* 2014; 124(1): 367–84. [\[CrossRef\]](#)
- Kim S, Park HS, Kim JY, Ryu J, Park S, Kim SI. Comparisons of Oncologic Outcomes between Triple-Negative Breast Cancer (TNBC) and Non-TNBC among Patients Treated with Breast-Conserving Therapy. *Yonsei Med J* 2016; 57(5): 1192–8. [\[CrossRef\]](#)
- Hassan H, Abu Bakar S, Halim KN, Idris J, Nordin AJ. Convenient and Efficient Method for Quality Control Analysis of 18F-Fluorocholine: For a Small Scale GMP-based Radiopharmaceuticals Laboratory Set-up. *Curr Radiopharm* 2016; 9(2): 128–36. [\[CrossRef\]](#)

22. Miller PC, El-Ashry D, Lippman ME. Liquid biopsy: expanding the frontier of circulating biomarker discovery and validation in breast cancer. *Cancer Drug Resist* 2019; 2:1215–23. [\[CrossRef\]](#)
23. Kim Y, Paeng JC, Kang KW, Lee DS, Chung JK, Cho JY, et al. F-18-Fluorocholine PET/MRI as a prostate cancer staging and restaging modality: A comparison study with F-18-FDG PET/MRI and PET/CT. *J Nucl Med* 2014; 55(1): 1661.
24. Sindon A, Perin T, Borsatti E. 18F-Fluorocholine PET/CT of Incidental Male Breast Cancer. *Clinical Nuclear Med* 2018; 43(1): 75–6. [\[CrossRef\]](#)
25. Bae SY, Kim S, Lee JH, Lee HC, Lee SK, Kil WH, et al. Poor prognosis of single hormone receptor- positive breast cancer: similar outcome as triple-negative breast cancer. *BMC Cancer* 2015; 15: 138. [\[CrossRef\]](#)
26. Vici P, Pizzuti L, Natoli C, Gamucci T, Di Lauro L, Barba M, et al. Triple positive breast cancer: a distinct subtype?. *Cancer Treat Rev* 2015; 41(2): 69–76. [\[CrossRef\]](#)
27. Vorselaars WM, Kluijfhout WP, Vriens MR, van der Pol CC, Borel Rinkes IH, Valk GD, et al. Detection of Synchronous Parathyroid Adenoma and Breast Cancer with (18)F-Fluorocholine PET-CT. *Nucl Med Mol Imaging* 2016; 50(2): 180–2. [\[CrossRef\]](#)
28. Ward PS, Thompson CB. Metabolic reprogramming: a cancer hallmark even warburg did not anticipate. *Cancer Cell* 2012; 21(3): 297–308. [\[CrossRef\]](#)
29. DeGrado TR, Reiman RE, Price DT, Wang S, Coleman RE. Pharmacokinetics and radiation dosimetry of 18F-fluorocholine. *J Nucl Med* 2002; 43(1): 92-6. Erratum in: *J Nucl Med* 2002; 43(4): 509.
30. Calabria F, Chiaravalloti A, Ciccio C, Gangemi V, Gullà D, Rocca F, et al. PET/CT with 18F-choline: Physiological whole bio-distribution in male and female subjects and diagnostic pitfalls on 1000 prostate cancer patients: 18F-choline PET/CT bio-distribution and pitfalls. A southern Italian experience. *Nucl Med Biol* 2017; 51: 40–54.