

ECCRINE POROMA LOCATED ON LATERAL LEFT EYEBROW

Sol kaş yerleşimli ektrin poroma

Teoman Eskitaşcıoğlu¹, İrfan Özyazgan¹, Hülya Akgün²

Abstract : *Eccrine poroma is a benign sweat gland tumor which arises from the intraepidermal portion of the eccrine sweat ducts. Although acral surfaces such as the palm and sole are common sites for these tumors, it has recently been reported that they may also appear in different locations and on hairy areas of the body. In this article, a case of eccrine poroma located on lateral left eyebrow was presented because of its rareness in the head and neck region, the possibility of malignant degeneration and conflicts in the literature.*

Key Words: *Acrospiroma, Eccrine; head and neck neoplasms; eyebrow.*

Özet : *Ektrin poroma, ektrin bezlerin intraepitelyal duktuslarından köken alan benign ter bezi tümörüdür. El ayası, ayak tabanı gibi akral bölgeler bu tümörlerin sık izlendiği bölgeler olmasına rağmen, bu tümörlerin vücudun farklı bölgelerinde ve kıllı alanlarda da ortaya çıkabileceği bildirilmiştir. Bu sunumda, sol kaş laterali yerleşimli bir ektrin poroma vakası, bu tür lezyonların baş-boyun bölgesinde sık izlenmemesi, malign dejenerasyon gösterbilme olasılıkları ve literatürdeki zıtlıklar nedeniyle sunulmuştur.*

Anahtar Kelimeler: *Akrospiroma, Ektrin; baş ve boyun neoplazmları; kaş*

Eccrine poroma is a benign sweat gland tumor which arises from the intraepidermal portion of the eccrine sweat ducts. Although acral surfaces such as the palm and sole are common sites for these tumors, it has recently been reported that they may also appear in different locations and on hairy areas of the body (1). The clinical appearance resembles various malignant and benign pathologies, such as basal cell carcinoma, squamous cell carcinoma and pyogenic granuloma. On the long term, it is known that these lesions may show malignant transformation (2).

Sweat gland tumors form 1% of primary skin tumors. Poromas form 10% of benign sweat gland tumors (3). Eccrine poroma is a protuberant skin lesion, similar to a dome or pedunculated, and is usually asymptomatic with pink-purple or skin colored lesion which is less than 2cm in diameter. If traumatized they may crust, ulcerate or bleed. The incidence peaks during the seventh decade, although they can also be seen at a younger age. Although rarely seen on the head and neck area, these areas should be considered in differential diagnosis. In this article, a case of eccrine poroma located on lateral left eyebrow was presented because of its rareness in the head and neck region, the possibility of malignant degeneration and conflicts in the literature.

¹ Department of Plastic and Reconstructive Surgery, University of Erciyes, School of Medicine, 38039, Kayseri, Turkey

² Department of Pathology, University of Erciyes, School of Medicine, 38039, Kayseri, Turkey

Geliş tarihi: 15 Haziran 2004

Case

A 62 year old male with no previous health problem presented to our clinic with a mass at the lateral side of the left eyebrow. In physical examination on the lateral left eyebrow, a 1 cm protuberant, 1.5 cm in diameter, nodular, red-purple crusted lesion was observed (Fig 1). It had appeared 4 weeks previously, increased in size and bled occasionally. Because of its clinical appearance, nodular basal cell carcinoma or skin appendage tumor was considered, and incisional biopsy carried out. Histopathology suggested the diagnosis of eccrine poroma, and the lesion was excised and primarily sutured. Histopathologic evaluation of the entire specimen verified the diagnosis of eccrine poroma.

Under light microscopy, a tumor structure composed of uniform looking elliptical-round cells, with basophilic nucleus and narrow eosinophilic cytoplasm was seen. Between the cells, there were eosinophilic material filling cystic regions. The tumor had formed anastomosing bands, extending from the epidermis to the dermis. Intracellular and intercellular vacuoles were observed under high magnification. The tumor was well circumscribed from its surrounding tissue and had a dense inflammatory mononuclear cell infiltrate. In other regions, normal skin appendages were observed (Fig 2A-B).

This patient is still being followed up at our clinic, and has completed the first postoperative year with no evidence of local recurrence.

Discussion

Eccrine poroma was initially reported by Pinkus et al (4). According to the literature, we know that it arises from eccrine glands of the acral region, although it has recently been reported that it may also have an apocrine origin (5,6). There are approximately 3 million eccrine glands in the human body, which are distributed in many regions of the body in different densities (7). They are predominantly seen in the palm and sole, and thus the appearance of eccrine poroma in the head and neck region is not expected. Although it is usually considered that “poromas have apocrine origin”, in the histological evaluation of our case no connection to the apocrine glands was determined.

Eccrine poroma is composed of poroid cells which have basophilic nucleus and cuticular cells with a wide eosinophilic cytoplasm. Intracytoplasmic and intercellular vacuolation, resembling eccrine duct formation, is a characteristic histological feature of this lesion. Eccrine poroma may be classified in 3 main subgroups: hidroacanthoma simplex, dermal duct tumor and poroid hidradenoma. Although they all arise from the same cells, they have different cellular growth patterns. In hidroacanthoma simplex, neoplastic cells completely fill the epidermis, whereas in dermal duct tumors solid focus of neoplastic cells is predominantly located in the dermis. Poroid hidradenoma resembles dermal duct tumors, and in the dermis neoplastic cells show both solid and cystic features (1). In the histological study of our case, it was seen that the lesion showed characteristic features of eccrine poroma, dermal duct tumor subgroup.

Poromas may be confused with numerous skin lesions such as hemangiomas, pyogenic granulomas, nevi, cysts and other adnexal tumors (2). In this case, a diagnosis of basal cell carcinoma was initially considered, and with incisional biopsy the pathological diagnosis was confirmed.

In the largest series presented in reports by Abenzo and Ackerman, of 353 poromas, 30% was located on the face, 10% on the scalp, 14% on the trunk, 15% on the foot and 5% on the hand (1). According to these percentages, in contrast to the literature, these lesions are commonly seen on the head and neck region, where recognition is difficult, and in the long term, due to malignant transformation, may lead to death. Consequently, in the differential diagnosis of these lesions there are important pathologies to consider. Long standing eccrine poromas may show malign transformation (malignant eccrine poroma-porocarcinoma), which may lead to multiple cutaneous and lymphatic metastases, and later to the death of the patient (2). Moore et al. (5) compared head and neck poromas with extremity poromas and reported that, unlike poromas found on the extremities, head and neck poromas had no gender predilection, and were usually asymptomatic and never correctly diagnosed clinically.

Therefore, the principal treatment of eccrine poromas should be excision and a correct histopathological diagnosis. When these situations are considered, although it is clinically a rare condition, it is important to consider eccrine poroma in differential diagnosis of head and neck tumors.

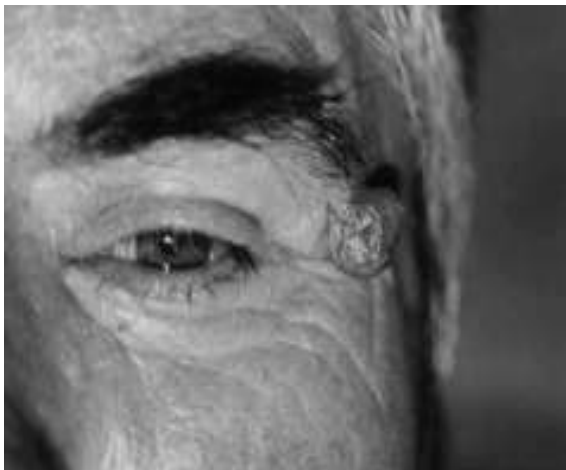

Fig. 1: View of lesion on lateral eyebrow.

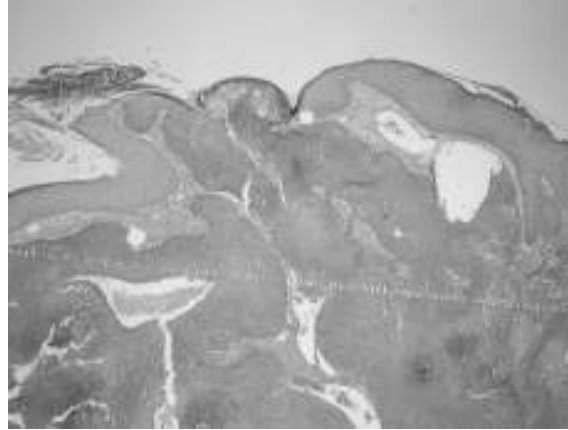


Fig. 2A: Tumor cells were extended downward into the dermis as tumor masses consisting of broad, anastomosing bands (HE x 20).

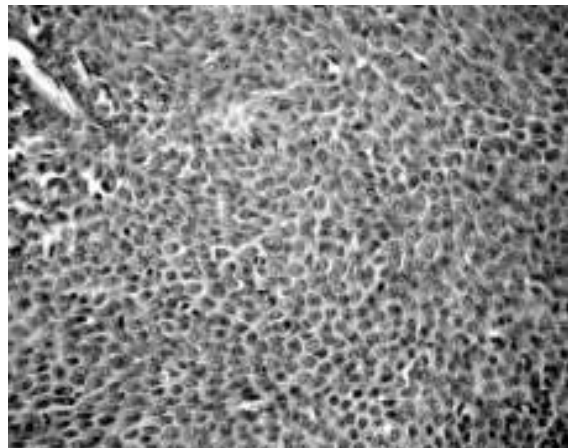


Fig 2B: The neoplastic cells are composed of cells with dense basophilic nuclei and scant cytoplasm and cells with abundant eosinophilic cytoplasm (HE x 400)

REFERENCES

1. Abenzoa P, Ackerman AB. Neoplasm with eccrine differentiation. Philadelphia: Lea & Febiger; 1990, pp113-185.
2. Elder D, Elenitsas R, Ragsdale BD. Tumors of the epidermal appendages. In: Elder D, Elenitsas R, Jaworsky C, et al, editors. Lever's histopathology of the skin. 8th ed. Philadelphia : Lippincott-Raven; 1997, pp 704-804.
3. Pylyser K, Dewolf-Peeters C, Marlen K. The histology of eccrine poromas: a study of 14 cases. *Dermatologica* 1983; 167:243-249.
4. Pinkus H, Rogin JR, Goldman P. Eccrine poroma: tumors exhibiting features of the epidermal sweatduct unit. *Arch Dermatol* 1956;74:511-521.
5. Moore TO, Orman HL, Orman SK, et al. Poromas of the head and neck. *J Am Acad Dermatol* 2001; 44:48-52.
6. Harvell JD, Kerschmann RL, LeBoit PE. Eccrine or apocrine poroma? Six poromas with divergent adnexal differentiation. *Am J Dermatopathol* 1996; 18:1-9.
7. Szabo G. The regional anatomy of the human integument with special reference to the distribution of hair follicles, sweat glands and melanocytes. *Philos Trans R Soc Lond B Biol Sci.* 1967;252: 447-485.