

Two Multiple Sclerosis Cases Confused with Cerebral Tumor

Serebral Tümörle Karışan İki Multiple Skleroz Olgusu

Vaner Köksal, MD.

Department of Neurosurgery,
Erciyes University Medical Faculty
vkoksal@erciyes.edu.tr

Mehmet Ali Ekici, MD.

Clinics of Neurosurgery
State Hospital of Kayseri

Ahmet Menkü, MD.

Department of Neurosurgery,
Erciyes University Medical Faculty
menkuaerciyes.edu.tr

Turgay Bulut, MD.

Department of Neurosurgery,
Erciyes University Medical Faculty
bulut.turgay@hotmail.com

İbrahim Suat Öktem, MD.

Department of Neurosurgery,
Erciyes University Medical Faculty
oktemis@hotmail.com

*This study was presented on 21th National Neurosurgery Congress,
May, 01, 2007, Antalya, Turkey.*

Submitted : April 25, 2007
Revised : May 26, 2007
Accepted : August 26, 2007

Corresponding Author:

Vaner Köksal, MD.,PHD.
Department of Neurosurgery,
Erciyes University Medical Faculty,
Kayseri, Turkey.

Telephone : +90 -352 3395099
E-mail : vkoksal@erciyes.edu.tr

Abstract

Multiple sclerosis (MS) is an inflammatory disease of central nervous system. As a result of the damage done to the myelin, lesions termed as plaques are formed in the white matter. The sizes of those plaques vary from milimetric values to 4-5cm. Large lesions of that size may behave like an abscess or tumor in the brain. Differentiating single lesions from gliomas, and distinguishing multiple lesions from tumor or abscess, are not easy processes. In the present study, we made an effort to denote that large and multiple MS lesions should be included in the differential diagnosis of intracranial space-occupying lesions, as well.

Key Words: **Brain neoplasms, demyelination diseases, multiple sclerosis.**

Özet

Multipl Skleroz (MS) santral sinir sisteminin otoimmün inflamatuvar bir hastalığıdır. Miyelinin hasarına bağlı olarak beyaz cevherde plak adı verilen lezyonlar oluşturur. Bu plakların boyutları milimetrik birimlerden 4-5 cm'e kadar değişebilir. Bu boyuttaki büyük lezyonlar beyinde tümör veya bir apse gibi davranış sergileyebilir. Tek olan lezyonları gliomlardan ve iki veya daha çok sayıda olanları metastatik tümör veya apseden ayırmak kolay olmaz. Bu yazıda intrakraniyal yer kaplayıcı lezyonların ayırıcı tanısında, multipl karakterli ve büyük boyutlu MS lezyonlarının da hatırlanması gerekliliğini vurgulamaya çalıştık.

Anahtar kelimeler: **Beyin Neoplazmları; Demiyenizasyon hastalıkları; Multiple skleroz.**

Introduction

Multiple sclerosis (MS) is an autoimmune disease that affects central nervous system. Defensive cells of the immune system begin to recognize myelin sheath enclosing the neurons, as a noxious foreign body due to some reason we don't know yet, and start to destroy it. Clinical signs and symptoms are a result of this event. The inflammation starting with the damage in the myelin sheath is called as sclerosis (demyelination) (1). The disease follows a course of intermittent attacks. The periods between attacks vary relative to the level of the disease. The disease is mostly seen in adults between 20-40 age. The incidence among women is twice the incidence for men. The development of each MS patient varies in terms of durations and symptoms. The disease has 5 known levels as follows: Benign, relapsing-remitting, secondary progressive, primary progressive, and progressive-relapsing.

The diagnosis of the disease is established by evaluating clinical symptoms, neurological examination, and magnetic resonance imaging (MRI) method. Advanced methods such as CSF analysis and "evoked potentials" are required for verification of the diagnosis. Typical MS patients may exhibit; ataxic movements, Babinski syndrome, blurred or double vision, temporary blindness, nystagmus, hyperactive deep tendon reflexes or clonus, clumsiness, dysarthria, various speech disorders, easy mood swings, fatigue, paralysis in certain muscle groups, monoparesis or complete paresis, paresthesia or paresthesias, frequent urination or urinary incontinence, coordination disorder, balance defects or gait abnormalities (1).

Sizes of MS plaques vary between milimetric values to 4-5cm. Particularly large lesions can display a different clinical behavior in brain similar to those of a tumor (2,3). While it is difficult to distinguish large single MS lesions from particularly glial tumors, discriminating two or more lesions from tumor metastases or atypical abscess, may prove to be difficult (2,3).

In the present study, we made an effort to denote that large and multiple MS lesions should be included in the differential diagnosis of intracranial space-occupying lesions, as well.

Case Report

Case 1. A 26-year-old female patient presented to the Medical School Hospital of Erciyes University with a sudden onset of fatigue in her left arm and leg 10 days ago followed by headache and repeated vomiting. Neurological examination revealed strength loss of 3/5 in left arm and 4/5 in left leg. Computed tomography (CT) and MRI showed 2 lesions of 4x5cm size exhibiting peripheral edema, regular margins and heterogeneous enhancement on both parietal hemispheres (Figure 1).

Case 2. A 34-year-old female patient presented to the Medical School Hospital of Erciyes University with weakness in the left side of her body and speech disorder. History of the patient revealed a similar condition experienced 8 years ago by her. MRI examination showed lesions of 4x3cm in both parietal hemispheres and a lesion of 2x2cm in temporal lobe all of which caused peripheral edema and exhibited heterogenous enhancement and regular contours (Figure 2).

Because all the clinical and radiologic findings suggested a metastatic tumor in both of the cases and due to absence of adequate information on large multiple MS lesions in the literature, initially, stereotaxic biopsy was considered appropriate. However, biopsy result was evaluated as MS. The following treatments of the cases were referred to the Neurology Department. Due to absence of severe neurological deficits, first, IV pulse steroid therapy (methylprednisolone) at 1000mg/day was applied for 3 days and then oral dexamethasone therapy was performed at 16mg/day dose. Oral steroid dose was reduced and discontinued at the end of the 3rd week. As a result of this 3-week steroid therapy, MRI examination showed a reduction in sizes of those large lesions (Figure 3).

One year later, lesions completely disappeared from the MRI. Clinical symptoms of the cases were cleared after the steroid therapy, as well.

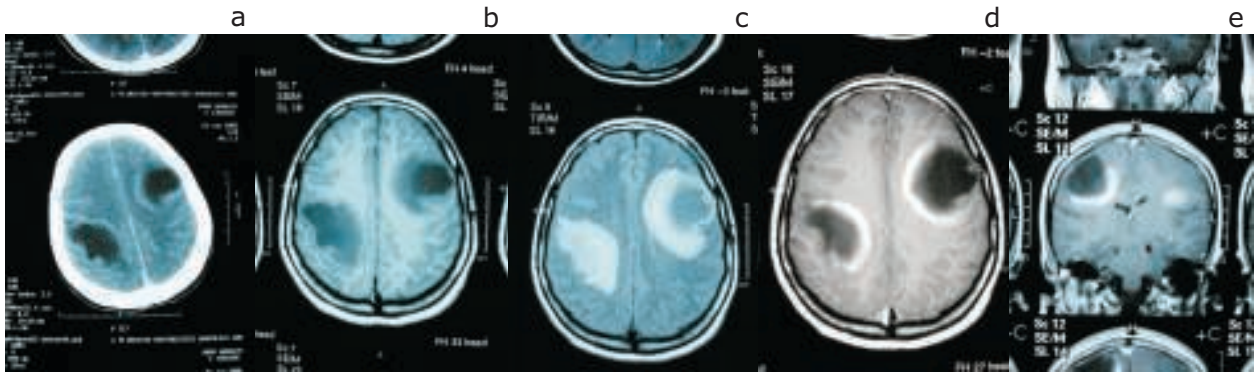


Figure 1. CT view before treatment (a), T1 axial MR image prior to surgery (b), T2 flair view (c), contrast axial (d) and coronal (e) view.

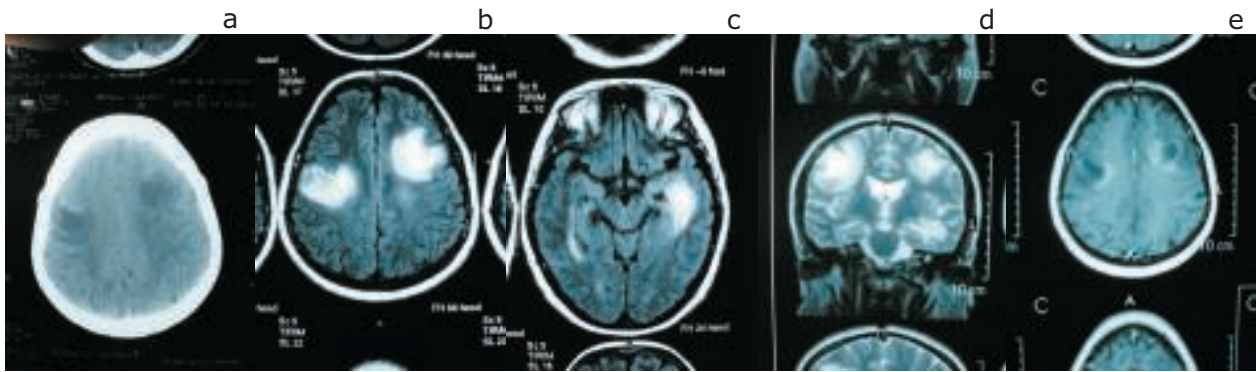


Figure 2. CT view before treatment (a), operation, T2 flair view (b), T2 flair view showing temporal lesion (c), T2 coronal view of the 3rd lesion in left temporal region (d) and contrast axial (e) view.

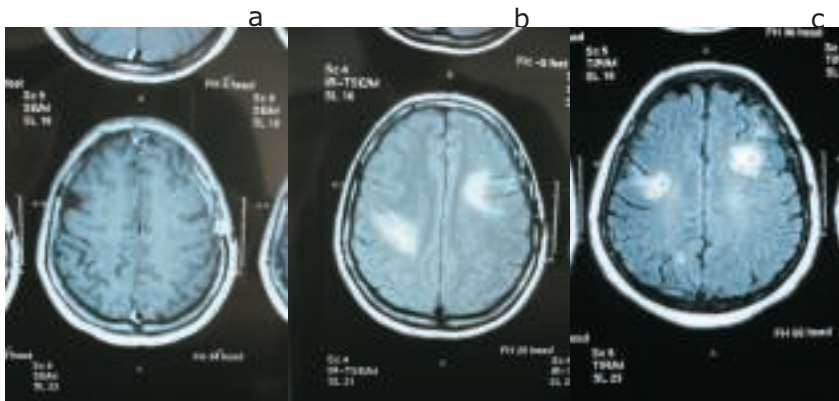


Figure 3. Contrast T1 view of the case I by postoperative 2nd month, cortical incision can be seen in the right frontal (a). 1. T2 flair view of the case 1 by postoperative 2nd month (b) and T2 flair view of case 2 by postoperative 2nd month (c).

Discussion

Typical MS lesions are viewed on MRI as irregular multiple lesions (MS plaque) exhibiting elevated signal intensity that are localized in white matter and particularly in close proximity with lateral ventricles, and frontal and occipital horns. Their diameter vary between 0.5-3cm. Besides periventricular area, plaques are commonly localized in centrum semiovale, corpus callosum, brain stem, and cerebellum. Infratentorial lesions are mainly localized in white matter, peduncles and fourth ventricle. High intensity lesions (plaques) on T2-weighted images are observed as low intensity areas on T1-weighted images (1,4,5,6).

Regarding distribution of lesions, most common lesions show periventricular localization; while lesions adjacent to trigone and lateral ventricles has an incidence of 96%, lesions adjacent to occipital lobe exhibit an incidence of 83% and lesions adjacent to frontal lobe show an incidence of 73% (7). Plaques in fourth ventricle base have an incidence of 60.3% and plaques adjacent to ventricle showed an incidence of 34% (7). While white matter involvement observed apart from the ventricles is most commonly seen particularly in centrum semiovale with an incidence of 90%; involvement rates of brain stem, corpus callosum, cerebellar hemispheres are known to be 68%, 55%, and 49%, respectively (7). However, incidence of internal capsula lesions are reported as 11% and incidence of basal ganglia lesions are reported as 25% (7).

Clinically, because MRI positivity can reach to a rate of 85-95% in patients diagnosed with MS, MRI has become one of the standard elements of diagnostic process. However, several criteria have been developed in order to render MRI more reliable for diagnosis of MS.

The underlying reason of the elevated signal intensity (typically observed in the proton study and T2-sequence) which is known to be the most important radiologic feature of MS plaques, has not been explained yet. It is thought to be occurring due to edema, inflammation, and increased water content of white matter (5,8). Both of our cases exhibited lesions suggestive of MS on their T2 MR images.

Mass lesions similar to large unilateral or multiple tumors are described for MS, as well. These lesions may also be of cystic appearance. Generally, their clinical symptoms occur as a result of mass effects. This MS type is called

as atypical MS or tumefactive MS (9,10,11,12). The radiographs of the presented cases are of same character, as well.

Recently, different but hard to distinguish pathologies have been added to the primary tumefactive demyelinating diseases (10). Although clinical and radiologic appearances of those diseases show similarities, they can be discerned by their histopathological appearances (10). Myelinoclastic Diffuse Sclerosis (MDS or Schilder disease), Acute Disseminated Encephalomyelitis (ADEM), Post infectious encephalomyelitis, and Progressive Multifocal Leukoencephalopathy (PML) are described as MS variants (10). The clinical symptoms and pathological diagnoses of our patients were not complying with these tumefactive MS variants.

History of patients diagnosed with ADEM include an acute onset, and generally reveal an infectious disease suffered 2-20 days previously. It has been reported to be associated with chicken pox, rubella, mumps, EBV, CMV, influenza, coxsackie B viruses (7). Systemic symptoms such as fever, irritability, and lethargia can be seen. Mental changes and seizures may be encountered. Generally, it is seen in people under 12 age. Lesions are localized in subcortical white matter and perivenular hemorrhages are seen in frequently changing levels (2). However, initial clinical profile can not lead to discrimination of ADEM from MS (2). No association could be founded between clinical histories of our cases and ADEM.

MDS is the second common disease in cases which exhibit MRI results suggestive of MS. It is also called as Schilder disease or Balo concentric sclerosis. It is a rare, sporadic disease and may present with acute or subacute onset. Most commonly encountered in children between 5-14 age. Mental destruction, loss of hearing and vision, hemiplegia or tetraplegia characterized by large asymmetrical demyelination areas, and a clinically progressive nature may be seen. Generally, patients present with KIBAS symptoms. They can not be distinguished from tumefactive MS. Biopsy and resection are performed (2,11). The clinical histories of cases presented here, are considered as parallel with MDS diagnosis.

Cases presenting with a tumefactive demyelinating lesion, can only be differentiated from tumors by their clinical profile. They can be seen as a single or multiple space-occupying tumor. When a semilunar contrast is determined by MRI, it is considered as a false tumor or abscess

(2,3,13). A typical semilunar contrast enhancement was determined on MRI images of the cases.

Generally, demyelinating lesions exhibit a circular pathologic contrast. In tumefactive MS type, semicircular or semilunar (open side facing exterior aspect) contrast enhancement is seen more frequently. This specific enhancement suggests active MS for those patients (11). Center of those lesions never show contrast enhancement. Central part may include dilated veins. These dilated veins are believed to drain towards subependymal veins. This central area is a necrotic and silence area just as in glioblastoma. The size of this lesion rarely reaches 4-5cm (9,10,14). Those lesions forming in MS type, generally localize in supratentorial and white matter. Although they are large lesions, their mass effect and peripheral edema are minimal (14). In radiological evaluation of those patients, different MRI techniques other than routine ones, have been used, as well. Those techniques include diffusion MRI and Proton MR spectroscopy (9). Diffusion MRI has been used in the present study on our cases. However, the results were found to be inadequate for distinction from tumors.

Diffusion study on tumefactive MS lesions, exhibited a moderate diffusion increase (9). However, in cases (such as MS) with cerebral abscess showing circular enhancement, a decrease in diffusion is observed (9). Necrotic neoplasms like glioblastoma exhibit an elevation of diffusion. In order to distinguish tumefactive demyelinating lesions and such a high grade glioma, proton MR spectroscopy is used. By this method, chemical content of the lesions are compared. Evaluations are carried out by examining choline/creatinine ratio in peripheral part of the lesion, and examining N-acetyl aspartate/creatinine ratio in central part of the lesion (9). N-acetyl aspartate ratio in central part, is found to be

decreased in gliomas due to creatinine elevation. However, despite all that, because there are cases which can not be diagnosed, application of stereotaxic surgical biopsy is recommended in the literature (2,9,15). In the present study, despite the same dilemma, stereotaxic biopsy has been applied on both of the patients.

This diagnostic dilemma has been mentioned in the pathology literature, as well. Histopathological results obtained from the biopsy, may mislead us. Particularly, hypercellularity, atypical reactive astrocytes and necrotic areas may lead to a misdiagnosis of malignant glial neoplasm. This condition, may occur as a result of unnecessary adjuvant radiotherapy which has a damage potential (2). Therefore, specific immunohistochemical stains are recommended (2). Proton MR spectroscopy has been recommended for solving this diagnostic dilemma. However, definitive diagnosis is established by the final pathologic evaluation and treatment is accordingly managed (2,3,15). Thus, if biopsy will be taken despite all that, it is recommended to take the biopsy from the inner side of the wall exhibiting contrast enhancement (2,15). Tumor-like MS lesions are described as a form between typical MS and ADEM in a serie of Kepes including 27 cases. Pathology of those lesions can not be distinguished from typical MS plaques (14).

In conclusion, uncommon demyelinating lesions should be differentiated from lesions in form of intracranial mass or abscess by neuroradiology or through histopathology in uncertain cases. For this, while primarily stereotaxic biopsy is recommended, if not available, open surgery might work as well; however, particularly when there is a suspicion on MRI results, we believe that noninvasive methods such as examining oligoclonal band presence in CSF, evoked nerve potentials and diffusion arthroscopy can lead to the accurate diagnosis, as well.

References

1. Rolak L. Multiple Sclerosis. In: Appel SH, editor. *Current Neurology*. Chicago; Year Book Med. Publ. Inc: 1989. p.109-148.
2. Anderson RC, Connolly ES Jr, Komotar RJ, et al. Clinicopathological review: tumefactive demyelination in 12 year old girl. *Neurosurgery* 2005; 56: 1051-1057.
3. Mastrostefano R, Occhipinti E, Bigotti G, Pompili A. Multiple sclerosis plaque simulating cerebral tumor: case report and review of the literature. *Neurosurgery*. 1987; 21: 244-246.
4. Kirshner HS, Tsai SI, Runge VM, Price AC. Magnetic resonance imaging and other techniques in the diagnosis of multiple sclerosis. *Arch Neurol* 1985; 42: 859-863.
5. McDonald WI: The role of NMR imaging in the assessment of multiple sclerosis. *Clin Neurol Neurosurg*. 1988; 90:3-9.
6. Paty DW. Magnetic resonance in multiple sclerosis. *Curr Opin Neurol Neurosurg*. 1993; 6: 202-208.
7. Ormerod IE, Miller DH, McDonald WI, et al. The role of NMR imaging in the assessment of multiple sclerosis and isolated neurological lesions. A quantitative study. *Brain*. 1987; 110:1579-1616.
8. McDonald WI, Barnes D. Lessons from magnetic resonance imaging in multiple sclerosis. *Trends Neurosci*. 1989; 12: 376-379.
9. Saindane AM, Cha S, Law M, Xue X, Knopp EA, Zagzag D. Proton MR spectroscopy of tumefactive demyelinating lesions. *AJNR Am J Neuroradiol* 2002; 23:1378-1386.
10. Dagher AP, Smirniotopoulos J. Tumefactive demyelinating lesions. *Neuroradiology* 1996; 38:560-565.
11. Eblen F, Poremba M, Grodd W, Opitz H, Roggendorf W, Dichgans J. Myelinoclastic diffuse sclerosis (Schilder's disease): cliniconeuroradiologic correlations. *Neurology* 1991; 41:589- 591.
12. Ernst T, Chang L, Walot I, Huff K. Physiologic MRI of a tumefactive multiple sclerosis lesion. *Neurology*. 1998; 51:1486-1488.
13. Di Patre PL, Castillo V, Delavelle J, Vuillemoz S, Picard F, Landis T. "Tumor-mimicking" multiple sclerosis. *Clin Neuropathol*. 2003; 22:235-239.
14. Given CA 2nd, Stevens BS, Lee C. The MRI appearance of tumefactive demyelinating lesions. *AJR Am J Roentgenol*. 2004; 182:195-199.
15. Garell PC, Menezes AH, Baumbach G, et al. Presentation, management and follow-up of Schilder's disease. *Pediatr Neurosurgery* 1998; 29: 86-91.