

# Sacral Parasite Conjoined Twin Mimicking Sacrococcygeal Teratoma: Multi-Detector CT Findings

## Sakrokoksigeal Teratoma Benzeyen Sakral Parazitik Yapışık İkiz: Multi-Dedektör BT Bulguları

### Mecit Kantarcı

Assoc Prof., MD.  
Department of Radiology  
Faculty of Medicine, Atatürk University  
drmecit@atauni.edu.tr

### Hayri Ogul

MD.  
Department of Radiology  
Faculty of Medicine, Atatürk University

### Selim Doganay

Specialist, MD.  
Department of Radiology  
Erciyes University, Faculty of Medicine  
selimdoganay@gmail.com

### Adnan Okur

Prof., MD.  
Department of Radiology  
Faculty of Medicine, Atatürk University  
adnanokur@atauni.edu.tr

### Abstract

Sacral parasite conjoined twins are rare form of conjoined twins. Differential diagnosis of the parasitic twin includes fetus in fetu (internal parasite) and teratoma. A 2900 g boy was born by normal vaginal delivery to a healthy young mother. At birth, the infant was found to have a large mass, attached to his sacrococcygeal region. Radiologic and histopathological examinations showed long and short bones within the sacral parasite. We present a rare case of parasitic conjoined twin attached to the sacrococcygeal region of the autosite who were evaluated by multidetector computed tomography including 3D volume rendering images.

Key words: **Conjoined Twins; Computed Tomography; Bone; Teratoma**

### Özet

Sakral parazitik yapışık ikiz, yapışık ikizlerin nadir bir formudur. Parazitik ikizlerin ayırıcı tanısında internal parazit (fetüs içinde fetüs) ve teratom sayılabilir. 2900 g erkek bebek vajinal yolla sağlıklı genç anneden doğdu. Doğumda olgunun sakrokoksigeal bölgesinde büyük bir kitle mevcuttu. Radyolojik ve histopatolojik tetkiklerde sakral parazit içerisinde uzun ve kısa kemikler tesbit edildi. Biz bu sunumda çok nadir görülen sakrokoksigeal bölgeye yerleşmiş parazitik yapışık ikiz vakasını multidedektör BT ve üç boyutlu volüm rendering tekniği ile gösterdik.

Anahtar Sözcükler: **Bilgisayarlı Tomografi; Kemik; Teratom; Yapışık İkiz.**

Submitted : April 02, 2008  
Revised : December 22, 2008  
Accepted : February 05, 2010

### Corresponding Author:

Uzm. Dr. Selim Doganay  
Department of Radiology  
Faculty of Medicine, Erciyes University  
38039- Kayseri, Turkey

Telephone : +90 - 352 437 49 37  
E-mail : selimdoganay@gmail.com

## Introduction

Sacral parasitic conjoined twins are rare anomalies. Of all monoamniotic, monochorionic, and monozygotic twins, 10% are conjoined (1). Conjoined twins are classified according to their symmetry, site and extent of union, and degree of duplication. We present an unusual case of sacral parasitic conjoined twin who was evaluated by multidetector computed tomography (MDCT) and 3D volume rendering.

## Case report

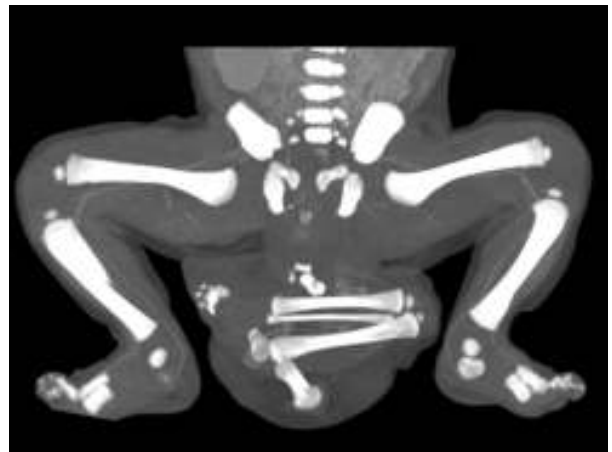
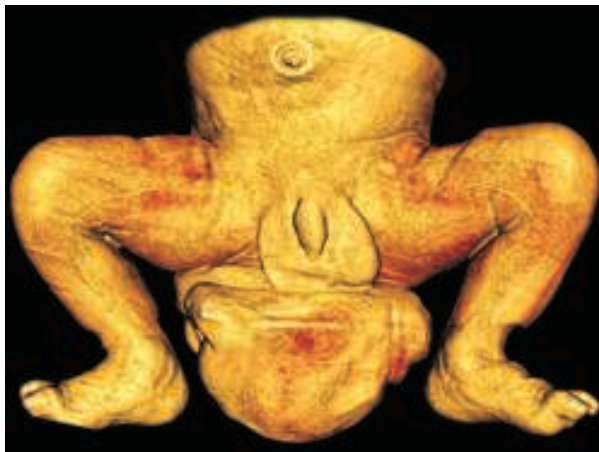A 2900 g boy was born by normal vaginal delivery to a healthy 32-year-old mother after an uncomplicated gestation of 39 weeks. There was no history of congenital anomalies in the family or drug intake during pregnancy. Serial prenatal ultrasounds had indicated an enlarging mass in the sacrococcygeal region, without any evidence of fetal distress and other organ or system anomalies.

At birth, the healthy, actively crying infant was found to have a large mass, 6-8-10 cm in size, attached to his sacrococcygeal region. The mass had a bony-hard feel underneath the skin, which was pushing the anal orifice forward and extending to both buttocks. It was completely covered with skin that was continuous with that of the infant. Physical examination findings were suggestive of sacrococcygeal teratoma.

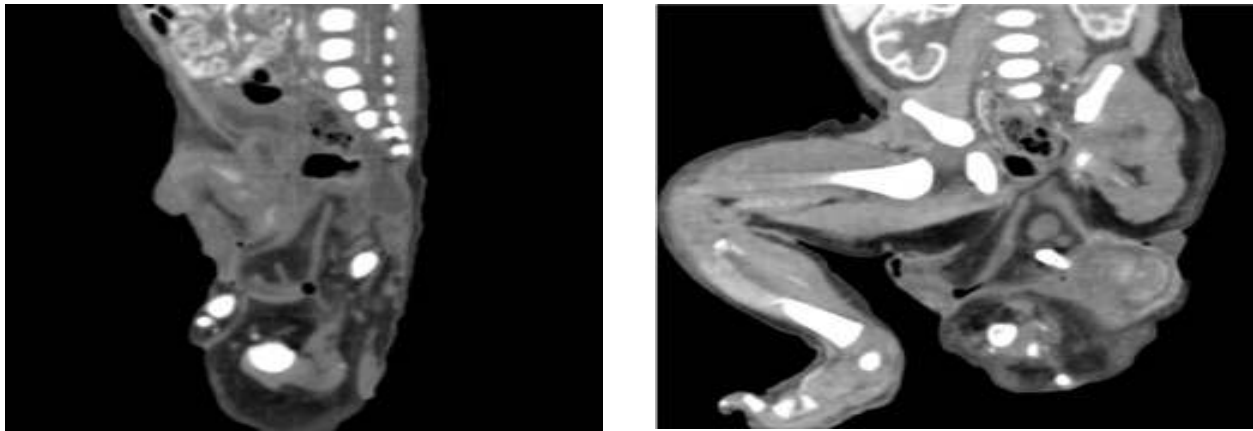
CT scans were acquired with the use of a 16-row multidetector computed tomography (MDCT) scanner (Aquillon, Toshiba Medical Systems, Tokyo, Japan) and with the patient in the supine position. The images were

obtained to define the caudocranial extent of the pelvis-to-lower limbs region (collimation, 1 mm x 16 rows; pitch, 3; gantry rotation speed, 0.75 second per round; voltage, 120 kV; current, 250 mA). Three-dimensional images were reconstructed using maximum intensity projection and 3D volume-rendering algorithms with imaging software (Vitrea 2, Vital Images, Inc.). Intravenous contrast material for imaging is administered with doses calculated per kilogram of weight of the baby (1 mL/kg). A water-soluble, nonionic, iodine-based contrast medium is used for computed tomographic (CT). Volume-rendered 3D CT (Pic. 1a) and maximum-intensity-projection (Pic. 1b) images showed one soft tissue mass with partial bone structure (including half a pelvis, a femur, a fibula, a tibia, and partial foot bones) at the sacrococcygeal area. Contrast-enhanced sagittal and coronal oblique (Pic. 2a-b) MDCT images of the baby revealed a large well-defined mass at the sacrococcygeal area with predominant fat attenuation and well-developed bony structures. These scans showed the presence of a small-sized bony pelvis and the mass. MDCT findings were interpreted as sacral parasitic conjoined twin.

Patient was referred to our pediatric department to be assessed for surgical correction. Surgery was performed when the baby was 1 week old. The mass was excised. After dissection of the mass, bone of one lower limb and some pelvic bone were seen. Histopathologic examination of the excised mass showed lipomatous tissue in the connective tissue stroma, cartilage, muscles, and a well-developed lower limb bones.



**Picture 1.** Volume-rendered 3D computed tomography (a) and maximum intensity projection (b) images shows one soft tissue mass with partial bone structure at the sacrococcygeal area.



**Picture 2.** Contrast-enhanced sagittal (A) and coronal oblique (B) multidetector computed tomography images show a large well-defined mass at the sacrococcygeal area with predominant fat attenuation.

### Discussion

Conjoined twin cases are rare, but the exact prevalence is not known. The estimated prevalence in the literature varies widely, from 1:30,000 to 1:200,000 (2, 3). Forty percent to 60% of conjoined twins are stillborn (4), and 70% are female (5). Sacral parasite conjoined twins are rare form of conjoined twins and consist of an incomplete twin (parasite) attached to the fully developed body of the normal twin (autosite) in the sacrococcygeal region.

Conjoined twins develop from a single fertilized ovum; there is failure of division of the embryonic disk between 13 and 17 days gestation (4). These twins are classified as symmetrical and asymmetrical. The asymmetric type is known as heteropagus. Heteropagus twinning is characterized by a parasitic portion, usually smaller than the well-formed fetus (the autosite). The dependent portion (the parasite) may be attached to in the autosite.

Differential diagnosis of the parasitic twin includes fetus in fetu (internal parasite) and teratoma. Teratomas found more frequently in the sacrococcygeal area than in any other location (6). The sacrococcygeal teratoma is the most common neoplasm of the newborn. It shows great variation in shape, size, and content. Fetiform teratoma is a rare entity, which refers to the teratoma shaped like a fetus (7). A sacral parasite may be diagnosed as a sacrococcygeal teratoma, which sometimes appears as a tumor-like mass. A teratoma is a neoplasm with malignant potential; therefore, the distinction between parasite and teratoma is clinically important (8).

Certain radiological investigations are desirable in evaluating conjoined twins. The prenatal diagnosis of

conjoined twins can be made with ultrasonography as early as 12 weeks gestation (4). More accurate evaluation of visceral conjunction is possible at 18 to 20 weeks gestation and should include detailed ultrasonography (4, 9). Prenatal sonography has the advantage of offering a reliable method of detecting anomalies of fetal growth and structure.

Therapeutic options include emergency separation, or planned separation. Emergency separation is usually performed in the neonatal period. The ideal is elective surgery at 6–12 months of age (4, 9). The separation of the parasitic conjoined twins presents a challenge to pediatric surgeons. Accurately define of the anatomic fusion and associated abnormalities are important for surgical planning and prognostic information. Accurate preoperative imaging aids in successful separation of parasitic conjoined twins. Magnetic resonance imaging (MRI) and multi detector computed tomography (MDCT) techniques provide well anatomic detail. MDCT performed with bone algorithms and three-dimensional reconstruction is excellent for evaluation of bone fusion abnormalities (4). In addition, three-dimensional reconstruction CT imaging may be helpful in planning osteotomies for pelvic ring closure after separation.

As a conclusion, distinguishing a sacral parasite from a teratoma is so important. It may be diagnosed as a teratoma, which sometimes appears as a tumor-like mass. The detailed anatomic information obtained by the image method can guide the surgical planning. The MIP and 3D volume rendered MDCT images are useful imaging modalities in complex anomalies like parasitic twin, as it was in the presented case.

### Kaynaklar

- 1.Hähnel S, Schramm P, Hassfeld S, Steiner HH, Seitz A.Craniofacial duplication (diprosopus): CT, MR imaging, and MR angiography findings - case report. *Radiology* 2003; 226:210–213.
2. Kantarci M, Alper F, Eren S, et al. Omphalopagus conjoined twins: ultrafast MR imaging findings. *Diagn Interv Radiol* 2006; 12:187-189
- 3.Barth RA, Filly RA, Goldberg JD, Moore P, Silverman NH. Conjoined twins: prenatal diagnosis and assessment associated malformations. *Radiology* 1990; 177:201-207.
- 4.Kingston CA, McHugh K, Kumaradevan J, Kiely EM, Spitz L. Imaging in the preoperative assessment of conjoined twins. *Radiographics* 2001; 21:1187–1208.
- 5.Gul A, Aslan H, Ceylan Y. Prenatal diagnosis of pygopagus tetrapus parasitic twin: case report. *BMC Pregnancy Childbirth* 2004; 4:13
- 6.Spencer R. Parasitic conjoined twins: external, internal (fetuses in fetu and teratomas), and detached (acardiacs). *Clin Anat* 2001; 14:428-444.
- 7.Aslan A, Karagüzel G, Gelen T, Melikoğlu M. Sacrococcygeal teratoma showing organoid differentiation: report of a case. *Surg Today*. 2003;33:560-563.
- 8.Chou SY, Liang SJ, Wu CF, Hsu CS. Sacral parasite conjoined twin. *Obstet Gynecol*. 2001; 98:938-940.
- 9.Spitz L. Conjoined twins. *Br J Surg*. 1996; 83:1028–1030.