

Cutaneous Metastases From Transitional Cell Carcinoma of the Bladder (In a Case with Two Primaries)

Transizyonel Hücreli Mesane Kanserinin Cilt Metastazı (İki Primeri Olan Bir Vakada)

Gamze Ugurluer

Assist.Prof., MD
Department of Radiation Oncology
Faculty of Medicine, Yüzüncü Yıl University
gamzeugurluer@gmail.com

Erkan Dogan

Assist.Prof., MD
Department of Radiation Oncology
Faculty of Medicine, Yüzüncü Yıl University
erkandogan@yahoo.com

Nedim Turan

Assist.Prof., MD
Department of Internal Medicine
Faculty of Medicine, Yüzüncü Yıl University
nedimturan@hotmail.com

Abstract

Cutaneous metastases from primary genitourinary malignancies are rare and, like all metastases, have a poor prognosis. Very few cases of skin metastases from urothelial carcinoma have been reported in the past and most of them were treated with chemotherapy. Here we present a case of cutaneous metastases from a primary bladder transitional cell carcinoma who was admitted to our clinic with pain and bleeding of the lesion on the dorsum of the hand which did not respond to chemotherapy and was treated with palliative radiotherapy.

Key words: **Bladder; Metastases; Radiotherapy; Transitional Cell Carcinoma.**

Özet

Mesane kanserinin cilt metastazı nadirdir ve diğer tüm metastazlar gibi kötü prognozlidir. Ürotelyal karsinomların cilt metastazları geçmişte çok az bildirilmiştir ve çoğu kemoterapi ile tedavi edilmiştir. Biz bu çalışmada kliniğimize el dorsumunda ağrılı ve kanamalı transizyonel hücreli mesane kanserinin cilt metastazı ile başvuran, uygulanan kemoterapiye yanıt vermeyen ve palyatif radyoterapi ile tedavi edilen bir olguyu sunmayı amaçladık.

Anahtar kelimeler: **Mesane; Metastaz; Radyoterapi; Transizyonel Hücreli Kanser.**

Submitted : February 07, 2009
Revised : August 10, 2009
Accepted : April 30, 2010

Corresponding Author:

Yard. Doç. Dr. Gamze Ugurluer
Yüzüncü Yıl Üniversitesi, Tıp Fakültesi
Radyasyon Onkolojisi Anabilim Dalı
Van- Turkey

Phone : 0 532 250 91 72
E-mail : gamzeugurluer@gmail.com

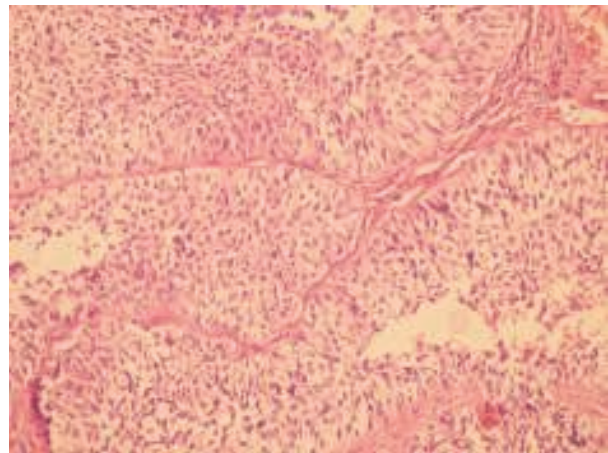
Introduction

The overall incidence of cutaneous metastasis from primary solid visceral malignancies is 2.9% to 5.3% (1, 2). The most common site of metastases is the skin of the chest wall, with breast cancer being the most common pathologic subtype, with an incidence of 24%. The incidence of cutaneous metastasis from all urologic malignancies is 1.1% to 2.5% (3). Metastasis to the skin from renal cell carcinoma is the most common (3.4% to 4.0%), followed by bladder (0.84% to 3.6%), prostate (0.36% to 0.7%), and testis (0.4%) tumors. Here we present a case of cutaneous metastasis from transitional cell carcinoma (TCC) of the bladder, who was admitted to our clinic with pain and bleeding of the lesion on the dorsum of the hand which was treated with palliative radiotherapy with a good result.

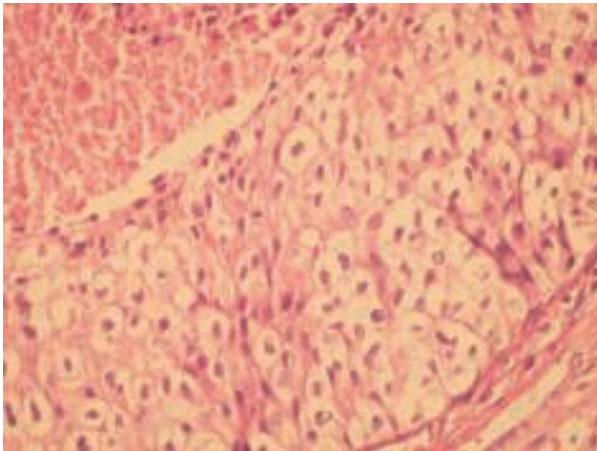
Case report

A 55 years old male patient presented to our outpatient clinic with a three month history of a painful, bleeding lesion on the dorsum of his left hand. He was diagnosed as bladder cancer 6 years prior at another institution and he had undergone transurethral resection of tumor. Histopathological examination had revealed poorly differentiated (grade III) muscle invasive transitional cell carcinoma with a staging of T2N0M0. But the patient had refused the treatment. After 1.5 years he had presented to our hospital's urology clinic with hematuria. Magnetic resonance imaging had demonstrated a lesion on lateral of bladder with involvement of perivesical tissue, transurethral resection was done and histopathology was poorly differentiated (grade III) muscle invasive transitional cell carcinoma. Radical cystoprostatectomy was advised but he had refused the treatment again. MVAC (methotrexate, vinblastine, adriamycin and cisplatin) was started then and he had 6 cycles. After a three years of initial bladder cancer diagnosis the patient was presented with difficulty in swallowing solid foods. Computed tomography had demonstrated annular thickening of cricoesophageal junction and a 15x8 mm nodule was seen on apical segment of right upper lobe of lung. Endoscopy had revealed a fragile, irregular lesion in the 20th cm of esophagus and biopsy was done, the histopathology was squamous cell carcinoma. Upper abdominal ultrasonography was normal. The patient had refused the surgical treatment option again (laryngectomy) for his second primary cancer and chemoradiotherapy was given which was followed by adjuvant chemotherapy. In May 2006 patient was admitted with hematuria again. Magnetic resonance imaging had demonstrated Grade 3

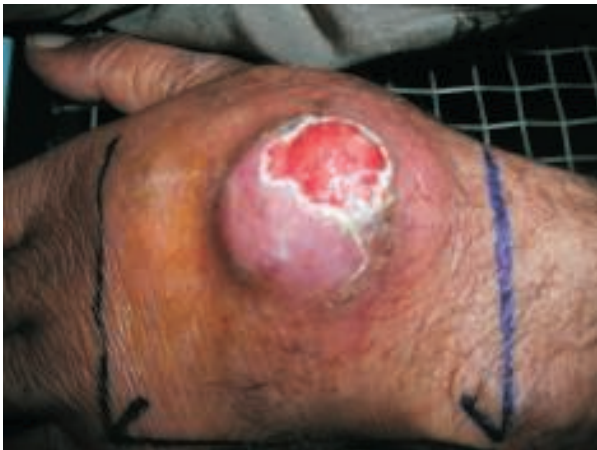hydronephrosis on left kidney, asymmetrical bladder wall thickening. Also in that time the lesion in the apical segment of right upper lobe of lung was thought as a third primary and aspiration biopsy was done to differentiate primary and metastasis but the histopathological examination had revealed metastasis of transitional cell carcinoma. Bone scintigraphy had demonstrated increased uptake in the left 3rd costal bone and parietooccipital region, the increased uptake in the left hand's joints was thought as reflex sympathetic dystrophy. After a transurethral resection gemcitabine-carboplatin was started and the patient had 4 cycles of that regimen (between 21 August 2006 and 7 December 2006, unless planned 6 cycles). Also he was administered palliative radiotherapy because of hematuria for a total dose of 30 Gy, delivered in 10 fractions to the pelvis. In February 2007 after a two month interval without treatment he was admitted with a growing lesion on the dorsum of hand. Punch biopsy confirmed the lesion to be metastatic carcinoma, histologically identical to the previously resected bladder cancer which has transitional epithelial cell islands with mild nuclear atypia (Picture 1, 2). Chemotherapy was started again as gemcitabine-carboplatine protocol. Owing to the lack of response to chemotherapy he presented to our clinic with a bleeding and painful lesion and local external beam radiation was administered to the lesion with a palliative intent for a total of 30 Gy, delivered in 10 fractions at May, 2007 (Picture 3). Even though the tumor size reduced slightly, the bleeding and the pain was terminated with radiotherapy. After a three months follow up, without a problem due to the lesion on dorsum of hand he died at August 28th, 2007 because of a cardiopulmonary arrest.



Picture 1. Tumoral transitional epithelial islands (HE 200X).



Picture 2. Mild nuclear atypia in transitional epithelial islands (HE400X).



Picture 3. The lesion on dorsum of hand.

Discussion

Cutaneous metastasis is a relatively uncommon manifestation of visceral malignancies and most often occurs late in the course of disease but also may be the presenting sign of underlying cancer. The tumor most commonly found to metastasize to skin is generally considered to be breast cancer (1). Cutaneous metastases from urologic tumors are uncommon and occur in 1% of patients with advanced disease, urologic skin metastases are most common from renal tumors, followed by those of the bladder and then prostate (2). Patients can present de novo with cutaneous metastases from TCC, or such metastases might arise after a prior diagnosis and treatment of TCC, as in our case. Occurrence of cutaneous metastases is not always associated with muscle-invasive or advanced

TCC, given that such metastases have also been described in patients with superficial TCC (2-4). Also it might be caused by iatrogenic implantation, but there are a limited number of previously reported cases of transitional cell carcinoma with cutaneous metastasis caused by iatrogenic implantations (5). Cutaneous metastasis is generally accepted as the late manifestation of systemic spread; however can be observed relatively early and as extensive skin metastasis (6). Wide local excision of the cutaneous lesion is the first line of management in these patients and is both diagnostic and potentially curative. This is followed by combination chemotherapy (7). Radiotherapy can also be given for the treatment of skin metastases. Some authors conclude that radiotherapy without excision of skin nodule might be the recommended palliative treatment (3, 8). Kubota et al. (9) have also used electrical pulses delivered to the tumor nodules along with intralesional bleomycin, with effective histological resolution of tumor in one patient. Regardless of the stage of the primary TCC, the prognosis after the appearance of cutaneous metastases is generally poor, with a median disease-specific survival of less than 12 months from diagnosis of the lesions. There are only a few reports mentioned the use of local radiotherapy in conjunction with or after failure of systemic chemotherapy, but it might be a viable option, as demonstrated in our patient.

Acknowledgement

The authors thank Prof. Dr. Selim Erekul, Erekul Pathology Laboratories, Ankara, Turkey for his expert histopathological evaluation.

References

1. Krathen RA, Orengo IF, Rosen T. Cutaneous metastasis: a meta-analysis of data. *South Med J* 2003; 96: 164-167.
2. Mueller TJ, Wu H, Greenberg RE, et al. Cutaneous metastases from genitourinary malignancies. *Urology* 2004; 63: 1021-1026.
3. Block CA, Dahmouh L, Konety BR. Cutaneous metastases from transitional cell carcinoma of the bladder. *Urology* 2006; 67: 846. e15-7.
4. Chitale SV, Morrow DR, Patel R, Gaches CG, Ball RY. Cutaneous metastases from transitional cell carcinomas of the bladder and renal pelvis. *Br J Urol* 1997; 79: 292-293.
5. Miyamoto T, Ikehara A, Araki M, Akaeda T, Mihara M. Cutaneous metastatic carcinoma of the penis: suspected metastasis implantation from a bladder tumor. *J Urol* 2000; 163: 1519.
6. Akman Y, Cam K, Kavak A, Alper M. Extensive cutaneous metastasis of transitional cell carcinoma of the bladder. *Int J Urol* 2003; 10: 103-104.
7. Gowardhan B, Mathers ME, Feggetter JG. Twenty-three years of disease-free survival following cutaneous metastasis from a primary bladder transitional cell carcinoma. *Int J Urol* 2004; 11: 1031-1032.
8. Rebelakos A, Manthopoulos A, Hadjissotiriou GG. Unusual metastasis of bladder cancer. *Br J Urol* 1989; 64: 198.
9. Kubota Y, Mir LM, Nakada T, Sasagawa I, Suzuki H, Aoyama N. Successful treatment of metastatic skin lesions with electrochemotherapy. *J Urol* 1998; 160: 1426.