

A Case of Synchronous Renal Cell Carcinoma, Metastatic Renal Cell Carcinoma and Non-Hodgkin's Lymphoma Diagnosed by Fine Needle Aspiration Biopsy

Senkron Böbrek Hücreli Karsinom, İnce İğne Aspirasyon Biyopsi Tanılı Metastatik Böbrek Hücreli Karsinom ve Non-Hodgkin Lenfoma

Demet Etit

Specialist, M.D.
Department of Patology
Izmir Tepecik Training and Research Hospital
demetetit@yahoo.com

Deniz Altinel

Specialist, M.D.
Department of Patology
Izmir Tepecik Training and Research Hospital
denizaltinel@gmail.com

Sadi Bener

Specialist, M.D.
Department of Patology
Izmir Tepecik Training and Research Hospital

Nezahat Erdogan

Specialist, M.D.
Department of Patology
Izmir Tepecik Training and Research Hospital

Abstract

Fine needle aspiration biopsy is a widely used diagnostic method especially in subcutaneous masses and in deep organ lesions. In this report while we emphasized the importance of fine needle aspiration cytology in pathology practice as an easy applicable method, we present a case with two different tumors: non-Hodgkin's lymphoma and renal cell carcinoma which was diagnosed by fine needle aspiration cytology.

Key words: **Renal cell carcinoma; Fine-needle aspiration biopsy; Non-Hodgkin Lymphoma.**

Özet

İnce iğne aspirasyon biyopsisi (İİAB), özellikle subkutan kitlelerin ve derin organ lezyonlarının tanısında yaygın kullanılan bir metoddur. Bu olgu sunumunda, bir taraftan İİAB'nin patoloji pratiğinde kolay uygulanabilir bir yöntem olduğu vurgulanırken bir taraftan da İİAB ile Non-Hodkin Lenfoma ve böbrek hücreli tümör olarak 2 farklı tümör tanısı almış olgu bildirilmektedir.

Anahtar kelimeler: **Böbrek Hücreli Karsinom; İnce-İğne Biyopsisi; Non-Hodgkin Lenfoma.**

The present study was presented at the XXXIth European Congress of Cytology, 2-5 October, 2005, Paris, France.

Submitted : April 19, 2009
Revised : October 17, 2010
Accepted : January 14, 2011

Corresponding Author:

Uzman Dr. Deniz Altinel
Tepecik Eğitim ve Araştırma Hastanesi
Patoloji Bölümü
(35100)- İzmir, Turkey.

Phone : +90 - 505 3913181
e-mail : denizaltinel@gmail.com

Introduction

Secondary malignant neoplasms are increasingly being observed in cancer patients who have lymphomas and renal cell carcinoma (1). Fine needle aspiration biopsy (FNAB) is widely used in investigating the nature of lymph nodes and in diagnosing renal cell carcinomas (2).

We diagnosed a case with a metastatic renal cell carcinoma on the surface of the right clavicle, another non-Hodgkin's lymphoma, in the left cervical region and renal cell carcinoma in the left kidney using fine needle aspiration cytology. This rare condition in cytology practise is being presented in this report.

Case report

A 38 year old male patient complained with a mass in the right clavicular region fixed to the clavicle with a diameter of 6 cm, and the other mass in the left cervical region with a diameter of 5 cm. A magnetic resonance scan and pelvic ultrasonography showed one more mass in the left kidney with a diameter of 6cm. All lesions were aspirated by fine -22 gauges- needle. Some slides were fixated in 95% ethylalcohol for Hematoxylin Eosin and Papanicolaou stains, others were air dried for a Giemsa stain. The aspirates from the cervical region were hypercellular within a hemorrhagic background. The smears were composed of round lymphoid cells with a small rim of cytoplasm. The nuclei were somewhat larger than that of mature lymphoid cells and the chromatin pattern was

irregular and clumped. The aspirates from the clavicular region were also hypercellular. In the smears of this region, we saw completely different types of cells. We observed the cells with finely vacuolated abundant clear cytoplasm, ranging from medium to large sized nuclei with prominent nucleoli, with low nuclear/cytoplasmic ratio. The cells were either isolated or in small clustered groups (Fig. 1). In the slides of the left kidney, a fine needle aspiration biopsy was taken under ultrasound guidance after which we observed cells as we saw in the clavicular region. The aspirates from the kidney were highly cellular. The cells had vacuolated cytoplasm, large and small nuclei with prominent nucleoli. Besides those neoplastic clear cells, small blood vessels were seen in the background. With all these findings, the cervical region cytology was reported as 'malignant', 'probable non-Hodgkin's lymphoma, the clavicular region aspirates diagnosed as 'malignant', 'could be renal cell carcinoma metastasized' and the left kidney's fine needle aspiration cytology was reported as 'malignant', 'renal cell carcinoma'. Then the patient was scheduled for an excisional biopsy of the cervical mass after which the surgeons planned a left nephrectomy. The cervical biopsy was confirmed as non-Hodgkin's Lymphoma, small lymphocytic lymphoma (Fig. 2). The surgical specimen of the nephrectomy was diagnosed as renal cell carcinoma. Immunohistochemically while CD5 was diffuse positive in the lymph node biopsy; EMA, vimentin and EMA showed strong positivity in the RCC.

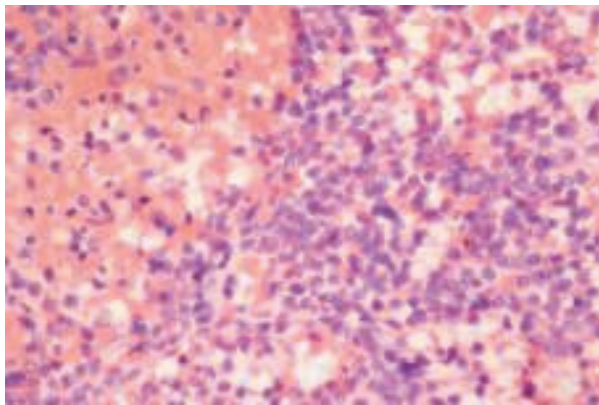


Figure 1. Cells with abundant clear cytoplasm round to oval nuclei from the supraclavicular region. (H&E X20)

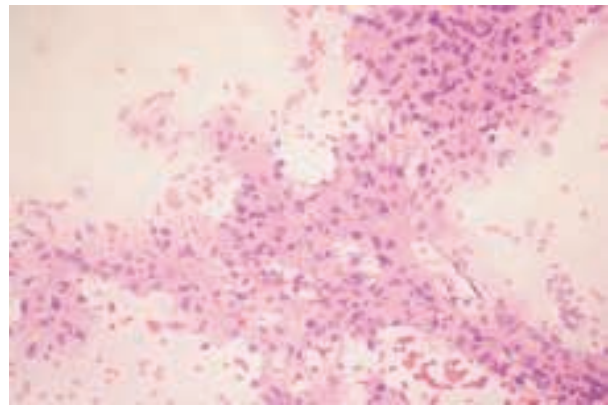


Figure 2. Diffuse small lymphocytic cells in the lymph node. (H&E X40)

Discussion

The most effective method of sampling renal lesions is performed by fine needle aspiration biopsy (2). The sensitivity of FNA's has been shown to reach 92.5% (3). Fine needle aspiration of the kidney is best accomplished under radiological imaging guidance for accuracy of needle placement. Ultrasonography is one of the methods that can be used for guidance. The lesion that was shown in the left kidney in our case was aspirated under ultrasonographic guidance. The aspirates were cellular containing with abundant clear cytoplasm with a low nuclear/cytoplasmic ratio. Similar types of cells were shown in the clavicular aspirates. Both lesions were identified as renal cell carcinoma.

Enlarged lymph nodes were the first organs to be biopsied by fine needle aspiration. Today, they are one of the most frequently sampled tissues. Much effort has been spent on the diagnosis of malignant lymphomas by FNA, attempts which have until recently been only partially successful. If the aspirate is composed of only one cell type, a confident diagnosis of non-Hodgkin's lymphoma can be made. At present no system of classification has been constructed for aspiration cytology (2). That's why we generally suggest to patients that they have an excisional biopsy if we suspect non-Hodgkin's lymphoma. By doing this, the classification of the disease and immunoprofiling are able to be done easier.

Carcinomatous metastases in the skeleton are mainly derived from the breast, kidney, lung, prostate and liver. The cytologic features in skeletal metastases are the same as those of the primary tumors (2). We first saw the clavicular lesion aspirates which had cytologic features, reminiscent of renal cell carcinoma, particularly with regard to clear cytoplasmic features.

The immunohistochemical work-up also supported the two different synchronous malignancies by using renal cell carcinoma and non-Hodgkin's lymphoma markers; such as CD5, vimentin and EMA.

If the incidence of co-occurrence of renal cell carcinoma and non-Hodgkin's lymphoma proves to be higher than expected in the general population, this will be controversial. According to Rabbani and Russo there is no increased risk of non-Hodgkin's lymphoma after renal cell carcinoma or vice-versa (4). Anderson et al and Nishikobo et al have reported this increase in the general population (5, 6). We think it needs several more studies.

In this report, we want to emphasize the importance of FNAB in routine pathology practise. We think FNAB is the gold standard diagnostic method even in these kinds of rare cases. The cases can be concluded diagnostically as soon as possible by FNAB, even in complicated ones. FNAB should be used as a first step diagnostic method in reachable masses.

References

1. Tihan T, Filippa DA. Coexistence of renal cell carcinoma and malignant lymphoma. A causal relationship or coincidental occurrence? *Cancer*. 1996; 77:2325-2331.
2. Mc Kee G. The kidney and retroperitoneal tissues. In: Gray W, Mc Kee G, editors. *Diagnostic Cytopathology*, 2nd edition. London: Churchill Livingstone; 2003. p.449-470.
3. Zardawi IM. Renal fine needle aspiration cytology. *Acta Cytol* 1999; 43: 184-190.
4. Anderson CM, Puzstai L, Palmer JL, Cabanillas F, Ellerhorst JA. Coincident renal cell carcinoma and nonHodgkin's lymphoma: the M. D. Anderson experience and review of the literature. *J Urol* 1998; 159: 714-717.
5. Rabbani F, Russo P. Lack of association between renal cell carcinoma and non-Hodgkin's lymphoma. *Urology* 1999;54: 28-33.
6. Nishikubo CY, Kunkel LA, Figlin R, et al. An association between renal cell carcinoma and lymphoid malignancies. A case series of eight patients. *Cancer* 1996; 78: 2421-2426.