

# Parotis Bezinin Multifokal Nodüler Onkostik Hiperplazisi

## Multifocal Nodular Oncocytic Hyperplasia of the Parotid Gland

### İbrahim Metin Çirış

Assist. Prof. M.D.  
Department of Pathology  
Süleyman Demirel University  
metin@med.sdu.edu.tr

### Şirin Başpınar

Specialist, M.D.  
Department of Pathology  
Isparta Doğum ve Çocuk Bakımevi

### Mustafa Asım Aydın

Assoc. Prof. M.D.  
Department of Plastic Surgery  
Süleyman Demirel University

### Birgül Aydoğan

M.D.  
Department of Pathology  
Süleyman Demirel University

### Nilgün Kapucuoğlu

Assoc. Prof. M.D.  
Department of Pathology  
Süleyman Demirel University  
kapucuoğlu@gmail.com

*The present study was presented at the XIXth National Pathology Congress, 25-29, October, 2009, Antalya, Turkey.*

Submitted : August 20, 2008  
Revised : October 26, 2009  
Accepted : May 04, 2011

#### Corresponding Author:

Yard. Doç. Dr. İbrahim Metin Çirış  
Süleyman Demirel Üniversitesi Tıp Fakültesi,  
Patoloji Anabilim Dalı,  
(32260) Isparta - Turkey

Phone : +90 - 2462112934  
e-mail : metin@med.sdu.edu.tr

#### Abstract

Proliferations of oncocytes in salivary glands are categorized as oncocytic metaplasia, nodular or diffuse hyperplasia, oncocytoma, and oncocytic carcinoma. Multifocal nodular oncocytic hyperplasia of the parotid gland represents an extremely rare lesion that refers to tumor-like nodules that show hyperplasia of metaplastic oncocytes. In this article, we present a case of a multifocal nodular oncocytic hyperplasia in a 60-year old woman with a 7-months history of gradually increasing diffuse swelling of the left parotid gland. The histopathological features and differential diagnosis of this rare lesion is described and discussed.

Keywords: **Oncocytes; Metaplasia; Parotid Gland.**

#### Özet

Tükürük bezlerinde onkositlerin proliferasyonu onkostik metaplazi, nodüler veya diffüz hiperplazi, onkositoma ve onkostik karsinom olarak sınıflanmaktadır. Parotis bezinin multifokal nodüler onkostik hiperplazisi metaplastik onkositlerin hiperplazisi sonucu oluşan tümör benzeri nodül yapıları ile karakterize oldukça nadir görülen bir lezyondur. Bu makalede sol parotis bezinde 7 aydır gittikçe büyüyen diffüz şişlik öyküsü olan 60 yaşında kadın hastada multifokal nodüler onkostik hiperplazi olgusu sunuldu. Bu nadir lezyonun histopatolojik özellikleri ve ayırıcı tanısı tanımlandı ve tartışıldı.

Anahtar Kelimeler: **Onkositler; Metaplazi; Parotis Bezi.**

## Introduction

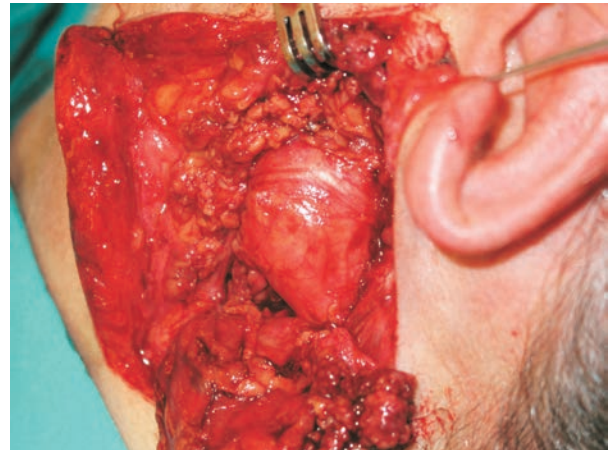Oncocytes represent a special class of transformed epithelial cells that arise principally from glandular and secretory epithelia, and they are characterized by their large size and abundant, finely granular eosinophilic cytoplasm which is rich in mitochondrias (1). Ultrastructural studies of oncocytes reveal marked mitochondrial hyperplasia with pleomorphism and a paucity of other organelles (2). Oncocytic neoplasms result from metabolically altered cells that accumulate abundant mitochondria within their cytoplasm by oncocytic metaplasia. These neoplasms rarely affect the major salivary glands, accounting less than 1% of all salivary gland tumours (3, 4). The World Health Organization's histologic classification of salivary gland tumors divides parotid oncocytic neoplasms into 3 categories: oncocytosis, oncocytoma, and oncocytic carcinoma (5).

Oncocytosis is the accumulation and proliferation of oncocytes in salivary glands in nodular or diffuse pattern (6). Multifocal nodular oncocytic hyperplasia (MNOH) in the salivary glands is an extremely rare condition (7). This report concerns a very rare case of a MNOH involving the parotid gland and occurring in a 60-year old woman. The histopathological features and differential diagnosis of this rare lesion is presented and discussed.

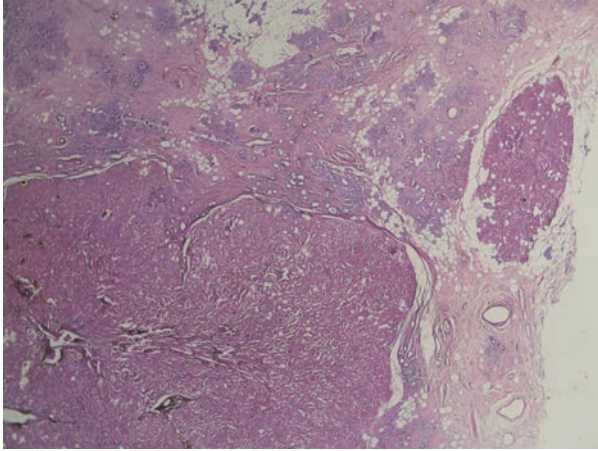
## Case report

A 60-year-old woman presented to our hospital with a left pre-auricular painless mass, which had appeared 7 months earlier and had been growing ever. The findings on physical examination included a wellcircumscribed firm mass located behind the angle of the mandible. The mass was 3x5 cm palpable, mobile, and not adherent to the skin. There were no palpable cervical lymph nodes, and no pathological changes were detected clinically in the other parotid gland. Preoperative sonography and magnetic resonance imaging clearly showed that the tumor was located deep in the left parotid gland. Subsequently the lesion was surgically excised through a left superficial and deep parotidectomy with facial nerve preservation (Picture 1). Macroscopically the surgical specimen consisted of two separate fragments of tissue which were identified as superficial and deep lobes of parotid gland measured totally 5x4.5x3cm. Multiple cut surfaces revealed a well demarcated nodular lesion measured 3.1x 2.9x1.5 cm and comprised around %60 of the specimen. The lesion had variegated yellowbrown nodular areas intermingled with few cystic spaces. Microscopically

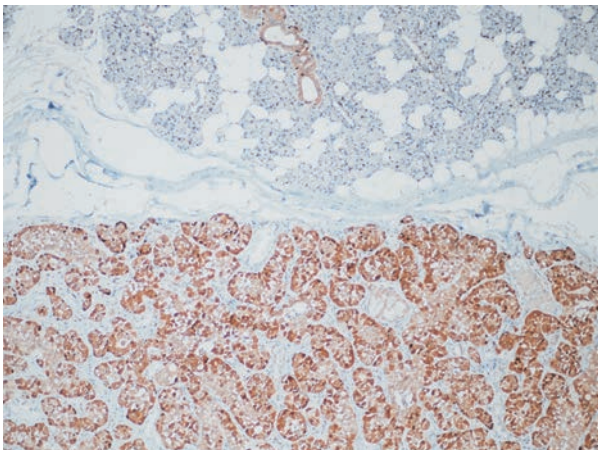
multiple nodules of large polyhedral cells with intensely eosinophilic granular cytoplasm and centrally placed pyknotic nucleus arranged in tubuloacinar structures were identified (Picture 2). There were sebaceous metaplasias in some ducts. The cystic spaces were lined by oncocytic cells. The residual parotid gland showed scattered dilated ducts containing intraluminal calculi and rare foci of mild chronic inflammatory infiltrates with a predominantly periductular distribution. In other areas acinar atrophy, and stromal fibrosis were seen. No necrosis, mitotic activity, cellular atypia or invasion was identified. Immunohistochemically the oncocytes were diffusely positive for CK7 (Picture 3) and ductal epithelium showed positive nuclear p63 immunostaining. In the light of histopathological and immunohistochemical findings the diagnosis was MNOH of the parotid gland. The patient's course was uneventful over the following 10 months.



**Picture 1.** Enlarged deep lobe of the left parotid gland with an intact facial nerve.



**Picture 2.** Nodules of large polyhedral cells with eosinophilic granular cytoplasm and centrally placed pyknotic nucleus arranged in tubulo-acinar structures (HEX40).



**Picture 3.** Oncocytes showing diffuse positive immunostaining with CK7 (Diaminobenzene X100).

### **Discussion**

Oncocytes were first described as eosinophilic, granular, swollen cells by Shaffer in 1897, but later named and more fully characterized by Hamperl in 1931 (8). Hamperl found oncocytes in salivary and mucous glands of the larynx, trachea, bronchi, esophagus, lacrimal glands, nasal mucous membrane, thyroid, parathyroid, pancreas, hypophysis, testicles, fallopian tubes, liver and stomach (1, 8). He considered oncocytes to differ from other epithelial cells by their excessive proliferation of mitochondria. Because of their size and characteristic abundant acidophilic cytoplasm and altered DNA, oncocytic cells may be classified as somatic mutants (8). Oncocytes are large polyhedral cells with abundant

granular cytoplasm that varies from strongly acidophilic to chromophobic. The cytoplasm shows granular positivity with phosphotungstic acid hematoxylin (PTAH) and anti-mitochondrial antibody, and large numbers of mitochondria are seen on ultrastructural examination (2,8).

Their number in the normal salivary gland increases with age, It has been demonstrated that oncocytic foci are rare before age 50, and are almost universal after age 70 (8). Oncocytes, have been once thought to arise from a degenerative process are now thought to result from redifferentiation of epithelial cells which develop an increased but unbalanced metabolism. This is due to an acquired enzymatic defect in the mitochondrial oxidative process (9). Oncocytes occur in some pathological conditions of the salivary glands including oncocytosis, oncocytoma, and oncocytic carcinoma (5).

MNOH is a tumor-like lesion that occurs predominantly in the parotid gland. It is mainly diagnosed in women and in the sixth decade with swelling and tenderness of the parotid region of 4 months to 25 years duration (7). It comprises nodules of oncocytes, with round, centrally located nuclei, eosinophilic, granular cytoplasm and conspicuous cell borders. The nodules may appear to engulf normal acinar tissue, giving a false impression of invasion. In diffuse oncocytic hyperplasia nearly the entire gland is replaced by oncocytes (10). Oncocytoma, the most common morphology of oncocytic neoplasia, comprises a well-demarcated mass with a solid, trabecular, or tubular configuration of monotonous sheets of oncocytes (10-12). A benign clinical course is the rule, but literature review yields an approximate 20% recurrence rate due to occult multifocality or incomplete excision (11, 12). In addition, there are reports of malignant transformation of oncocytoma to oncocytic carcinoma (13).

The distinction between an oncocytic hyperplasia and an oncocytoma can be difficult histopathologically, especially in glands with multiple nodules. Oncocytoma can be distinguished from oncocytosis because it is well defined, solitary and commonly encapsulated. In contrast oncocytosis is multifocal and does not disrupt nodular architecture of the glandular parenchyma. The presence of focal, ductal and acinar oncocytic metaplasia in other parts of the gland, in addition to presence of normal acini at the periphery of the large nodules in nodular oncocytic hyperplasia may be useful in distinguishing this lesion from true oncocytoma (5,10,12). Criteria for the diagnosis of malignancy in salivary oncocytic tumors include: distant

metastasis; local lymph node metastasis; perineural, vascular or lymphatic invasion; frequent mitoses and cellular pleomorphism with extensive invasion and destruction of adjacent structures (8). Our case had no regional or distant lymph node metastasis clinically or radiologically.

Sebaceous glands or isolated sebaceous cells are normal findings in salivary gland tissue. Sebaceous metaplasia has been noted in pleomorphic adenoma, oncocytoma, sialoblastoma, Warthin tumor, and oncocytic lipoadenoma (14). In our case there were sebaceous metaplasias in some ducts, surrounded by small lymphoid aggregates.

In the present case nodules of oncocytes with intervening ducts, acini and fat in a background of morphologically normal serous acini were present. The normal tubulo-aciner structure is preserved at the periphery of the large nodules, and the lobular arrangement of the parotid gland was maintained. The nodules were consisted of large polyhedral cells with eosinophilic granular cytoplasm and central pyknotic nucleus characteristic of oncocytic change. There was no evidence of encapsulation, mitotic activity, cellular pleomorphism, invasion or destruction of adjacent structures.

In conclusion, MNOH of the salivary glands is a benign disorder of putative hyperplastic pathogenesis that follows a benign course. Although this lesion is very rare, it should be considered in the differential diagnosis of oncocytic neoplasms of salivary glands.

#### References

- 1.Hamperl H. Benign and malignant oncocytoma. *Cancer* 1962; 15: 1019–1027.
- 2.Johns ME, Regezi JA, Batsakis JG. Oncocytic neoplasms of salivary glands: an ultrastructural study. *Laryngoscope* 1977; 87(6): 862-871.
- 3.Seifert G. Tumour-like lesions of the salivary glands: the new WHO classification. *Pathol Res Pract* 1992; 188(7): 836-846.
- 4.Brandwein MS, Huvos AG. Oncocytic tumors of major salivary glands: a study of 68 cases with follow-up of 44 patients. *Am J Surg Pathol* 1991; 15(6):514-28.
- 5.Hanna EY, Suen JY. Neoplasms of the salivary glands. In: Cummings C, Freidrickson J, Harker, editors. *Otolaryngology–Head and Neck Surgery*. St Louis: Mosby; 1998. p.1256.
- 6.Becker K, Donath K, Seifert G. Diffuse oncocytosis of the parotid gland. Definition and differential diagnosis. (German) *Laryngol Rhinol Otol* 1982; 61(12): 691–701.
- 7.Strassburger S, Hyckel P, Kosmehl H. Multifocal oncocytic adenomatous hyperplasia of the parotid gland. A case report. *Int J Oral Maxillofac Surg* 1999; 28(6): 457–458.
- 8.Gray SR, Cornog JL Jr, Seo IS. Oncocytic neoplasms of salivary glands: a report of fifteen cases including two malignant oncocytomas. *Cancer* 1976; 38(3):1306-17.
- 9.Smith RA, Ord MJ. Mitochondrial form and function relationships in vivo: their potential in toxicology and pathology. *Int Rev Cytol* 1983; 83: 63-134.
- 10.Palmer TJ, Gleeson MJ, Eveson JW, Cawson RA. Oncocytic adenomas and oncocytic hyperplasia of salivary glands: a clinicopathological study of 26 cases. *Histopathology*. 1990; 16(5):487-493.
- 11.Blanck C, Eneroth CM, Jakobsson PA. Oncocytoma of the parotid gland: neoplasm or nodular hyperplasia? *Cancer* 1970; 25(4): 919-925.
- 12.Alberty J, August C, Stoll W. Oncocytic neoplasms of the parotid gland. Differential diagnosis, clinical course and review of the literature (German). *HNO* 2001; 49(2): 109–117.
- 13.Laurian N, Zohar Y, Kende L. Malignant oncocytoma *J Laryngol Otol* 1977; 91(9):805-808.
- 14.Klieb HB, Perez-Ordoñez B. Oncocytic lipoadenoma of the parotid gland with sebaceous differentiation. Study of its keratin profile. *Virchows Arch* 2006; 449(6): 722-725.