

# Abscess Drainage by a Retroperitoneoscopic Technique in Emphysematous Pyelonephritis Treatment

## *Amfizematöz Piyelonefrit Tedavisinde Retroperitoneoskopik Apse Drenaj*

Abdullah Demirtaş, Mustafa Sofikerim, Mehmet Caniklioğlu, Nurettin Şahin, Erol Erşekerici, Oğuz Ekmekçiöğlü, İbrahim Gülmez

CASE REPORT  
OLGU SUNUMU

ABSTRACT  
ÖZET

A 60-year-old man had experienced bilateral flank pain for two months. Bilateral hydronephrosis, bilateral kidney stones and a right distal ureteral stone were determined. He was diabetic. A JJ stent was placed into the right renal unit and emphysematous pyelonephritis consequently emerged one week later. Right renal abscess drainage was performed by laparoscopy. Based on computed tomography scans six weeks later, the abscess had completely disappeared. To our knowledge, this is the first report of an emphysematous pyelonephritis case being treated by performing laparoscopic drainage along with renal capsule incision. Laparoscopic drainage and renal capsule incision may be chosen as a minimally invasive procedure for select patients.

**Key words:** Pyelonephritis, laparoscop, psoas abscess

Altmış yaşında erkek hasta 2 aydır olan iki taraflı böğür ağrısı ile başvurdu. İki taraflı hidronefroz, iki taraflı böbrek böbrek taşları ve sağ üreter distal uçta taş tespit edildi. Hasta diabetikti. Sağ böbreğe jj stent yerleştirildikten bir hafta sonra hastada amfizematöz piyelonefrit gelişti. Sağ renal apse laparoskopik olarak drene edildi. Altı hafta sonra çekilen bilgisayarlı tomografi kesitlerinde absenin tamamen kaybolduğu izlendi. Bildiğimiz kadarıyla bu yayın, laparoskopik renal kapsül insizyonu ile absenin drene edilerek tedavisi yapılan ilk amfizematöz piyelonefritli olgu sunumudur. Laparoskopik drenaj ve renal kapsül insizyonu, uygun hastalarda minimal invaziv bir prosedür olarak tercih edilebilir.

**Anahtar kelimeler:** Piyelonefrit, laparoskop, psoas apsisi

## Introduction

Emphysematous pyelonephritis is an acute suppurative infection in diabetic patients that is characterised by intense gas formation. It is life-threatening and more frequent in women. The infectious agents are usually *Escherichia coli* and *Klebsiella pneumoniae*, and sepsis is the most frightening complication of the disease. Ureteral obstruction is common but does not always occur. Diabetes mellitus alone is sufficient as a risk factor, whether or not a patient is using insulin. Immediate nephrectomy or systemic antibiotic therapy with open surgical drainage is the traditional treatment procedure in this emergency condition.

However, there are a few reports in which only medical treatment and/or percutaneous drainage or JJ stent application were successful treatments. To our knowledge, this is the first report of an emphysematous pyelonephritis case being treated by performing laparoscopic drainage along with renal capsule incision. In this case report, kidney-sparing treatment in place of nephrectomy and its results are discussed along with the literature.

## Case Report

A 60-year-old man who had bilateral flank pain for two months presented at our clinic. Bilateral hydronephrosis and multiple renal stones ( $\leq 1.5$  cm) in the calices of both kidneys and a 1 cm stone in the right distal ureter were diagnosed by ultrasonography (US). There was uncontrolled diabetes mellitus for two years in his history. The serum creatinine level was 1.8 mg/dL. A JJ stent was placed in the right ureter. In this way, we aimed to provide urine drainage.

A week later, the patient sought treatment at the emergency department. He was in a septic state, and an abscess and gas formation originating from his right kidney and perirenal tissue and extending bilaterally to the gluteal zones were observed on computed tomography (CT) sections (Figure 1). He was hospitalised with a diagnosis of emphysematous pyelonephritis. His serum creatinine level rose to 2.5 mg/dL. Meropenem treatment was given at the dose of 2x1 g parenterally, based on his kidney function. A percutaneous nephrostomy (PCN) catheter was placed in his right kidney and the JJ stent was removed. On the 2,3-dimercaptosuccinic acid (DMSA) scan, total uptake was 4.8%; right kidney function was 52.7% and left kidney function was 47.3%.

Cystoscopy was performed under anaesthesia, his ureter stone will be passed into and extracted from his bladder. Then, retroperitoneoscopic dissection was performed. The abscess (1000 mL) was drained by aspiration from the retroperitoneal space, and five vertical incisions were made in the renal capsule. Bilateral gluteal abscesses were

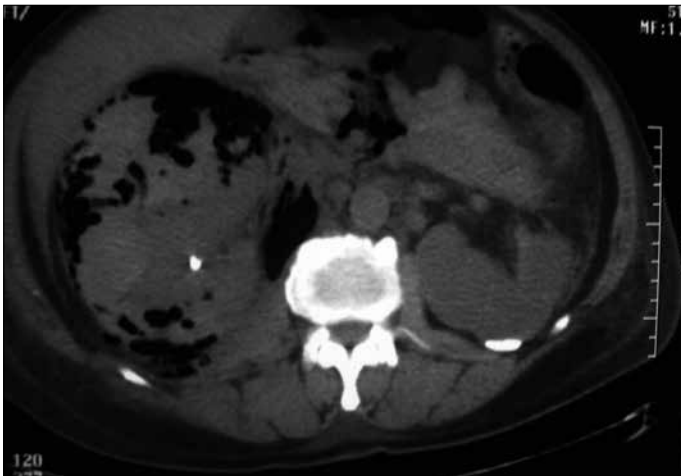
Department of Urology,  
Faculty of Medicine,  
Erciyes University,  
Kayseri, Turkey

Submitted/Geliş Tarihi  
19.11.2009

Accepted/Kabul Tarihi  
17.04.2012

Correspondance/Yazışma  
Dr. Abdullah Demirtaş  
Department of Urology,  
Faculty of Medicine,  
Erciyes University,  
38039 Kayseri, Turkey  
Phone: +90 532 509 44 94  
e.mail: mesane@gmail.com

©Copyright 2012  
by Erciyes University School of  
Medicine - Available on-line at  
www.erciyesmedicaljournal.com  
@Telif Hakkı 2012  
Erciyes Üniversitesi Tıp Fakültesi  
Makale metnine  
www.erciyesmedicaljournal.com  
web sayfasından ulaşılabilir.



**Figure 1.** View of emphysematous pyelonephritis in the right kidney causing intense gas formation and an abscess. The left kidney is atrophic and there is a JJ stent in the right kidney

drained percutaneously by orthopedists, and two drainage catheters were placed, one for each gluteal zone. *Klebsiella pneumoniae* was cultured from the abscess ( $10^5$  CFU/mL).

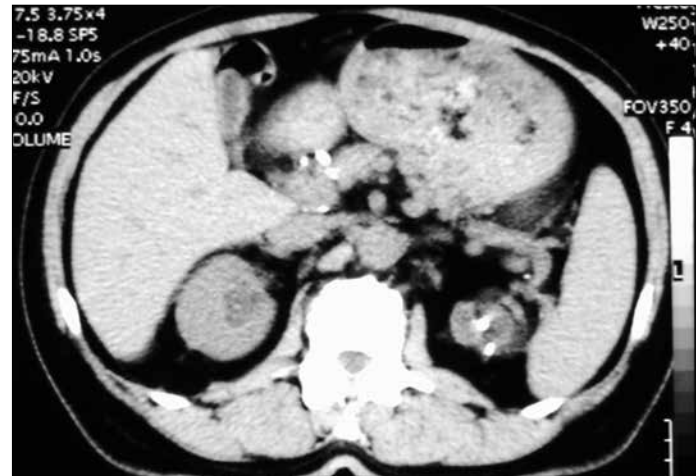The patient continued with antibiotic therapy and drainage catheters for six months; 5000 mL of pus were drained in total. The drainage catheters were removed upon complete resolution of disease as seen by CT and the cessation of drainage (Figure 2). At the 18<sup>th</sup> post-operative month, a DMSA scan showed that total renal uptake was 21.5%; right kidney function was 65.4% and left kidney function was 34.6%. The serum creatinine level was 1.7 mg/dL. Based on 24 hours' urine collection analyses, the patient's glomerular filtration rate was 52 mL/min. The patient was diagnosed with stage 3 chronic renal insufficiency at the 18<sup>th</sup> post-operative month.

## Discussion

Emphysematous pyelonephritis is an acute suppurative infection of the renal parenchyma and perinephritic area and is characterised by intense gas formation in these locations. It occurs more frequently in women than in men. Diabetes mellitus and obstructive uropathy are the most important predisposing factors (1). Emphysematous pyelonephritis is a surgical emergency. Most patients are septic, and fluid resuscitation and broad-spectrum antimicrobial therapy are essential. If the kidney is functioning, medical therapy can be considered. Nephrectomy is recommended for patients who do not improve after a few days of therapy. Although there are isolated case reports of retention of renal function after medical therapy combined with relief of obstruction, most patients require nephrectomy (2).

Recently, some cases were reported in which laparoscopic techniques were used as minimally invasive procedures in emphysematous pyelonephritis surgery for selected patients (3, 4). We are of the opinion that laparoscopic approaches offer advantages over open surgery in emphysematous pyelonephritis, because wound regeneration is often problematic in affected patients.

Conservative treatment is successful in a few cases. Huang et al. (5) performed percutaneous drainage (PCD) and used systemic antibiotics (6) reported a case which was treated by PCD.



**Figure 2.** View of the normal right kidney and perirenal zone after conservative treatment

Ku et al. (7) reported a diabetic emphysematous pyelonephritis patient with an atrophic kidney on the contralateral side who was treated by placing a JJ stent and using supportive treatment, thereby rescuing the patient from being anephric. In our case, emphysematous pyelonephritis occurred after a JJ stent had been placed into the right ureter. It should be kept in mind that serious complications may occur after surgical or invasive applications such as ureteral stent placement in diabetic patients with urinary obstruction.

There are limited number of cases in which patients are cured only with antibiotic therapy without nephrectomy, PCD or ureteral stent placement. These cases are usually in situations in which a patient risks being anephric (e.g., bilateral involvement or a solitary functioning kidney). Angulo et al. (8) reported curing a patient with bilateral involvement by antibiotic therapy alone; however, in a case with a solitary kidney when antibiotic therapy was insufficient, they performed PCN. Huang et al. (5) administered antibiotic treatment alone in five patients, two of whom died (mortality rate=40%). Our opinion is that patients should be followed closely and evaluations for additional surgical interventions are necessary when systemic antibiotic therapy is planned as the only emphysematous pyelonephritis treatment in selected patients.

In our case, kidney-sparing treatment was chosen because of impaired kidney function and widespread bilateral renal parenchymal damage. Further, wound regeneration is defective in emphysematous pyelonephritis because of diabetes mellitus, and intense infection and inflammation worsen the situation. For these reasons, laparoscopic drainage was chosen over open surgery. The existence of intense pus at the right retroperitoneum led to the decision to perform laparoscopic drainage, which is more effective than percutaneous drainage. We aimed to make abscess and gas drainage easier by making vertical renal capsular incisions. There was no problem with port healing.

To our knowledge, this is the first report of an emphysematous pyelonephritis case being treated by performing laparoscopic drainage along with renal capsule incision.

## Conclusion

Consequently, at experienced centres, laparoscopic drainage and renal capsule incision may be chosen as a minimally invasive pro-

cedure for select patients, such as those with only one kidney or a contralateral atrophic kidney and those with bilateral renal function under risk or low renal reserve.

#### Authors' contributions

Conceived and designed the study: IG, OE. Examination and follow-up of the patient: IG, AD, NS. Analysed the data: AD, MS. Wrote the paper: EE, MC. All authors read and approved the final manuscript.

#### Conflict of interest

No conflicts of interest were declared by the authors.

#### References

1. Cheng YT, Wang HP, Hsieh HH. Emphysematous pyelonephritis in a renal allograft: successful treatment with percutaneous drainage and nephrostomy. *Clin Transplant* 2001; 15(5): 364-7. [\[CrossRef\]](#)
2. Wein AJ, editor-in-chief; Kavoussi LR, Novic AC, Partin AW, Peters CA, editors. *Campbell-Walsh Urology*, 9th ed. Philadelphia, US: Saunders, Elsevier inc; 2007. p.265-87
3. Bauman N, Sabbagh R, Hanmiah R, Kapoor A. Laparoscopic nephrectomy for emphysematous pyelonephritis. *Can J Urol* 2005; 12(4): 2764-8.
4. Okochi H, Iiyama T, Kasahara K, Moriki T, Inoue K, Shuin T. Renal matrix stones in an emphysematous pyelonephritis. *Int J Urol* 2005; 12(11): 1001-4. [\[CrossRef\]](#)
5. Huang JJ, Tseng CC. Emphysematous pyelonephritis: clinicoradiological classification, management, prognosis, and pathogenesis. *Arch Intern Med* 2000; 160(6): 797-805. [\[CrossRef\]](#)
6. Hudson MA, Weyman PJ, van der Vliet AH, Catalona WJ. Emphysematous pyelonephritis: successful management by percutaneous drainage. *J Urol* 1986; 136(4): 884-6.
7. Ku JH, Kim ME, Lee NK, Park YH. Emphysematous pyelonephritis recovered by ureteral stenting in a functionally solitary kidney. *Urol Int* 2002; 69(4): 321-2. [\[CrossRef\]](#)
8. Angulo JC, Dehaini A, Escibano J, Sanchez-Chapado M. Successful conservative management of emphysematous pyelonephritis, bilateral or in a solitary kidney. *Scand J Urol Nephrol* 1997; 31(2): 193-7. [\[CrossRef\]](#)