



Subdural Empyema as a Result of Silent Otitis Media: Case Report

Sessiz Otitis Medya Sonucu Subdural Ampiyem: Olgu Sunumu

Mehmet Somdaş¹, Onur Sönmez², Celalettin Cihan³, Fatih Karasu², Ramazan Gündoğdu², Alperen Vural²

CASE REPORT
OLGU SUNUMU

ABSTRACT ÖZET

Silent otitis media is a progressive otogenic disease. This sub-clinical infectious disease affects the mucosal layers and bony structures of mastoid cells despite intact tympanic membranes. Although there is a significant decrease present in the incidence of the classical mastoiditis in the postantibiotic era, silent mastoiditis which develops as a result of insufficient or inefficient antibiotherapy for otitis media is still a life threatening entity. In this article, a patient with epidural and subdural empyema due to silent mastoiditis is presented. The patient underwent mastoidectomy. After mastoidectomy, the patient is disease free and under control. The aim of the article is to alert the physician about silent otitis media which might easily be misdiagnosed.

Key words: Mastoiditis, otitis media, subdural empyema

Sessiz otitis medya, ilerleyici otojenik bir hastalıktır. Bu subklinik enfeksiyöz hastalık timpanik zar normal olmasına rağmen mastoid kemik hücrelerini ve mukozalarını etkiler. Antibiyotik sonrası dönemde klasik mastoidit sıklığında ciddi bir düşüş mevcut olmakla birlikte, otitis medya için yetersiz veya etkisiz antibiyotik kullanımına bağlı gelişen sessiz mastoidit halen hayatı tehdit eden bir antitedir. Bu yazıda, sessiz mastoidite bağlı gelişen epidural ve subdural ampiyem olgusu sunulmaktadır. Hastaya mastoidektomi uygulanmıştır. Mastoidektomi sonrası olgu hastaliksız takiptedir. Bu yazının amacı, kolaylıkla gözden kaçırılacak olan sessiz otitis medyaya okuyucunun dikkatini çekmektir.

Anahtar kelimeler: Mastoidit, otitis medya, subdural ampiyem

¹Clinic of Otorhinolaryngology Research and Training Hospital, Kayseri, Turkey

²Department of Otorhinolaryngology Erciyes University, School of Medicine, Kayseri, Turkey

³Clinic of Otorhinolaryngology Research and Training Hospital, Aksaray, Turkey

Available Online Date
Çevrimiçi Yayın Tarihi
22.06.2012

Submitted / Geliş Tarihi
08.11.2010

Accepted/Kabul Tarihi
16.05.2012

Correspondance/Yazışma
Dr. Mehmet Somdaş
Department of Otorhinolaryngology Research and Training Hospital, Kayseri
38010 Kayseri, Turkey
Phone: 90 352 336 88 84-2069
e.mail:
somas@erciyes.edu.tr

This study was presented at the National Congress of Otolaryngology and Head-Neck Surgery, 28 October-1 November 2009 Antalya, Turkey.

©Telif Hakkı 2012
Erciyes Üniversitesi Tıp Fakültesi
Makale metnine
www.erciyesmedicaljournal.com
web sayfasından ulaşılabilir.
©Copyright 2012
by Erciyes University School of Medicine - Available on-line at
www.erciyesmedicaljournal.com

Introduction

The term "silent otitis media" was first used by Paparella et al. (1) in 1980 to describe ongoing infection and inflammation in the tympanic cavity and mastoid cells behind a healthy tympanic membrane. On the other hand, the term "masked or silent mastoiditis", which is accepted as a subtype of silent otitis media, is used to describe the infection that progresses with osteitis in the mastoid cavity despite a normal tympanic membrane. The clinical significance of silent mastoiditis was first drawn attention to in the USA during a Neisseria meningitis outbreak: The tympanic cavity and mastoid cells were the main sources of meningitis according to histological examinations carried out on autopsies of the children (2). Although clinical improvement has been observed in infection profiles, as a result of application of insufficient or inappropriate antibiotics in acute otitis media (AOM) cases, the bacteria cannot be eradicated from the tympanum and mastoid cavity. Histopathological changes such as inflammatory reaction in the mastoid mucosa, granulation tissue and osteitis has usually been observed with a decrease to some extent (2, 3).

Nowadays, due to an increase in the use of broad spectrum antibiotics and a decrease in classic mastoiditis incidence, silent mastoiditis may be life-threatening. Many children and adults may present with chronic intractably pathological tissue that can fill the middle ear cleft, including the mastoid, behind an intact membrane, and can cause complications not only in the middle ear and inner ear but in the cranium. In this article, a patient with hemiparesis due to epidural and subdural empyema who underwent mastoidectomy with a prediagnosis of silent mastoiditis is presented and this overlooked entity is discussed in the light of the literature to emphasize its significance.

Case Report

In January 2009, a 15-year-old female patient applied to the emergency department with the complaints of headache, nausea and vomiting, somnolence, weakness on the left side of the face and loss of strength in the left part of the body. According to the history of the patient, she had received antibiotic treatment due to pain in the right ear two months earlier and did not go to another clinic even though there was a feeling of fullness in the ear.

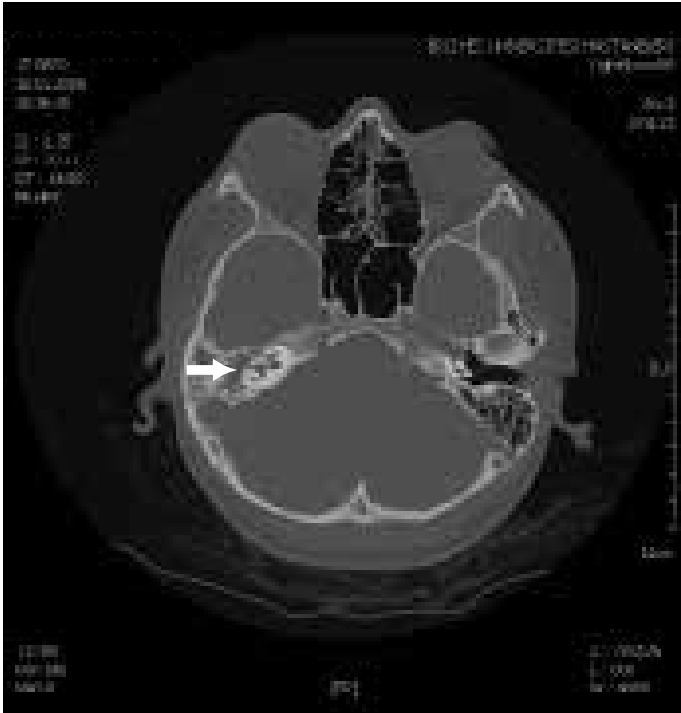


Figure 1. Preoperative temporal CT scan showing soft tissue in aditus (arrow)

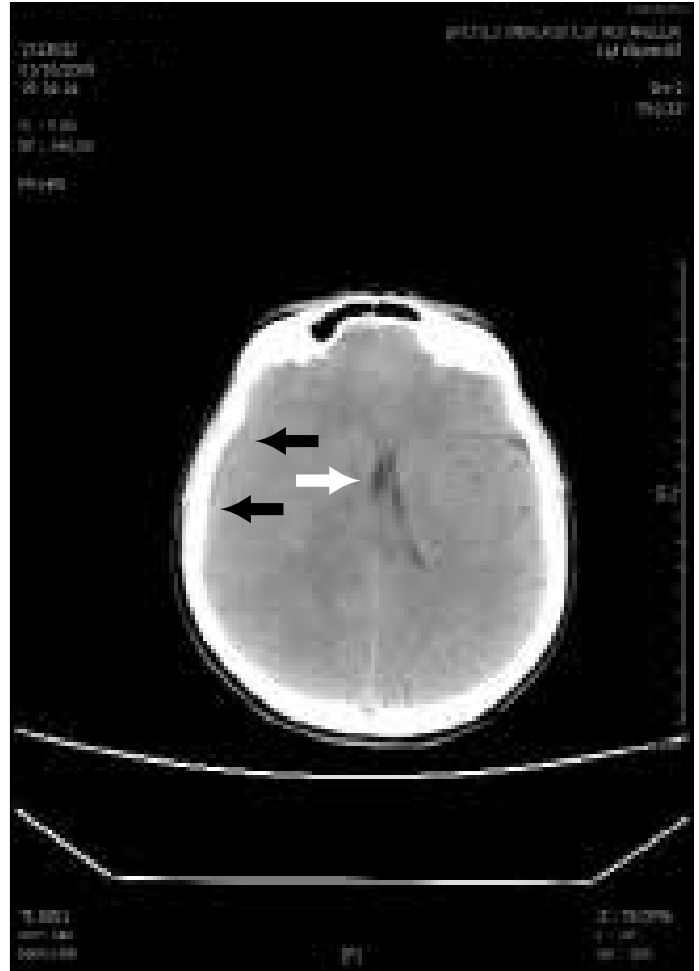

Figure 2. Preoperative cranial CT scan showing epidural empyema (black arrows) and midline shift (white arrow)

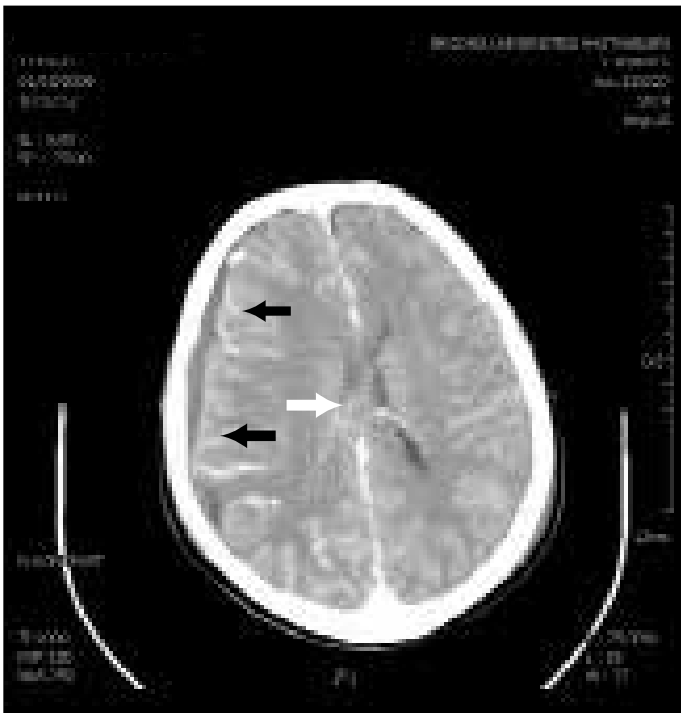


Figure 3. Cranial CT scan, midline shift (white arrow) and subdural empyema (black arrows), three days after initial surgery

No pathological findings were observed in anterior rhinoscopy, oral cavity examination or endoscopic nasopharynx and larynx examinations. Both external auditory canals and left tympanic membrane were observed to be normal in the otomicroscopic examination. The pars tensa of the right tympanic was seen to be normal,

the pars flaccida membrane, however, was matt. The Rinne test was bilaterally positive and the Weber test was dextrally lateralized. The patient was lethargic and had had a convulsion in the emergency service, therefore a pure tone audiometry test could not be applied. No pathologies concerning the vestibular system were observed. The body temperature of the patient was 38.3°C, and signs of meningeal irritation and lethargy were present. In addition, central facial paresis was observed on the left.

In the temporal computed tomography (CT), an expansive soft tissue density, which filled the epitympanum and the mastoid cells completely, was observed on the right (Figure 1). There was also an approximately 5-mm midline shift to the left due to the epidural empyema (Figure 2). The patient was consulted with the neurosurgery department because of the shift, hemiparesis and central facial paralysis but thought to be initially treated with broad spectrum antibiotic.

On the other hand, the soft tissue in the CT blocking the aditus (Figure 1) urged us to proceed to an immediate mastoidectomy, with the suspicion of a silent mastoiditis. A modified radical mastoidectomy was immediately carried out and granulation tissues were observed, filling the antrum and leading to osteitis in the epitympanum and tegmen mastoideum. Tympanic cavity mucosa was

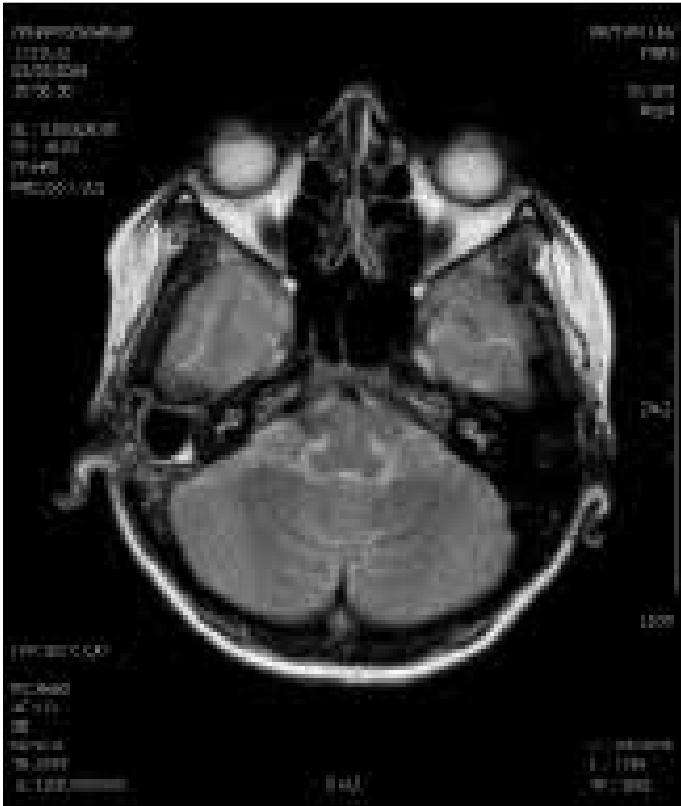


Figure 4. Cranial MRI, two months after surgery

slightly hypertrophic although the tympanic membrane seemed healthy. While cleaning the granulation tissues from the perisinus area of the mastoid bone, 5 cc yellow-green colored abscess fluid drainage was observed through a defect superior to the sinus. A specimen from the draining fluid was obtained and sent for culture. Peroperative neurosurgery consultation was requested and more abscess drainage through the defect was carried out from the epidural area. The operation ended with no more complications. Culture for bacteria yielded no growth.

Three days after the first operation, the patient had had two convulsions. As neurological symptoms had not improved, and a midline shift was still present in the cranial CT scans (Figure 3), a subdural empyema was suspected and the patient was taken to the operating theatre and drainage was performed. The patient was discharged after all the neurological deficits were completely recovered. The cranial magnetic resonance imaging (MRI) taken on the postoperative second month was normal (Figure 4). In the last control of the patient in the 12th month, the mastoid cavity and tympanic membrane were observed to be healthy in the otomicroscopy (Figure 5) and no signs of infection were present. In the pure tone audiometry, the average airway threshold was 20 dB and boneway average was 10 dB in the right ear. In the left ear, airway average was 18 dB and boneway average was 10 dB.

Discussion

According to Paparella et al. (1), histopathological changes in the tympanic cavity may continue although the patient does not show a clinical otitis media. There is no perforation or discharge in the

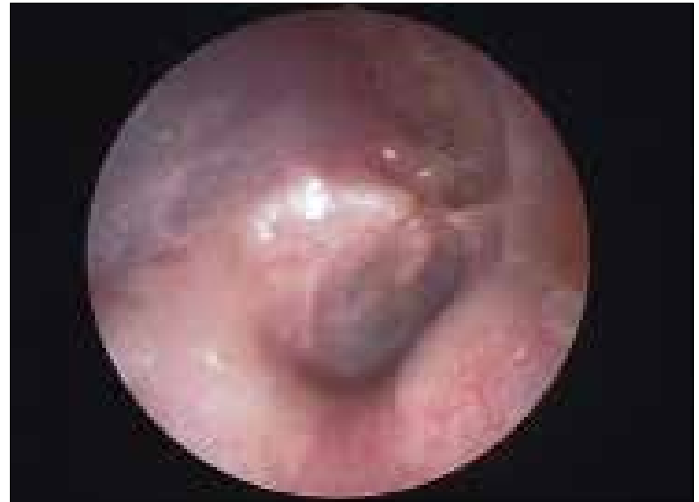

Figure 5. Otomicroscopy of right ear after surgery

tympanic membrane; however, the disease process, which can be described as masked, latent or silent, may be continuing in the tympanic cavity and/or mastoid mucosa. Presence of pulsation, granulation tissue or a localized hyperemia in pars flaccida, rear face-up of pars tensa or the adjacent external auditory canal may indicate that a latent infection is continuing in mastoid cells (2).

In a study by Tovi et al. (4) edema over the mastoid bone, pain upon pressure, hearing loss and tinnitus were the most frequent complaints of patients with silent mastoiditis who had an acute otitis media history. In examinations, pars tensa parts of the tympanic membranes were normal; however, there were differences in the pars flaccida of 20% of the patients. In their research, the most prevalent intracranial complication was meningitis. Among the other complications were lateral sinus thrombophlebitis, brain abscess, blockage in cortical sinus and encephalitis. The most prevalent temporal bone complications were sensorineural hearing loss, tinnitus and facial paralysis. Our case supports their series, as dullness was observed in the pars flaccida, and the defect made by the granulation tissue in the mastoid was just superior to the lateral sinus. This defect led the infection into the cranium instead of sinus thrombosis. Our patient might have ended up with meningitis if had not been suspected in time.

In mastoiditis cases with intracranial complications, warning symptoms such as severe earache/headache, dizziness, vomiting, shivering, fever and meningeal symptoms may develop. The characteristic of the headache is usually felt gradually at the affected temporoparietal area of the ear (2, 4). Our case also had these findings. However, epidural and subdural empyema were both present in our patient, as well. Facial paralysis and hemiparesis are the main factors that made the patient apply to our Emergency Department.

In the literature, AOM cases are often observed among children and many silent mastoiditis cases with consequent intracranial complications are often reported (5). Mastoiditis cases of children have been reported starting from 4-month-old children (6, 7). Especially for childhood groups, clinical symptoms of silent mastoiditis are non-specific and are often confused with sepsis (8).

In many research studies, it has been reported that temporal CT imag-

ing is very important for diagnosis (2, 4, 9). Aeration loss in mastoid cells and increase in the soft tissues of the attic and mastoid are the most prevalent findings (4). Soft tissue densities in the mastoid and attic were also present in our case and the most disturbing matter, which prompted us to take the patient urgently to the operating theatre, was the soft tissue blocking the aditus.

According to the literature, examinations of cases with silent mastoiditis have showed bacterial growth in 30% of the cases (10). Cultures for aerobic and anaerobic bacteria yielded no growth in our patient. This was probably due to the previous antibiotics that the patient had used.

In acute otitis media cases, as a result of inappropriate and insufficient doses of antibiotics, the course of the disease may change. Therefore, the patients with AOM who still have complaints like hearing loss, slight pain and sensitivity at the back of the ear, even after receiving treatment, should be considered in terms of latent infections in the mastoid. In this sense, the importance of CT scans should never be disregarded and both the condition of mastoid cells and the presence of a probable intracranial complication should be checked and verified with MRI if necessary. Mastoidectomy should be carried out on patients who has been diagnosed as silent mastoiditis (11, 12).

Conclusion

If there is a history of otitis media with intracranial infection in the temporal area, silent mastoiditis should be suspected and the patient should be evaluated with a temporal CT scan even if the tympanic membrane is healthy, and especially if aditus and antrum are blocked; simple mastoidectomy and exploration should be considered.

Conflict of interest

No conflicts of interest were declared by the authors.

Authors' contributions: Conceived and designed the experiments or case: OS, CC; Performed the experiments or case: MS, CC; Analyzed the data: OS, FK; Wrote the paper: MS, OS, RG, AV. All authors read and approved the final manuscript.

References

1. Paparella MM, Shea D, Meyerhoff WL, Goycoolea MV. Silent otitis media. *Laryngoscope* 1980; 90(7): 1089-98. [\[CrossRef\]](#)
2. Akyıldız N. Kulak hastalıkları ve mikrocerrahisi. Bilimsel Tıp Yayınevi, Ankara 1998; ss. 332-4.
3. Wickham MH, Marven SS, Narula AA. Three "silent" mastoid abscesses. *Br J Clin Pract* 1990; 44(6): 242-3.
4. Tovi F, Gatot A, Lantsberg S. Masked mastoiditis. *Harefuah* 1993; 125(3-4): 82-5.
5. Tovi F, Lieberman A. Silent mastoiditis and bilateral simultaneous facial palsy. *Int J Pediatr Otorhinolaryngol* 1983; 5(3): 303-7. [\[CrossRef\]](#)
6. Holt GR, Gates GA. Masked mastoiditis. *Laryngoscope* 1983; 93(8): 1034-7. [\[CrossRef\]](#)
7. Gassmann NB, Linder T. Silent mastoiditis in a 5-month-old infant. *HNO*. 2006; 54(11): 879-82. [\[CrossRef\]](#)
8. Shanley DJ, Murphy TF. Intracranial and extracranial complications of acute mastoiditis: evaluation with computed tomography. *J Am Osteopath Assoc* 1992; 92(1): 131-4.
9. Dobben GD, Raofi B, Mafee MF, Kamel A, Mercurio S. Otogenic intracranial inflammations: role of magnetic resonance imaging. *Top Magn Reson Imaging* 2000; 11(2): 76-86. [\[CrossRef\]](#)
10. Martin-Hirsch DP, Habashi S, Page R, Hinton AE. Latent mastoiditis: no room for complacency. *J Laryngol Otol* 1991; 105(9): 767-8. [\[CrossRef\]](#)
11. Sahin B, Karavus A, Sapcı T, Akbulut UG. İntrakranial komplikasyonlarla seyreden silent mastoidit: olgu sunumu. *Turk Arch Otolaryngol* 2003; 41(4): 232-8.
12. Liu YH, Qin Y, Wang QG, Zhong Z, Wang J, Xiao SF. Managements of masked mastoiditis. *Zhonghua Er Bi Yan Hou Tou Jing Wai Ke Za Zhi* 2006; 41(3): 191-4.