



Protective Surgical Procedures for Carotid Body Tumors: A Case Series

CASE REPORT

Faruk Toktaş, Gündüz Yümün, Arif Gücü, Tuğrul Göncü, Cüneyt Eriş, Çağdaş Çayır, Kağan As, Şenol Yavuz

ABSTRACT

Glomus tumors are benign tumors that originate from neural non-chromaffin cells. Its symptoms usually depend on the mass effect. The tumor can be treated with embolization, excision, and radiotherapy. The most important complications of surgery are hemiplegia and nerve injury at the surgical site. In this article, we report four cases of carotid body tumor. Four female patients presented with neck swelling and/or hypertension, and the diagnosis was made with the aid of ultrasonography, angiography, and computed tomography. These cases were classified as type 3 according to Shamblin's classification, and surgical resection was performed under local anesthesia without the need for graft interposition. These tumors were excised with the carotid artery adventitia. No complication associated with the surgery was observed in any patient.

Key words: Carotid body tumor, shamblin type 3, surgical resection

INTRODUCTION

Carotid body tumors are rarely seen tumors arising from the neural crest. They are also called paragangliomas and glomus caroticum. They can be found in many locations of the neural crest but are mostly in the carotid body (1-3). Although carotid body tumors are slowly progressive, they can present with pressure symptoms on 9th and 12th pairs of the cranial nerves, as well as symptoms, including invasion to neighboring tissues, pain, hoarseness associated with pressure, and dysphagia (4, 5). Moreover, early surgical treatment should be planned, because it may cause paroxysmal hypertension with catecholamine secretion.

Malignant transformation occurs at a rate of 3% among glomus tumors (5, 6) and 0.03% among all neoplasms. Its incidence frequency is 0.6% in head and neck neoplasms (5, 6). As the tumor gets bigger, the operation becomes more difficult, and postoperative complications increase. Carotid body tumors have been classified by Shamblin et al. (7) according to their growth patterns. Type 1 tumors are regional masses and excised without difficulty. Type 2 tumors surround the carotid arteries. Type 3 tumors account for approximately one-fourth of cases, and they are adherent, incarcerate the carotid arteries completely; most of the time, they can be excised by a challenging surgery, requiring graft replacement of the internal carotid artery. In this paper, we present 4 cases with type 3 glomus body tumors according to Shamblin's classification.

METHODS and PATIENTS

Surgical technique

Our cases were taken into the operating room after their written informed consent was obtained. The surgery was performed under local anesthesia in order to avoid possible ischemic events and nerve injuries and to stay in cooperation with the patient during the operation. During surgery, verbal communication was kept with the patient for early recognition of the patient's consciousness and to determine whether the hypoglossal nerve and the pairs of cranial nerves were affected or not. For local anesthesia, xylocaine 2% (Citanest) diluted with 1:1 physiological saline solution was used.

After the carotid body tumor was reached, the mass distals of the common carotid, external carotid, and internal carotid arteries were surrounded. In this case, the densely adherent tumoral mass was evaluated as type 3 according to the Shamblin classification. The glomus mass was incised in a Y-shape through the tumor tissue from the anterior region to the carotid artery media layer. Dissection was performed, beginning from the region between the adventitia and carotid media layer toward the mass. It was begun approximately from the 0.5-cm distal margin from the end point of the tumor tissue in other words, the unaffected region. The adventitia of carotid artery was prepared such that it remained on the tumor tissue. Then, the carotid body tumor was excised from the carotid artery by careful dissection, progressing throughout the region between the adventitia and media layers of the carotid. Several bleeding events that occurred during the dissection procedure were repaired with 6/0 Prolene suture. The mass was removed without any serious vascular injury (Figure 1).

CASE REPORTS

Case 1

A 46-year-old female patient presented with complaints of neck swelling and hypertension attacks to our clinic. The mass in the region of the carotid bifurcation was evaluated as glomus caroticum on the carotid Doppler examination.

Clinic of Cardiovascular
Surgery, Bursa Yüksek İhtisas
Hospital, Bursa, Turkey

Submitted
22.08.2012

Accepted
10.01.2013

Correspondance

Faruk Toktaş MD, Clinic of
Cardiovascular Surgery, Bursa
Yüksek İhtisas Hospital,
Bursa, Turkey
Phone: +90 533 712 19 39
e.mail:
faruktoktas@gmail.com

©Copyright 2014
by Erciyes University School of
Medicine - Available online at
www.erciyesmedj.com

Then, surgery was planned for the patient, and angiography (DSA) was performed to identify whether the tumor was supplied by the carotid or not. On DSA, an image consistent with a 5x4-cm glomus tumor having high vascularity was obtained (Figure 2).

The patient was followed up in the intensive care unit for 1 day in order to monitor postoperative blood pressure changes and was then transferred to the service without any problem. She was discharged on the third postoperative day, with full recovery under prophylactic antibiotic and acetylsalicylic acid treatment. She did not need postoperative antihypertensive therapy. During the follow-up period, the result of the ultrasonographic carotid examination that was performed every year was also found to be normal in the third year.

Case 2

An 18-year-old female patient presented to the otorhinolaryngology outpatient clinic with a complaint of neck swelling. She was referred to our clinic when an image consistent with a 5-6-cm glomus tumor with high vascularity was detected on CT and DSA (Figure 3). The patient was operated on as described above. Since the tumor of this patient was densely adherent, it was evaluated as type 3 according to Shamblin's classification. The tumor was excised completely without any severe vascular injury. The patient was followed up in the intensive care unit for 8 hours after the surgery and discharged on the third postoperative day with full recovery under prophylactic antibiotic and acetylsalicylic acid treatment. No recurrence was observed during the 22-month follow-up period.

Case 3

The most notable complaint of the 53-year-old female patient was headache. She had been receiving treatment for type 2 diabetes mel-

litus for 5 years and, additionally, medical treatment for hypertension. In this case, the region of the carotid bifurcation was prepared with an oblique neck incision under local anesthesia. This case was evaluated as Shamblin type 3, too. The tumor was removed by dissecting from the carotid. The operation was completed without any supplementary process. The patient was transferred to the service after being followed up for 4 hours in the intensive care unit. She was discharged from the hospital with full recovery on the second postoperative day. During the follow-up period, her clinical complaints disappeared, and her blood pressure was stable. However, acetylsalicylic acid and carvedilol treatment was initiated, in addition to diabetes treatment. No recurrence was observed in the patient, who was followed up for 18 months.

Case 4

A 72-year-old female patient had had a cerebrovascular event attack 2 months before admission. She had no neurological sequelae, and the examination results revealed that her echocardiographic findings were normal. The patient was in sinus rhythm. There was a 37 mm x 25 mm-sized glomus tumor in the region of the right carotid bifurcation, and it surrounded the entire carotid artery and led to a narrowing at a rate of 30% in that region. In the patient, explored under local anesthesia, the tumoral mass that was located in the region of the bifurcation incarcerated the carotid artery. The case was evaluated as Shamblin type 3. The tumoral mass was removed by dissection from the carotid artery with the technique described above. Bleeding regions that occurred during dissection were repaired primarily with 6/0 Prolene suture. The narrowing of the carotid disappeared when the mass was removed. She was followed up on the first postoperative day and discharged from the hospital on the third postoperative day with acetylsalicylic acid 300 mg treatment. There is no known problem in the patient, who has not completed the first postoperative month yet.

DISCUSSION

The carotid body is a small neurovascular tissue with posterior localization in the adventitia of the carotid bifurcation (1, 2). It is supplied by an extensive 1-2-mm arterial web originating from the carotid bifurcation. The carotid body involves a blood volume that is 10 times more than the heart myocardium and 25 times more than brain tissue at the same size due to its rich vascular structure (1, 2). The normal carotid body is approximately 12 mg (1, 2). The carotid body develops between the medial and adventitial layers of the artery. This structure is innervated by the branches of Hering's nerve, which transmits this conduction to the respiratory center in the medulla through the glossopharyngeal nerve (1, 2). The carotid body is a chemoreceptor displaying hemostatic function and is sensitive to blood flow, blood pH, pO_2 , and pCO_2 (1-3).

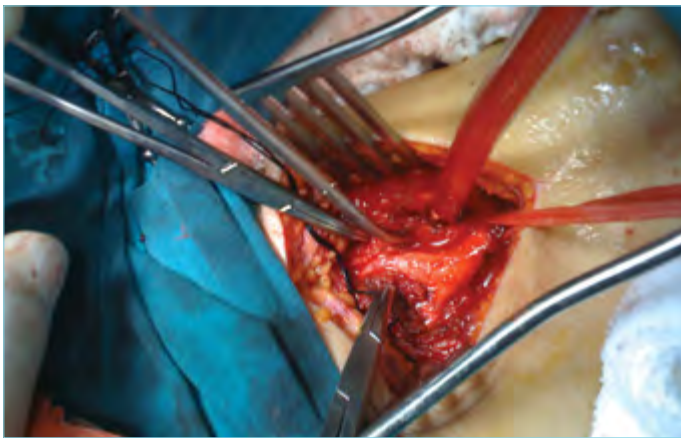


Figure 1. Image of intraoperative glomus tumor

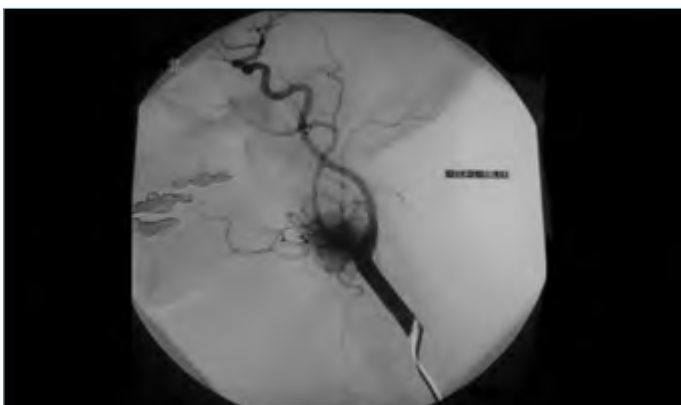


Figure 2. Vascularized carotid body tumor on the DSA (digital subtraction angiography) image

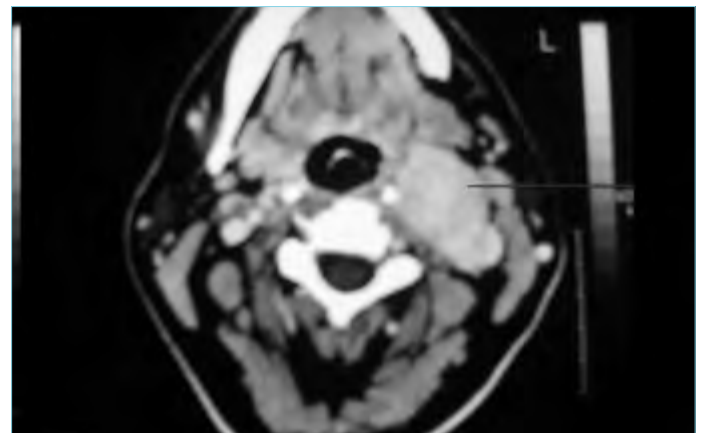


Figure 3. Imaging of carotid body tumor on computed tomography

Glomus tumors can be localized in the head and neck in four different regions. They are the jugular bulb, middle ear cavity, carotid body, and vagus nerve (11). Although paragangliomas are most frequently seen in the neck, Brown et al. (9) reported their experience with mediastinal paraganglioma among 14 cases between 1973 and 2007.

Carotid body tumors were classified by Shamblyn et al. (7), considering their growth patterns. Type 1 tumors are regional masses and excised easily. Twenty-six percent of tumors are this type. Type 2 tumors surround the carotid arteries. They are difficult to excise, and they constitute 40% of cases. Type 3 tumors account for 27% of cases, and they are adherent and incarcerate the carotid arteries completely; most of the time, they can be excised by a challenging surgery requiring graft replacement of the internal carotid artery. As the tumor gets larger, the surgery becomes more difficult, and postoperative complications increase. The main criterion for typing is the extent to which the carotid is surrounded by the tumor (7). In the 4 cases that we presented, tumor resection was performed exactly without the need for graft interposition.

Surgical excision, embolization, and radiotherapy are the treatment alternatives for carotid body tumors (8, 9). Other alternatives apart from surgery are recommended, especially for patients with a high surgical mortality rate (10). Although embolization was reported to be an effective preoperative maneuver in some studies, other studies revealed that it did not decrease bleeding during surgery and suggested that the risk of embolism had to be taken into consideration (8).

The tumor may be detected in each patient through ultrasonography or tomography following an appropriate physical examination. However, we think that DSA should be performed for patients having similar symptoms in order to investigate the possibility of another mass, the presentation of the tumor's vascular structure, the possibility of a bilateral tumor, and the presence of concurrent carotid artery disease, especially in geriatric patients. Long-term follow-up of patients should be carried out with ultrasonography.

Today, surgical intervention is considered the primary treatment method. Although postoperative mortality decreases to small rates, an increased rate of postoperative morbidity still remains. The hypoglossal nerve (XII) is the nerve that is mostly injured during operations (10). Hoarseness, dysphagia, facial paralysis, and hemiplegia can be observed when cranial nerves are injured. Basel et al. (11) reported in their series, including 33 cases, that Horner syndrome developed in 1 case and hoarseness occurred in 3 cases that recurred 6 months later. San et al. (12) conducted a series with 27 cases and stated that Horner syndrome occurred in 1 patient and preoperative vagus, and hypoglossal nerve injuries did not recover in 2 patients. In other studies, the rate of postoperative cranial nerve paralysis was reported to be 32%-40%, the rate of hemiplegia was 0%-20%, and the rate of postoperative mortality was 0%-13% (11-13).

Some authors defend that ligation of the external carotid artery is not necessary and that it should be protected. On the other hand, other authors suggest that ligation of the external carotid artery provides a safe opportunity for operation in cases with larger tumors that are densely adherent to the carotid artery (10, 13, 14). In our experience, an external carotid artery injury developed in 1 patient, but hemostasis was obtained with primary repair.

The series conducted by Talay et al. (15), including 47 cases, is the most comprehensive series with results on glomus tumors that has been published in our country. Although our cases were type 3 according to Shamblyn's classification, tumoral mass resection could be

performed through the surgical technique that we administered without the need for graft interposition.

CONCLUSION

Carotid body tumors should be taken into consideration for the differential diagnosis of a patient who presents with a mass in the neck after physical examination. We think that glomus tumor excision can be performed more easily through dissection of the adventitia and medial layers by beginning from the non-intact tissue. Surgery should be preferred, because it is performed under local anesthesia and has low mortality and morbidity rates.

Informed Consent: Written informed consent was obtained from patients who participated in this study.

Peer-review: Externally peer-reviewed.

Authors' Contributions: Conceived and designed the experiments or case: PO, AG. Performed the experiments or case: PO, İY, MC. Analyzed the data: AG, KN, FC. Wrote the paper: MB, SE, DU. All authors have read and approved the final manuscript.

Conflict of Interest: No conflict of interest was declared by the authors.

Financial Disclosure: The authors declared that this study has received no financial support.

REFERENCES

- Robert B. Rutherford MD. Vascular Surgery, Sixth Edition. Elsevier Inc 2005; 2066-73.
- Seabrook GR, Towne JB. Nonatherosclerotic cerebrovascular disease. Haimovici H, Ascer E, Hollier LH, Strandness DE, Towne JB. Haimovici's Vascular Surgery, United States of America, Blackwell Science, Inc. 1996.
- Gonzalez C, Almaraz L, Obeso A, Rigual R. Carotid body chemoreceptors: from natural stimuli to sensory discharge. *Physiol Rev* 1994; 74(4): 829-98.
- Patetsios P, Gable DR, Garrett WV, Lamont JP, Kuhn JA, Shutze WP, et al. Management of carotid body paragangliomas and review of a 30-year experience. *Ann Vasc Surg* 2002; 16(3): 331-8. [\[CrossRef\]](#)
- Van der Mey AG, Jansen JC, van Baalen JM. Management of carotid body tumors. *Otolaryngol Clin North Am* 2001; 34(5): 907-24. [\[CrossRef\]](#)
- Trimas SJ, Mancuso A, de Vries EJ, Cassisi NJ. Avascular carotid body tumor. *Otolaryngol Head Neck Surg* 1994; 110(1): 131-5. [\[CrossRef\]](#)
- Shamblyn WR, ReMine WH, Harrison EG Jr. Carotid body tumor (chemodectoma). Clinicopathologic analysis of ninety cases. *Am J Surg* 1971; 122(6): 732-9. [\[CrossRef\]](#)
- Barnes L, Estes SA. Laser treatment of hereditary multiple glomus tumors. *J Dermatol Surg Oncol* 1986; 12(9): 912-5. [\[CrossRef\]](#)
- Brown ML, Zayas GE, Abel MD, Young WF, Schaff HV. Mediastinal Paragangliomas: The Mayo Clinic Experience. *Ann Thorac Surg* 2008; 86(3): 946-51. [\[CrossRef\]](#)
- Westerband A, Hunter GC, Cintora I. Current trends in the detection and management of carotid body tumors. *J Vasc Surg* 1998; 28(3): 84-93. [\[CrossRef\]](#)
- Basel H, Ozturk H, Aydin C, Goya C, Bayar E. Diagnosis and treatment of carotid body tumors. *Pak J Med Sci* 2011; 27(4): 797-801.
- San M, Serin GM, Özdemir N. Our treatment approaches for carotid body tumors. *KBB-Forum* 2006; 5(3): 113-7.
- Matticari S, Credi G, Pratesi C, Bertini D. Diagnosis and surgical treatment of the carotid body tumors. *J Cardiovasc Surg* 1995; 36(3): 233-72.
- Wang SJ, Wang MB, Barauskas TM, Calcaterra TC. Surgical management of carotid body tumors. *Otolaryngol Head Neck Surg* 2000; 123(3): 202-6. [\[CrossRef\]](#)
- Talay S, Abanoz M, Kaygin MA, Dag Ö, Halıcı Ü, Ay D et al. Glomus caroticum tumors: A case report of an operated giant carotid body tumor with a review of our experience in 47 patients. *Central European Journal of Medicine* 2010; 5(4): 411-6. [\[CrossRef\]](#)