



A Rare Case: Suprahyoid Ectopic Thyroid Tissue

CASE REPORT

Abdullah Dalgıç, Harun Gür, Tolga Kandoğan

ABSTRACT

The presence of thyroid gland or thyroid tissue out of its normal anatomic localization is called ectopic thyroid. 90% of ectopic thyroid cases are located in the tongue base. Suprahyoid mass excision was performed because of suspicious malignancy in a patient with dysphagia and submaxillary mass. The result of histopathology was consistent with ectopic thyroid tissue. In the presence of a mass in the midline neck, ectopic thyroid tissue should be considered as well as congenital masses and malignant tumors for differential diagnosis. Moreover, it is important to evaluate a patient, for whom surgical treatment has been planned, with regard to thyroid function.

Keywords: Lingual thyroid, thyroid, neck

INTRODUCTION

The thyroid gland or thyroid tissue can be found in another region apart from its normal anatomic localization (1). If the thyroid gland is located in a place along the thyroglossal duct, in which the embryological development of the thyroid gland occurs, the term "ectopic thyroid" is generally used. On the other hand, if the thyroid gland is located in any region of the body, except its natural developmental position, the term "aberrant thyroid" is used. Ninety percent of ectopic thyroid cases are found in the tongue base (lingual thyroid). The remaining 10% is located in the suprahyoid, infrahyoid, and prelaryngeal regions along the thyroglossal line, beginning from the tongue base to the normal gland location; aberrant thyroid tissue can rarely be seen in the mediastinal region, esophagus, larynx, gallbladder, duodenum, lung, and heart tissue (1-7). The rate of ectopic thyroid tissue in the suprahyoid, infrahyoid, prelaryngeal, and neck midline has not been reported in the literature. The localization of ectopic thyroid generally occurs as asymptomatic, but some symptoms, such as dysphagia and dyspnea, can sometimes be observed, depending on its location.

In this study, a case with ectopic thyroid and a medical history of thyroid hormone replacement due to hypothyroidism, who presented with the complaint of dysphagia to our clinic and whose clinical evaluation revealed a mass in the suprahyoid region, which was found to be thyroid tissue in the histopathological evaluation conducted after total excision, was presented.

CASE REPORT

In the medical history of a 62-year-old female patient having the complaint of dysphagia for about 4 months and a palpable mass under her chin for 1 month, it was learned that she had hypothyroidism, and therefore, she had been taking thyroid hormone for nearly 10 years. At admission, the TSH, fT3, and fT4 values of the patient were evaluated to be normal. No signs of a mass and a compression were found in the endoscopic orohypopharynx examination. However, a palpable, nearly 3-cm-sized mass with asymmetry in the suprahyoid region of the midline neck was detected in the neck ultrasonography. So, magnetic resonance (MR) imaging was performed, and a 34x20-mm-sized mass between the hyoid bone and tongue base, equal to adjacent muscle tissue SI on T1 series and also equal to adjacent muscle tissue but consistent with thyroid tissue containing millimetric hyperintense nodular areas on T2 series (Figure 1), was detected. On the other hand, no thyroid tissue was observed in the normal anatomic localization of the thyroid gland.

In the thyroid scintigraphy, no activity was monitored in the thyroid area, but increased focal activity was found in the mass that was located in the suprahyoid region (Figure 2). Since the patient had not had any complaints and a palpable mass in the neck previously, we decided to remove the mass completely in order to rule out the possibility of malignancy development in ectopic thyroid tissue, and also, we planned to perform a histopathological examination. Then, the mass was excised totally (Figure 3). Written informed consent was obtained from

Clinic of Otolaryngology,
İzmir Bozyaka Research and
Training Hospital,
İzmir, Turkey

Submitted
11.07.2011

Accepted
20.02.2013

Correspondance
Abdullah Dalgıç MD, Clinic
of Otolaryngology, İzmir
Bozyaka Research and
Training Hospital,
İzmir, Turkey
Phone: +90 505 475 70 95
e.mail:
dalgicabdullah@gmail.com

©Copyright 2014
by Erciyes University School of
Medicine - Available online at
www.erciyesmedj.com

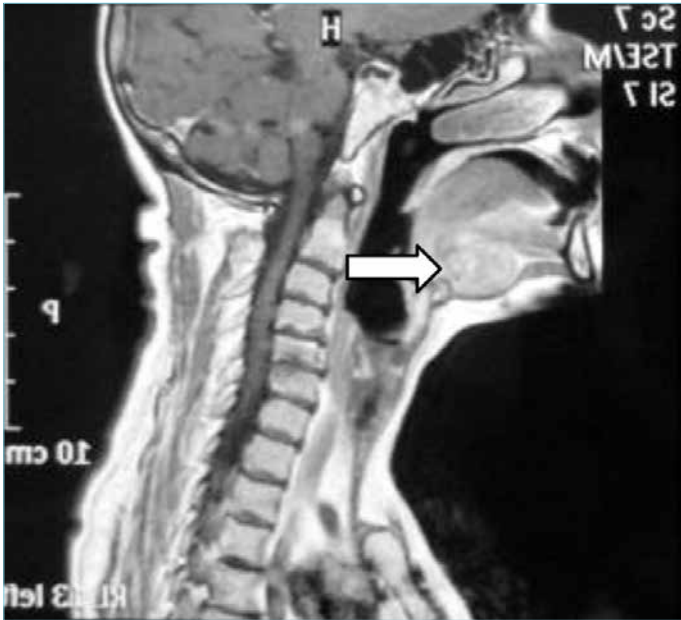


Figure 1. Preoperative sagittal MR image of the patient having complaints of dysphagia and a mass under the chin. A 34x20-mm-sized mass between the hyoid bone and tongue base, equal to adjacent muscle tissue SI on T2 series and consistent with the thyroid tissue containing millimetric hyperintense nodular areas (arrow)

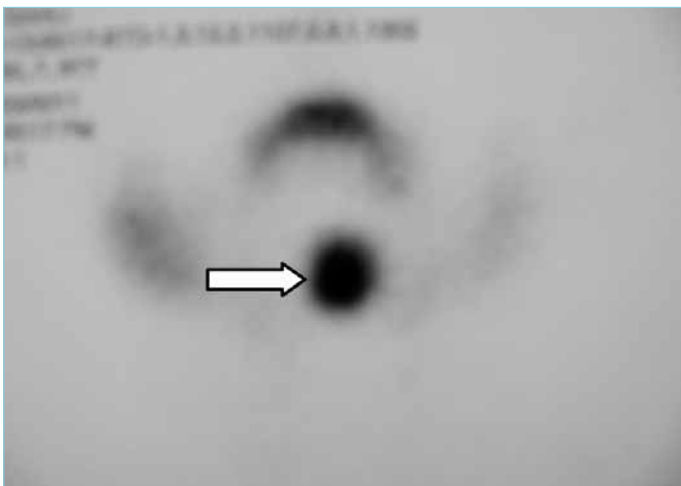


Figure 2. Thyroid scintigraphy of the patient applying with complaints of dysphagia and a mass under the chin. Focal activity involvement is observed in the sublingual area (arrow)

the patient. The report of the histopathological examination was consistent with thyroid tissue, and no malignancy was observed. Moreover, her complaint of dysphagia regressed after the operation. In the postoperative thyroid function tests, the value of TSH was found to be high, and the values of fT3 and fT4 were found to be low. Then, the patient consulted the endocrinology clinic for thyroid hormone replacement.

DISCUSSION

Embryonic development of the thyroid gland begins about 24 days after fertilization, from the endodermal diverticulum (2). Ectopic

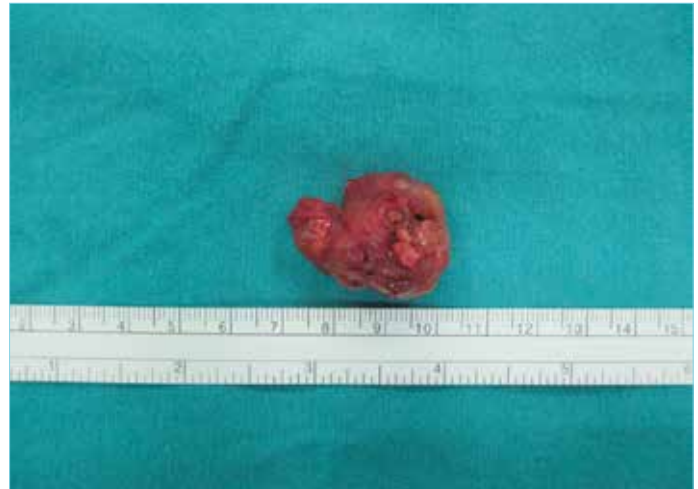

Figure 3. Macroscopic image of the excised suprahyoid mass for the case presenting with dysphagia and a mass under the chin

thyroid occurs due to the formation of an anomaly during embryonic development of the thyroid tissue and incomplete migration. Up to the present, at least 400 lingual thyroid cases, but rarely suprahyoid ectopic cases, have been reported (8-10). In cases with lingual thyroid, ectopic thyroid tissue generally exists in the tongue base, and an ectopic thyroid mass can also be seen inside the mouth (2, 8). Owing to close anatomical adjacency of the tongue base, tongue, and suprahyoid area, it is difficult to denominate ectopic thyroid tissue and to identify its margins in these regions. In the literature, lingual ectopic thyroid is generally the most commonly used term. We used the term “suprahyoid ectopic mass” in our case, since the ectopic thyroid mass was located in the suprahyoid area, rather than in the tongue base.

Ectopic thyroid tissue is mostly seen in women and in the second decade of life. Approximately 70% of cases with ectopic thyroid do not have a thyroid gland in the normal anatomic localization. Also, in the case presented here, there was no thyroid gland in the normal anatomic localization, but her thyroid functions were within normal intervals. The patient had been receiving treatment for her hypothyroidism for about 10 years. In a literature review, it is noticed that hypothyroidism is seen almost in 14.5% to 33% of patients with lingual thyroid (8, 11-13).

The symptoms of ectopic thyroid tissue differ according to its location. Since most of the cases occur in the thyroglossal line, they generally present with dysphagia, dysphonia, dyspnea, asymptomatic neck mass, hyperthyroidism, or hypothyroidism (14). When it is considered that more than 90% of ectopic thyroid cases are confronted with a mass in the neck, it is important to carefully perform a differential diagnosis with congenital masses, including thyroglossal duct cyst, dermoid cyst, and branchial cyst, and with benign and malignant diseases presenting with a mass in the neck. When ectopic thyroid tissue is suspected, ultrasonography, computed tomography, and MR provide quite valuable findings both for the differential diagnosis and before surgical intervention. Thyroid scintigraphy is the golden standard method for ectopic thyroid tissue. The state of activity in normal thyroid area and ectopic thyroid tissue plays a key role in the diagnosis and treatment choice.

The treatment of ectopic thyroid tissue is carried out, considering the symptoms of the patient and the possibility of malignancy. Surgical treatment should be performed when ectopic thyroid in the neck leads to symptoms, such as dysphagia, dysphonia, and dyspnea; when hyperthyroid and severe bleeding are available; and when malignancy can not be ruled out (12). In 70% of cases with ectopic thyroid, the only functional thyroid tissue is ectopic tissue. When these patients undergo surgical treatment, they should also be evaluated with regard to thyroid function. The risk for transformation of ectopic thyroid tissue into malignancy has rarely been reported in the literature. Most malignancies arising from ectopic thyroid tissue are papillary thyroid carcinoma (1).

CONCLUSION

In the presence of a mass in the midline neck, ectopic thyroid tissue should be taken into consideration, as well as congenital masses and malignancy, in the differential diagnosis, and patients for whom surgical treatment is planned should also be evaluated with regard to thyroid function.

Informed Consent: Written informed consent was obtained from patient who participated in this study.

Peer-review: Externally peer-reviewed.

Authors' Contributions: Conceived and designed the experiments or case: AD, TK, HG. Performed the experiments or case: AD, TK, HG. Analyzed the data: AD, TK. Wrote the paper: AD, TK. All authors have read and approved the final manuscript.

Conflict of Interest: No conflict of interest was declared by the authors.

Financial Disclosure: The authors declared that this study has received no financial support.

REFERENCES

1. Ling L, Zhou SH, Wang SQ, Wang LJ. Misdiagnosed ectopic thyroid carcinoma: report of two cases. *Chin Med J (Engl)* 2004; 117: 1588-9.
2. Toso A, Colombani F, Averono G, Aluffi P, Pia F. Lingual thyroid causing dysphagia and dyspnoea. Case reports and review of the literature. *Acta Otorhinolaryngol Ital* 2009; 29: 213-7.
3. Pollice L, Caruso G. Struma cordis. Ectopic thyroid goiter in the right ventricle. *Arch Pathol Lab Med* 1986; 110: 452-3.
4. Porqueddu M, Antona C, Polvani G, Pompilio G, Cavoretto D, Gianolli L, et al. Ectopic thyroid tissue in the ventricular outflow tract: embryologic implications. *Cardiology* 1995; 86: 524-6. [\[CrossRef\]](#)
5. Ferlito A, Giarelli L, Silvestri F. Intratracheal thyroid. *J Laryngol Otol* 1988; 102: 95-6. [\[CrossRef\]](#)
6. Hazarika P, Siddiqui SA, Pujary K, Shah P, Nayak DR, Balakrishnan R. Dual ectopic thyroid: a report of two cases. *J Laryngol Otol* 1998; 112: 393-5. [\[CrossRef\]](#)
7. Smoker W.R.K. Oral Cavity. In Som P.M, Curtis H.D. *Head and Neck Imaging*. 3rd edn St Louis: Mosby. 488-544, 1996.
8. Akgül C, Nazaroğlu H, Özmen S, Senol A, İki Lingual tiroid olgusu *Tip araştırmaları Dergisi* 2005;3(1):34-7
9. Quarracino M, Aguas S. Lingual thyroid: a clinical case. *Med. oral*. 2003;8(1):57-60
10. Gibson JR, Noblett HR. Suprahyoid median ectopic thyroid. *Aust Paediatr J*. 1977 Mar;13(1):49-52.
11. Unal O, Arslan H, Peksoy U, Kutluhan A. Lingual ektopik tiroidde multinodüler guatr. *Turk J Diagn Intervent Radiol* 2001; 7:346-349
12. Osma Ü, Tekin M, Topçu İ, Üstel M. Lingual tiroid. *Kulak Burun Boğaz İhtisas Dergisi* 1997; 4 :168-70.
13. Prasad KC, Bhat V. Surgical management of lingual thyroid: a report of four cases. *J Oral Maxillofac Surg*. 58(2):223-7 [\[CrossRef\]](#)
14. MU, Ozcan M. Lingual thyroid. *Otolaryngol Head Neck Surg* 1996;115(5):483-4 [\[CrossRef\]](#)