



# A Case with Reactive Airway Dysfunction Syndrome Accompanied by Non-Cardiogenic Pulmonary Edema

## CASE REPORT

Tuba Öğüt<sup>1</sup>, Ayşe Nur Soytürk<sup>1</sup>, Hilal Akdemir<sup>1</sup>, Hatice Kılıç<sup>1</sup>, Ayşegül Karalezli<sup>1</sup>, Hatice Canan Hasanoğlu<sup>2</sup>

## ABSTRACT

Reactive airway dysfunction syndrome (RADS) is a disease that causes bronchial hyper-reactivity with asthma-like symptoms within 24 hours, and it causes high-level irritant exposure in patients who did not have any previous lung disease. In general, the patient's radiological findings are normal, although some changes are often seen. Pulmonary edema is rarely seen radiologically. In a 43-year-old female patient's thorax computed tomography (CT) scan after the inhalation of a mixture of hydrochloric acid and sodium hypochloride, ground glass opacities, which implies bilaterally pulmonary edema, are detected. This case is presented because RADS is rarely accompanied by pulmonary edema.

Keywords: Toxic inhalation, non-cardiogenic pulmonary edema, reactive airway dysfunction syndrome

## INTRODUCTION

Reactive airway dysfunction syndrome (RADS) is a disorder characterized by asthma-like symptoms in patients not previously diagnosed with pulmonary disease. It develops within 24 h after the inhalation of excess amounts of non-allergen and non-immunogenetical smoke, gas, and dust, leading to bronchial hyperreactivity (1). The symptoms including cough, shortness of breath, and wheezing start within minutes to hours (2). Medical histories of patients generally do not involve respiratory complaints or allergy (1). The chemical agents that are most commonly associated with RADS etiology are inhaled chlorine, toluene diisocyanate, and nitrogen oxide (3). The mechanism of RADS development relies on the toxic effects of the irritants on the airway (1). Radiological findings vary; however, they are generally completely normal (4). Radiologically, pulmonary edema is rarely seen (4). A 47-year-old female patient was admitted to the emergency department with the manifestation of an asthma attack, having developed after the inhalation of a mixture of hydrochloric acid (spirit of salt) and sodium hypochloride (bleach). Her thoracic computed tomography (CT) revealed some regions with icy glass appearance, which was suggestive of bilateral diffuse pulmonary edema. This case has been presented in the present study because a RADS case accompanied by pulmonary edema is rarely encountered.

## CASE REPORT

A 47-year-old female patient was admitted to the emergency department with complaints of sudden-onset shortness of breath, cough, wheezing, and white-colored phlegm. She had no known history of any pulmonary disease. She smoked 30 packs per year and had no history of allergy and asthma. It was learned that 8 h before admission to the hospital, cough and shortness of breath suddenly developed after inhaling a mixture of bleach, spirit of salt, and dish-washing detergent. On physical examination, her general condition was moderate; she was conscious, cooperative, and oriented. On respiratory system examination, oxygen-free saturation was 89% and diffuse sibilant rhonchus was detected during auscultation. In the laboratory findings, white blood cell count was 12000 K/uL and neutrophils were 82%. C-reactive protein level (CRP) was found to be 14 mg/dL (reference interval: 0-0.8 mg/dL). Because posteroanterior chest radiography (PAAC) revealed heterogeneous dense regions in the middle and lower zones, the patient underwent thoracic CT. On thoracic CT, icy glass appearance starting from the perihilar region, suggestive of bilateral pulmonary edema was seen (Figure 1). The sudden onset of symptoms in the patient led us to think of RADS because she had no history of pulmonary disease. Short-acting bronchodilator therapy, 40 mg methylprednisolone, and 500 mg levofloxacin for elevated CRP level were initiated. Respiratory testing revealed FEV<sub>1</sub> was 76%, FVC was 82%, FEV<sub>1</sub>/FVC ratio was 67, and PEF was 66%; the result of reversibility test was positive. During follow-up, auscultation findings of the respiratory system had regressed, as a result of which, after 10 days, the steroid treatment dose was decreased to 20 mg. In the third week of treatment, clinical improvement was observed and the steroid treatment dose was gradually decreased and subsequently discontinued. Long-acting

<sup>1</sup>Clinic of Chest Diseases, Ankara Atatürk Training and Research Hospital, Ankara, Turkey

<sup>2</sup>Department of Chest Diseases, Yıldırım Beyazıt University Faculty of Medicine, Ankara, Turkey

Submitted  
24.11.2013

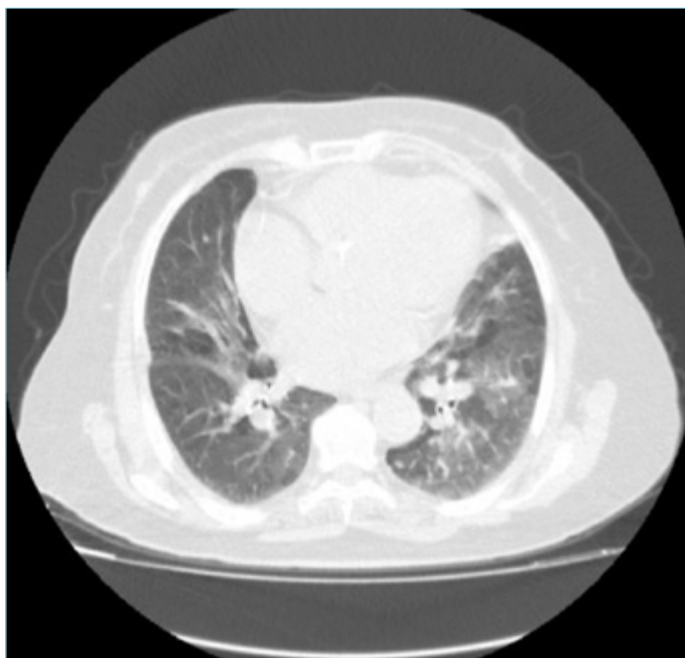Accepted  
28.02.2014

### Correspondance

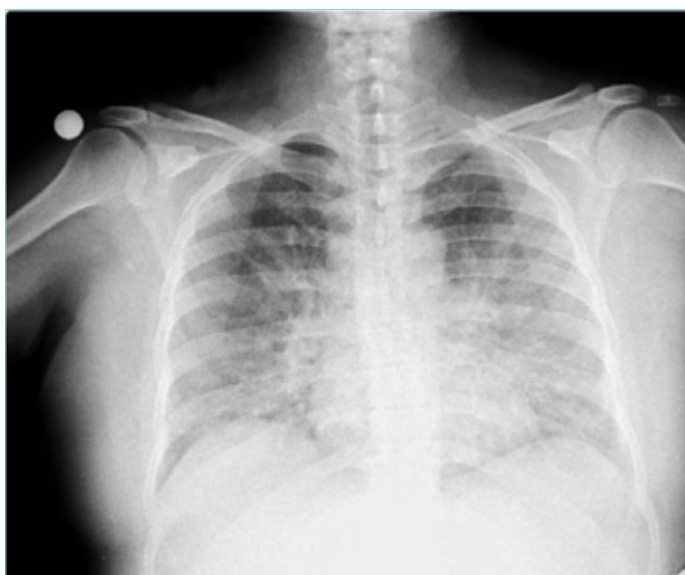Dr. Tuğba Öğüt, Ankara Atatürk Eğitim ve Araştırma Hastanesi, Göğüs Hastalıkları Kliniği, Ankara, Türkiye  
Phone: +90 312 291 25 25  
e.mail: tubaogut@gmail.com

This study was presented at the 35<sup>th</sup> National TUSAD Congress, 2-6 October 2013, İzmir, Turkey.

©Copyright 2015  
by Erciyes University School of Medicine - Available online at  
www.erciyesmedj.com



**Figure 1.** Icy glass appearance suggestive of pulmonary edema in the thorax CT performed after toxic inhalation

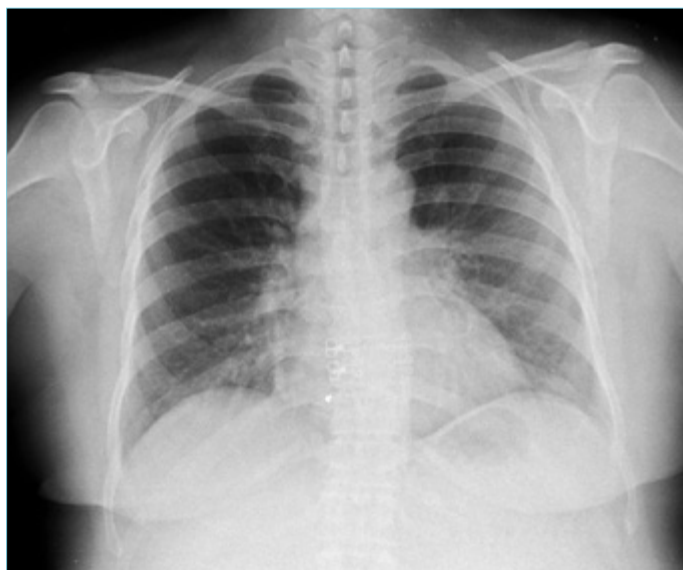


**Figure 2.** Image suggesting pulmonary edema in the PA chest X-ray taken at admission

inhaled beta-mimetic and inhaled steroid therapies were continued. Moreover, chest radiography performed at follow-up was normal (Figure 2, 3). In the third month of follow-up, the patient complained of ongoing cough and inhaler therapy was still being continued. In the fourth month of follow-up, the patient did not have any respiratory complaints. The results of respiratory function tests were within normal limits. Therefore, the dose of inhaler therapy was decreased, and the patient was followed-up.

## DISCUSSION

Reactive airway dysfunction syndrome (RADS) was first defined by Brooks et al. (1) in 1985. It is a disorder characterized by asthma-



**Figure 3.** Apparent improvement in the PA chest X-ray performed one week after treatment

like symptoms in patients not previously diagnosed with any pulmonary disease. It develops within 24 h after inhalation of excess amounts of smoke, gas, and dust. In this condition, the type of exposure that is described by patients can be so intense and severe that they cannot forget it even after years (5).

Inhalation mostly occurs by accident or in environment where there is no ventilation or air circulation (1). Inhaled agents can be gases, aerosols, or vapors generated after heating (1). Exposure generally occurs in occupational accidents. However, in our country, the use of a mixture of bleach and spirit of salt by women while cleaning is a cause of RADS. Its symptoms include cough, shortness of breath, and wheezing that start within minutes to hours (2). It can be confused with asthma due to the similarity in symptoms. However, while the symptoms of RADS last for a period of time, asthma is a permanent disease.

The symptoms of RADS continue for at least 3 months (2). Moreover, the period of RADS symptoms can extend and can also lead to chronic airway diseases (6). Irritants manifest themselves as asthma, obliterative bronchiolitis, and bronchiolitis obliterans organizing pneumonia (7). The disease often occurs through various clinical pictures, including bronchitis, chemical pneumonia, and mild pulmonary edema (1). The pathogenesis of RADS is unclear; however, it is thought that irritants act through the “big bang” mechanism. Accordingly, irritants cause damage in the epithelium and in the non-adrenergic and non-cholinergic nerve fibers, and they lead to neurogenic inflammation and mast cell degranulation (8). It is thought that inhaled toxic agents cause inflammation, desquamation, subepithelial hemorrhage, and swelling in the airway epithelium and bronchial hyperreactivity due to the immunomediators that are released (2). In RADS etiology, the effects of toxic chemical agents such as inhaled chlorine, toluene diisocyanate, and nitrogen oxide are frequently demonstrated (3). It is known that chloramines and other toxic chlorine products are produced when household cleaners are mixed with spirit of salt, including chlorine, and the inhalation of chlorine compounds rarely causes

RADS (7). There is no specific diagnostic test for the final diagnosis of the disease (9). The diagnosis of the disease can be established only through detailed anamnesis. The diagnostic criteria for RADS defined by Brooks in 1985 are given below (4).

1. No history of any known pulmonary disease.
2. Development of sudden-onset symptoms after exposure to a single dose or accident.
3. Exposure to irritant amounts and high concentrations of gas, cigarette smoke, vapor, or smoke.
4. Appearance of symptoms within 24 h of exposure and their continuance for at least 3 months.
5. Imitation of asthma with some symptoms being predominant, including cough, wheeze, and shortness of breath.
6. Existence of obstruction in respiratory function tests.
7. Elimination of other pulmonary diseases.
8. Positive result on methacholine provocation test.
9. Absence of atopy.
10. Presence of inflammation and mucosal injury without eosinophilia in the biopsy specimen of bronchial mucosa (9).

Our case had most of the above mentioned diagnostic criteria because she did not have a history of pulmonary disease, sudden-onset symptoms occurred after intensive toxic gas inhalation, and the symptoms imitated those of asthma.

During the establishment of diagnosis, complete blood cell count, chest radiography, respiratory function tests, and allergic skin test are performed only for eliminating asthma and other diseases. In respiratory function tests, reversibility is seen in >15% patients. Radiological findings of RADS differ. Chest radiography is normal or consistent with hyperinflation, and a clinical picture of pulmonary edema is rarely seen (4). Our case had no history of asthma or atopy. She was admitted with the manifestation of asthma-like symptoms. In thoracic CT, the size of the heart was within normal range, and areas with diffuse icy glass appearance with bilateral perihilar localization were seen. The patient was evaluated with regard to the causes of secondary non-cardiogenic pulmonary edema; however, no cause, except the inhalation of irritants agent, was found.

The treatment of RADS is similar to that of asthma. Therapy with Nasal oxygen, bronchodilators, and corticosteroids are recommended (9). However, the response rate of patients to  $\beta_2$ -agonists is less than that in asthma (10).

## CONCLUSION

Reactive airway dysfunction syndrome is characterized by a clinical picture of acute asthma, developing as a result of inhalation of

toxic agents by accident in patients with no history of an asthma diagnosis or symptoms. No specific diagnostic test is currently available for the disease and a history of toxic inhalation is important for diagnosing. Therefore, in patients who do not have a history of any pulmonary disease and who are admitted with the symptoms of asthma, the inhalation history should also be investigated in detail. In these patients, the chest radiography findings are generally normal. Moreover, non-cardiogenic pulmonary edema can also develop when the inhaled irritants reach the alveoli. RADS should be considered in the differential diagnosis of patients who present with a clinical picture of non-cardiogenic pulmonary edema.

**Informed Consent:** Written informed consent was obtained from the patient.

**Peer-review:** Externally peer-reviewed.

**Authors' Contributions:** Conceived and designed the experiments or case: TÖ, AS, HA, HK. Performed the experiments or case: TÖ. Analyzed the data: TÖ. Wrote the paper: TÖ, HK, AK, HCH. All authors read and approved the final manuscript.

**Conflict of Interest:** No conflict of interest was declared by the authors.

**Financial Disclosure:** The authors declared that this study has received no financial support.

## REFERENCES

1. Brooks SM, Weiss MA, Bernstein IL. Reactive airways dysfunction syndrome (RADS); persistent asthma syndrome after high level irritant exposures. *Chest* 1985; 88(3): 376-84. [\[CrossRef\]](#)
2. Tarlo SM. Critical aspects of the history of occupational asthma. *Allergy Asthma Clin Immunol* 2006; 2 (2): 74-7. [\[CrossRef\]](#)
3. Shakeri MS, Dick FD, Ayres JG. Which agents cause reactive airways dysfunction syndrome (RADS)? A systematic review. *Occup Med* 2008; 58(3): 205-11. [\[CrossRef\]](#)
4. Malo JL, Chan-Yeung M, Lemi re M. Reactive airways dysfunction syndrome and irritant-induced asthma. <http://www.uptodate.com/contents/reactive-airways-and-irritant-induced-asthma/contributors> (updated: Oca 11, 2013).
5. Emel Kurt. Mesleksel Astım. In:  zlı T, Metintaş M, Karadağ M, Kaya A (edit). *Solunum Sistemi ve Hastalıkları*. İstanbul: 2010. cilt 2. p. 1602.
6. Patel RK, Patel P, Patel NJ. Reactive airway dysfunction after high level irritant exposures. *International research of journal of pharmacy* 2012; 3(8): 254-6.
7. CebraİL Şimşek. Toksik Ajanlara Bağlı Akciğer Hasarı. *Klinik Gelişim* 2010. Cilt 23(4); 71-8.
8. Varney VA, Evans J, Bansal AS. Successful treatment of reactive airways dysfunction syndrome by high-dose vitamin D. *J Asthma Allergy* 2011; 4: 87-91. [\[CrossRef\]](#)
9. Patel PD, Patel RK, Patel NJ. Review on reactive airways dysfunction syndrome (RADS). *Asian Journal of Pharmaceutical and Clinical Research* 2012; 3(5): 10-5.
10. Palczynski C, Gorski P, Jakubowski J. The case of TDI-induced reactive airway dysfunction syndrome with the presence of specific IgE antibodies. *Allergol Immunopathol* 1994; 22(2): 80-2.