



Paget's Disease of the Breast Presenting as a Local Recurrence Following Breast-conserving Surgery

Haldun Kar¹, Necat Cin¹, Cengiz Tavusbay¹, Kürşat Yemez¹, Yasin Peker¹, Ayşegül Akder Sarı², Evren Durak¹, Fatma Atalay Tatar¹

CASE REPORT

ABSTRACT

Paget's disease of the breast is a relatively rare condition. It is accompanied by underlying in situ or invasive carcinoma in most cases. The diagnosis of Paget's disease several years after the conservative surgical treatment of breast carcinoma has rarely been described in literature. Here we report an interesting case of Paget's disease presenting as a local recurrence following breast-conservation treatment for infiltrating ductal carcinoma and glycogen-rich clear cell carcinoma in a 44-year-old woman. Any eczematous changes around the areola–nipple area may remind the local recurrence with Paget's disease following breast-conserving treatment for malignancy. Long-standing erythematous changes should be investigated with prompt pathological evaluations in these patients.

Keywords: Local recurrence, Paget's disease of the breast, breast cancer

INTRODUCTION

Paget's disease (PD) of the breast is a relatively rare condition. It is accompanied by underlying in situ or invasive carcinoma in most cases (1). The diagnosis of PD several years after the conservative surgical treatment of breast carcinoma has rarely been described in literature (2-4). Nipple deformations following radiotherapy after breast-conserving surgery are usually suggested to be benign disorders leading to a delayed diagnosis of PD. Nipple biopsy in the early period is diagnostic for the disease. Glycogen-rich clear cell carcinoma (GRCCC) of the breast is a rare histological subtype of breast cancer and is associated with an aggressive clinical course. Here we report an interesting case of PD presenting as a local recurrence following breast-conserving surgery for infiltrating ductal carcinoma and GRCCC.

CASE REPORT

A 44-year-old woman presented with a mass in the upper inner quadrant of her right breast, and her physical examination revealed a 2 cm mass in 2011. A radiological investigation revealed a complicated cystic lesion of 2.3 cm diameter in the upper inner quadrant of the right breast. Fine-needle biopsy confirmed that the tumor was malignant. Breast-conservation surgical treatment and axillary lymph node dissection were performed. The patient had free surgical margins during the surgical procedure. Frozen section was not employed for the retroareolar tissues because the areola complex was normal during the exam.

The pathological examination of the specimen revealed a 1.8 cm tumor consisting of infiltrating ductal carcinoma and GRCCC (Figure 1, 2). Immunohistochemistry showed that the lesion was estrogen and progesterone receptor-negative and c-erbB-2 (3+). All 10 dissected axillary lymph nodes were free of involvement. The patient received adjuvant cyclophosphamide, 5 FU chemotherapy, and radiotherapy.

The patient was admitted to our department 15 months after the index operation with a suspicious eczematous lesion of the right areola–nipple area, which was noted during the follow-up examination. She was also found to have erythema of the nipple. Excisional biopsy and pathological diagnosis confirmed PD of the nipple (Figure 3a). Mammography, ultrasonography (US), and magnetic resonance imaging (MRI) showed no concomitant pathological feature in this and contralateral breast. She subsequently underwent simple mastectomy. A pathological examination revealed PD with an association of intraductal involvement (Figure 3b) but no other foci of carcinoma. At the last follow-up, 3 years after her local recurrence, she was alive with no evidence of the disease.

DISCUSSION

Paget's disease (PD) of the breast was first described in 1874. Its incidence has been reported to be between 0.5% and 5% of all breast carcinomas (5). PD mostly presents as eczematous changes of the nipple-areolar com-

This study was presented at the 18th National Surgical Congress, 23-27 May 2012, İzmir, Turkey

¹Department of General Surgery, Katip Çelebi University Atatürk Training and Research Hospital, İzmir, Turkey

²Department of Pathology, Katip Çelebi University Atatürk Training and Research Hospital, İzmir, Turkey

Submitted
01.08.2014

Accepted
25.09.2014

Correspondance

Dr. Haldun Kar,
Katip Çelebi Üniversitesi
Atatürk Eğitim ve Araştırma
Hastanesi, Genel Cerrahi
Anabilim Dalı, İzmir,
Türkiye
Phone: +90 532 346 34 22
e.mail:
haldunkar@hotmail.com

©Copyright 2016
by Erciyes University School of
Medicine - Available online at
www.erciyesmedj.com

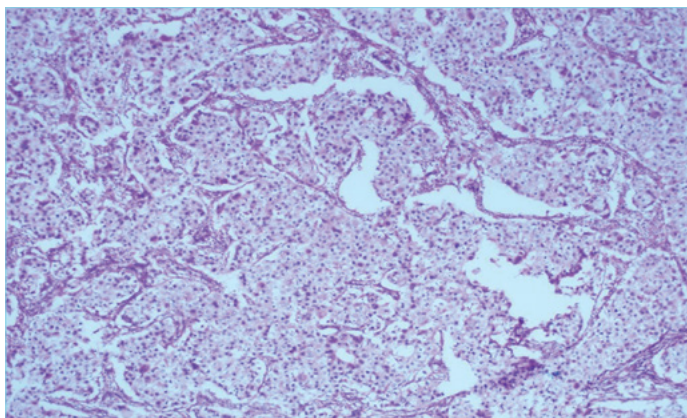


Figure 1. Tumor cell nests with the large eosinophilic cytoplasm

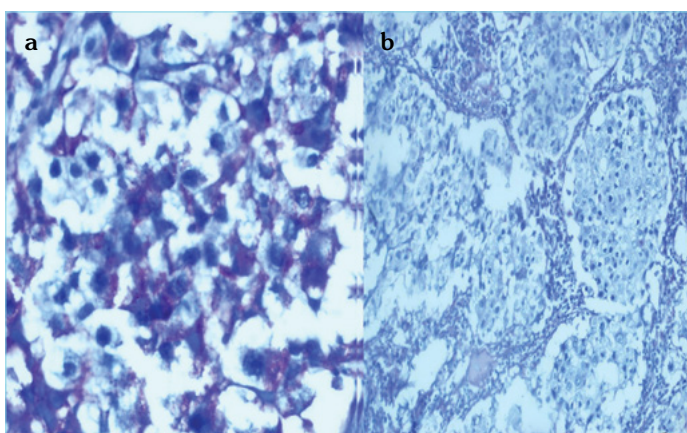


Figure 2. (a) Periodic acid-Schiff stain (PAS) positivity is observed in the cytoplasm of tumoral cells. (b) Cytoplasmic PAS positivity is lost during treatment with diastase in d-PAS staining

plex, such as erythema, itching, and scaling of the skin, and can be mistaken for dermatitis or a benign dermatological condition (6). Histologically, it is characterized by typical neoplastic infiltration in the epidermal layer of the nipple–areolar complex (4).

The pathological origin of Paget's cells has been debated. The epidermotropic theory states that tumor cells migrate to the epidermis from an underlying breast carcinoma. An opposing theory advocates that PD results from the malignant transformation of cells already present in the epidermis (2).

Paget's disease (PD) of the nipple can be discovered in conjunction with an invasive cancer mass having an underlying ductal carcinoma in situ (DCIS) or alone without any underlying invasive breast carcinoma or DCIS (7). The associated concomitant cancer can be centrally located, adjacent to the nipple, or may be peripherally within the breast tissue. PD alone without any underlying cancer consists of only 8% of all PD cases (8).

All patients with a suspicion of PD should then undergo an additional evaluation to identify the underlying malignancy. Evaluation should always include a careful examination of the breast and axilla by mammography, US, and MRI. MRI is more sensitive than mammography for detecting multifocal or multicentric breast cancer and also PD of the breast (9).

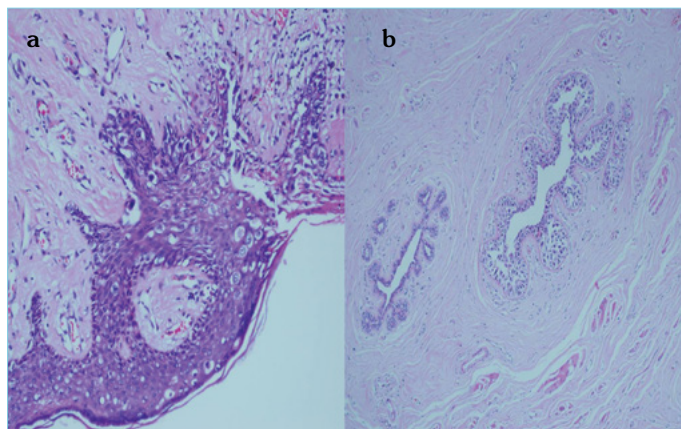


Figure 3. (a) Paget cells, which are characterized by malignant glandular cells with pale cytoplasm and prominent nucleolus, are dispersed throughout the epidermis of the nipple. (b) Pagetoid spread of intraductal carcinoma along lactiferous ducts in the mastectomy specimen

Paget's disease (PD) of the breast also can be detected as a local recurrence after breast-conserving treatment (BCT) for malignant breast disease (2). It has been reported that it consists of between 2.2% and 13% of all recurrences after BCT. Lohsiriwat et al reported this to be 19.4% in their series (4).

The median time to recurrence of the reported cases of PD following BCT is approximately 2 years, but it ranges from 5 months to 10 years (2). In our case, recurrence occurred at 15 months. The average age of the patients with PD discovered following BCT is found to be lower than that of patients with primary PD. Lohsiriwat reported an average age of 42.8 years in their series (4). Our patient was 44 years old during her evaluation.

The clinical presentation of PD can mimic the signs of radiation dermatitis. The changes in pigmentation and radio-dystrophy could have a part of the clinical presentation of PD and should be carefully evaluated (4). In the series by Plastaras et al. (2) 2 of 4 patients had delays in diagnosis after the appearance of skin changes. Because nipple changes were initially attributed to post radiation therapy.

Mastectomy remains the standard salvage surgery (2). The treatment of our patient consisted of simple mastectomy alone without any chemotherapy and no axillary treatment. Our patient did not receive radiotherapy; however, it can be added to the adjuvant treatment protocol in patients with invasive components in the recurrence lesion.

An axillary sentinel lymph node study has been recommended for patients with PD (10). We did not perform axillary sampling in our patient because she already had axillary dissection during her index operation.

Patients with PD generally have primary tumors with estrogen and progesterone negative-receptor status. Overexpressed HER2-neu status was also detected in these patients by Caliskan et al (10). The tumor characteristics of invasive cancer associated with PD are more aggressive than those of invasive cancer not associated with PD. GRCCC of the breast is a rare sub-type of invasive duc-

tal carcinoma and generally tends to follow an aggressive clinical course (11, 12).

CONCLUSION

Any eczematous changes around the areola–nipple area may remind the local recurrence with PD following breast conserving treatment for malignancy. Long-standing erythematous changes should be investigated with prompt pathological evaluations in these patients. PD of the breast is rare following BCT, but it should be aggressively evaluated in suspicious cases. Invasive components in the recurrence lesion may remind the presence of synchronous lesion.

Informed Consent: Written informed consent was obtained from the patient.

Peer-review: Externally peer-reviewed.

Authors' Contributions: Conceived and designed the experiments or case: HK, CT, AAS. Performed the experiments or case: HK, NC, KY. Analyzed the data: YP, FT. Wrote the paper: HK, ED. All authors have read and approved the final manuscript.

Conflict of Interest: No conflict of interest was declared by the authors.

Financial Disclosure: The authors declared that this study has received no financial support.

REFERENCES

- Marcus E. The Management of Paget's Disease of the Breast. *Curr Treat Options Oncol* 2004; 5(2): 153-60.
- Plastaras JP, Harris EE, Solin LJ. Paget's disease of the nipple as local recurrence after breast-conservation treatment for early-stage breast cancer. *Clin Breast Cancer* 2005; 6(4): 349-53.
- Shousha S, Tisdall M, Sinnett HD. Paget's disease of the nipple occurring after conservative surgery for ductal carcinoma in situ of the breast. *Histopathology* 2004; 45(4): 416-8.
- Lohsiriwat V, Martella S, Rietjens M, Botteri E, Rotmensz N, Mastropasqua MG, et al. Paget's disease as a local recurrence after nipple-sparing mastectomy: clinical presentation, treatment, outcome, and risk factor analysis. *Ann Surg Oncol* 2012; 19(6): 1850-5.
- Sakorafas GH, Blanchard K, Sarr MG, Farley DR. Paget's disease of the breast. *Cancer Treat Rev* 2001; 27(1): 9-18.
- Morrogh M, Morris EA, Liberman L, Zee VK, Cody HS, King TA. MRI identifies otherwise occult disease in select patients with Paget's disease of the nipple. *J Am Coll Surg* 2008; 206(2): 316-21.
- Chen CY, Sun LM, Anderson BO. Paget's disease of the breast: Changing patterns of incidence, clinical presentation, and treatment in the U.S. *Cancer* 2006; 107(7): 1448-58.
- Dalberg K, Hellborg H, Warnberg F. Paget's disease of the nipple in a population based cohort. *Breast Cancer Res Treat* 2008; 111(2): 313-9.
- Siponen E, Hukkinen K, Heikkilä P, Joensuu H, Leidenius M. Surgical treatment in Paget's disease of the breast. *Am J Surg* 2010; 200(2): 241-6.
- Caliskan M, Gatti G, Sosnovskikh I, Rotmensz N, Botteri E, Musci S, et al. Paget's disease of the breast: the experience of the European institute of oncology and review of the literature. *Breast Cancer Res Treat* 2008; 112: 513-21.
- Kuroda H, Sakamoto G, Ohnisi K, Itoyama S. Clinical and pathological features of glycogen-rich clear cell carcinoma of the breast. *Breast Cancer* 2005; 12(3): 189-95. [\[CrossRef\]](#)
- Markopoulos C, Mantas D, Philipidis T, Kouskos E, Antanopoulou Z, Hatzinikolaou ML, et al. Glycogen-rich clear cell carcinoma of the breast. *World J Surg Oncol* 2008; 6: 44. [\[CrossRef\]](#)