



# Clinical Presentation of Epileptic Seizures in a Child with a Final Diagnosis of Atrial Fibrillation: A Pediatric Case Report

Ayşe Kaçar Bayram<sup>1</sup>, Özge Pamukçu<sup>2</sup>, Sefer Kumandaş<sup>1</sup>, Zübeyde Gündüz<sup>3</sup>, Mehmet Canpolat<sup>1</sup>, Güldemet Kaya Özçora<sup>1</sup>, Hakan Gümüş<sup>1</sup>, Ali Baykan<sup>2</sup>, Hüseyin Per<sup>1</sup>

CASE REPORT

ABSTRACT

Many cardiovascular disorders may result in blackouts accompanied by abnormal movements attributable to generalized brain hypoxia. In some cases, it may be difficult to distinguish between cardiovascular and epileptogenic causes. Therefore, misdiagnosis of epilepsy and use of unnecessary antiepileptic medication can often be seen in these patients. Although rare in children, atrial fibrillation may cause loss of consciousness. This disorder has strong association with underlying cardiovascular diseases. In this case report, we describe a previously healthy 13-year-old girl presenting with transient loss of consciousness, urinary incontinence, and generalized tonic-clonic convulsions. She was diagnosed with atrial fibrillation based on physical examination and electrocardiography findings. Cardiovascular disorders should be assessed in patients presenting with transient loss of consciousness and seizure-like symptoms. We emphasize that complete physical examination and electrocardiography recording are necessary for correct diagnosis of patients.

Keywords: Atrial fibrillation, cardiac arrhythmia, convulsion, pediatric

## INTRODUCTION

Misdiagnosis of childhood epilepsy is an ongoing problem among pediatricians. In epilepsy referral centers, epilepsy misdiagnosis was detected in 30% of children who referred with a diagnosis of epilepsy (1). Many types of cardiovascular diseases may result in transient loss of consciousness with abnormal movements associated with generalized cerebral hypoxia.

Atrial fibrillation is a very rare disorder in childhood characterized by rapid and irregular heartbeat. It has usually been associated with structural heart diseases, such as rheumatic heart disease and congenital heart disease, and hypertrophic cardiomyopathy (2).

We describe a 13-year-old girl who was admitted to our Pediatric Neurology Department with complaints of transient loss of consciousness, urinary incontinence, and generalized tonic-clonic convulsions. She had a final diagnosis of atrial fibrillation but was initially suspected of having epileptic seizures.

## CASE REPORT

A 13-year-old girl presented to our clinic with complaints of transient loss of consciousness, urinary incontinence, and generalized tonic-clonic convulsions. She was born after an uneventful pregnancy at 39 weeks of gestation and uncomplicated delivery. The perinatal history was unremarkable. She was the first child of a non-consanguineous couple. Her medical history was unremarkable. Physical and neurological examinations were normal except for an irregular heart rhythm with a range of 85–145 beats/minute. Informed consent was obtained from the patient's parents before the diagnostic tests and interventions. Routine laboratory investigations of patient were normal. Cerebral magnetic resonance imaging (1.5-T MRI imaging scanner, Gyroscan Intera, Philips Healthcare medical system; Netherlands) and electroencephalography recordings (Grass-Telefactor; West Warwick, RI, USA) were entirely normal. A 12-lead electrocardiography (GE Healthcare; Milwaukee, WI, USA) revealed atrial fibrillation (Figure 1). The patient referred to the Pediatric Cardiology Department, and she was investigated using 48-hour electrocardiography (GE Healthcare; Milwaukee, WI, USA), transesophageal echocardiogram (Vivid 7 Pro system, GE Medical Systems; Milwaukee, WI, USA), and coronary computed tomography angiography (LightSpeed VCT 64, GE Healthcare; Milwaukee, WI, USA). The 48-hour electrocardiography confirmed the presence of atrial fibrillation. Transesophageal echocardiogram demonstrated the secundum type of atrial septal defect, and defect size was measured as 13 mm diameter. Computed tomography coronary angiogram was normal. The patient was treated with 100 J and 150 J synchronized cardioversion, but cardiac arrhythmia did not respond to cardioversion.

<sup>1</sup>Division of Pediatric Neurology, Department of Pediatrics, Erciyes University School of Medicine, Kayseri, Turkey

<sup>2</sup>Division of Pediatric Cardiology, Department of Pediatrics, Erciyes University School of Medicine, Kayseri, Turkey

<sup>3</sup>Division of Pediatric Nephrology and Rheumatology, Department of Pediatrics, Erciyes University School of Medicine, Kayseri, Turkey

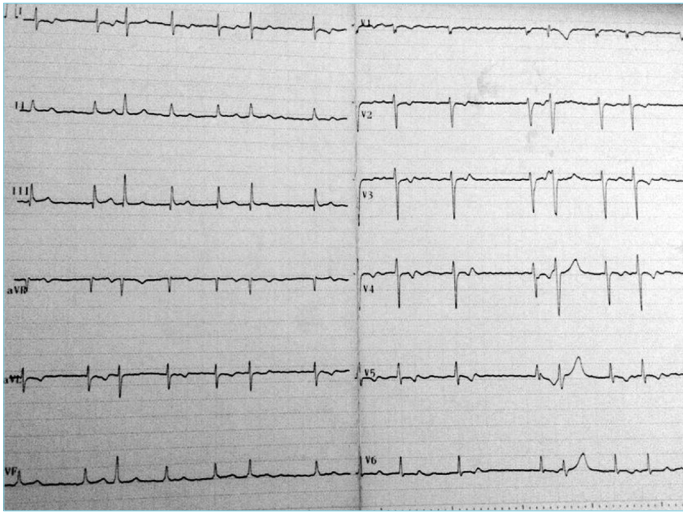
Submitted  
13.09.2015

Accepted  
15.04.2016

### Correspondence

Dr. Hüseyin Per,  
Erciyes Üniversitesi Tıp  
Fakültesi, Çocuk Sağlığı ve  
Hastalıkları Anabilim Dalı,  
Çocuk Nörolojisi Bilim Dalı,  
Kayseri, Türkiye  
Phone: +90 352 207 66 66  
e.mail:  
huseyinper@yahoo.com

©Copyright 2016  
by Erciyes University School of  
Medicine - Available online at  
www.erciyesmedj.com



**Figure 1.** A 12-lead electrocardiography revealing spontaneous atrial fibrillation, with an irregular heart rhythm ranging between 85 and 145 beats/minute

Therefore she was given acetylsalicylic acid 100 mg/day and 750 mg amiodarone was given for loading dose and 400 mg/day as maintenance dose. Atrial fibrillation persisted despite these medical therapies; therefore, transcatheter closure of an atrial septal defect with an Amplatzer septal occluder (ASO, AGA Medical Corporation, Golden Valley, MN, USA) and radiofrequency ablation were performed. The patient is currently being followed-up with only acetylsalicylic acid 100 mg/day.

## DISCUSSION

Transient loss of consciousness is a common presenting symptom, which has many possible causes, as well as different therapeutic, psychosocial, and prognostic implications. Transient global cerebral hypoperfusion has been implicated as responsible for potential pathomechanism. Transient loss of consciousness may be accompanied by abnormal limb movements in many causes of cardiovascular disorders such as arrhythmias (3, 4). Because of the important prognostic impact of the presence of cardiovascular disorders, the previously healthy children with loss of consciousness with or without abnormal movements should be assessed with detailed medical history and physical examination, as well as electrocardiography. Here, we described a pediatric case of atrial fibrillation with presentation of transient loss of consciousness, urinary incontinence, and generalized tonic-clonic convulsions. Physical examination of patient showed an irregular heart rhythm, and a 12-lead electrocardiography revealed atrial fibrillation.

Atrial fibrillation is associated with the risk of thromboembolic cerebral ischemia and substantially impaired heart function. Treatment of atrial fibrillation in children includes pharmacological therapy, transesophageal atrial pacing, electrical cardioversion, and catheter ablation (5). Our case did not respond to treatment of pharmacological and electrical cardioversion, and therefore radiofrequency ablation was performed.

Abnormal movement, such as generalized tonic-clonic, is probably the most misleading in the diagnosis between transient loss

of consciousness and seizure disorders. Simultaneous electroencephalographic and electrocardiographic recordings are important in differentiate transient loss of consciousness and seizure.

On the other hand, there are clinically important relations between cardiac arrhythmias and seizure disorders. Atrial fibrillation is also associated with generalized tonic-clonic seizure. Prolonged perictal atrial fibrillation has been described in patients with epilepsy (6, 7). Pathophysiological mechanisms of prolonged perictal atrial fibrillation have been suggested as generalized tonic-clonic convulsion-related increase in sympathetic tone and release of catecholamines (6, 7).

## CONCLUSION

We would like to emphasize that a patient presenting with a transient loss of consciousness accompanied by abnormal movements should not be immediately assumed as having epilepsy. Physical examination and detailed medical history, as well as electrocardiography, are important in differential diagnosis of these patients.

**Informed Consent:** Informed consent was obtained before the study from the patient's parents.

**Peer-review:** Externally peer-reviewed.

**Authors' Contributions:** Conceived and designed the experiments or case: HP, AKB. Performed the experiments or case: AKB, HP, ÖP, HG, AB, MC, GKÖ, HG, SK, ZG. Analyzed the data: AKB, HP, ÖP. Wrote the paper: AKB, HP. All authors have read and approved the final manuscript.

**Acknowledgement:** All authors thank the patient and family members for their participation in this study.

**Conflict of Interest:** No conflict of interest was declared by the authors.

**Financial Disclosure:** The authors declared that this study has received no financial support.

## REFERENCES

1. Uldall P, Alving J, Hansen LK, Kibaek M, Buchholt J. The misdiagnosis of epilepsy in children admitted to a tertiary epilepsy centre with paroxysmal events. *Arch Dis Child* 2006; 91(3): 219-21. [\[CrossRef\]](#)
2. Wasmer K, Breithardt G, Eckardt L. The young patient with asymptomatic atrial fibrillation: what is the evidence to leave the arrhythmia untreated? *Eur Heart J* 2014; 35(22): 1439-47. [\[CrossRef\]](#)
3. Zaidi A, Clough P, Cooper P, Scheepers B, Fitzpatrick AP. Misdiagnosis of epilepsy: many seizure-like attacks have a cardiovascular cause. *J Am Coll Cardiol* 2000; 36(1): 181-4. [\[CrossRef\]](#)
4. Petkar S, Cooper P, Fitzpatrick AP. How to avoid a misdiagnosis in patients presenting with transient loss of consciousness. *Postgrad Med J* 2006; 82(972): 630-41. [\[CrossRef\]](#)
5. Fazio G, Visconti C, D'Angelo L, Novo G, Barbaro G, Novo S. Pharmacological therapy in children with atrial fibrillation and atrial flutter. *Curr Pharm Des* 2008; 14(8): 770-5. [\[CrossRef\]](#)
6. Surges R, Moskau S, Viebahn B, Schoene-Bake JC, Schwab JO, Elger CE. Prolonged atrial fibrillation following generalized tonic-clonic seizures. *Seizure* 2012; 21(8): 643-5. [\[CrossRef\]](#)
7. Vedovello M, Baldacci F, Nuti A, Cipriani G, Ulivi M, Vergallo A, et al. Perictal prolonged atrial fibrillation after generalized seizures: description of a case and etiopathological considerations. *Epilepsy Behav* 2012; 23(3): 377-8. [\[CrossRef\]](#)