



Increased Expression of E-cadherin, Endothelin-1, and CD68 in Preeclamptic Placentas

Sevgi İrtegun¹, Mehmet Ali Tekin¹, Rojbin Alpaycı²

ORIGINAL
INVESTIGATION

ABSTRACT

Objective: Preeclampsia (PE) is a complex pregnancy-specific disorder characterized by the onset of hypertension and proteinuria in the second trimester of pregnancy. The pathogenesis of PE still remains unknown. Revealing the specific proteins involved in placental functions is important for a better understanding of the pathogenesis of PE. In this study, we aimed to investigate the expression levels of E-cadherin, endothelin-1, and CD68 in both preeclamptic and normal placentas.

Materials and Methods: In this study, placentas after birth at 35–38 weeks were included. Ten preeclamptic placentas and 10 normal placentas were used. The expression levels of E-cadherin, endothelin-1, and CD68 were measured by western blot.

Results: It was observed that the expression of E-cadherin and endothelin-1 was not at detectable levels in normal placentas; however, E-cadherin and endothelin-1 were observed to be highly expressed in preeclamptic placentas. In addition, the expression of CD68 was found to be markedly increased in preeclamptic placentas in comparison to control placentas.

Conclusion: The increased expression of E-cadherin, endothelin-1, and CD68 may play an important role in impaired trophoblast invasion, endothelial dysfunction, and inadequate spiral remodeling, which are key factors involved in the pathogenesis of PE.

Keywords: Preeclampsia, E-cadherin, endothelin-1, CD68, placenta

INTRODUCTION

Preeclampsia (PE) is a complex pregnancy-specific multisystem disorder, which is characterized by the onset of hypertension and proteinuria after the 20th week of gestation (1, 2). In addition to hypertension and proteinuria, PE also affects the central nervous system, lungs, liver, heart, and kidneys. PE occurs in about 5–7% of all pregnancies worldwide and is the primary cause of maternal and neonatal morbidity and mortality (3). Although the pathophysiological mechanisms of PE are unclear, increasing evidence has shown that abnormal placentation and endothelial dysfunction play a key role in the pathological changes in PE (4-6).

The placenta is the maternal–fetal interface, which provides the efficient blood supply required for the exchange of nutrients, waste, and gas between the maternal and fetal circulations. Trophoblasts, which form the outer layer of the placenta, are divided into two layers: an underlying layer known as cytotrophoblasts and an overlying layer known as syncytiotrophoblasts (7-9). PE is associated with the impaired migration/invasiveness of trophoblasts, which leads to endothelial dysfunction, incomplete uterine vascular remodeling, and, consequently, poor placental perfusion. In a normal pregnancy, the invasion of cytotrophoblasts results in remodeling of the uterine spiral arteries, which is required for placental perfusion. In PE, remodeling of the spiral arteries is impaired as a result of poor trophoblast migration/invasion (10, 11).

E-cadherin is an adherent junction protein expressed by epithelial tissues, which is important for the development of the embryo and the formation of cell–cell interactions via intracellular binding to catenins such as β -catenin, plakoglobin, and p120 catenin (12). Endothelin-1 is a vascular regulator that is produced by endothelial cells and cardiomyocytes, which has vasoconstrictive and mitotic effects via the stimulation of growth factors. It is also important in hypertension, acting as a blood pressure elevator (13, 14). CD68, which belongs to the LAMP (lysosomal-associated membrane protein) family of glycoproteins, is expressed by monocytes and macrophages. Its main function is unknown, but, because of its location close to the endosomal or lysosomal membrane, an antigen process is presumed to be involved in preventing the hydrolysis of lysozyme (15).

¹Department of Medical Biology, Dicle University Faculty of Medicine, Diyarbakır, Turkey

²Dicle University Faculty of Medicine, Diyarbakır, Turkey

Submitted
23.08.2016

Accepted
25.09.2016

Correspondence
Sevgi İrtegun MD,
Department of Medical Biology, Dicle University Faculty of Medicine, Diyarbakır, Turkey
Phone: +90 553 474 27 38
e.mail:
irtegunsevgi@hotmail.com

©Copyright 2016
by Erciyes University Faculty of Medicine - Available online at
www.erciyesmedj.com

The investigation of a specific protein in the preeclamptic placenta can provide important information for the better understanding of potential mechanisms that cause PE. Studies of the associations of E-cadherin, endothelin-1, and CD68 in PE have been limited. Therefore, in this study we aimed to investigate the expression of E-cadherin, endothelin-1, and CD68 in the preeclamptic placenta.

MATERIALS and METHODS

Study subjects

This study was approved by the local ethics committee. Informed consent was obtained from the patients and healthy subjects. Ten preeclamptic placentas from women diagnosed with PE and 10 normal placentas from healthy pregnant women were included in the study. Pregnant women with PE were selected on the basis of an increased systolic blood pressure (>140 mmHg) and an increased diastolic blood pressure (>90 mmHg) with proteinuria (300 mg/24 h) on urine analysis. Preeclamptic pregnant women with infection, chronic hypertension, and any other chronic diseases were excluded from the study. Healthy pregnant women used as controls were selected on the basis of having a normotensive and non-proteinuric pregnancy with no medical or obstetric complications. The demographic and clinical features of the women with PE and the normal pregnant women are given in Table 1.

Placental tissue collection

Placental tissue samples (1 cm × 1 cm × 1 cm) were cut from the maternal side near to the umbilical cord in a sterile condition and were immediately flash-frozen using liquid nitrogen. The flash-frozen placental tissues were stored at -86°C until being analyzed by western blot.

Antibodies for western blot

Anti-endothelin-1 and anti-β-actin were purchased from Abcam. Anti-E-cadherin and anti-CD68 were obtained from Santa Cruz Biotechnology.

Western blot analysis

The flash-frozen placental tissues were ground to a fine powder in a chilled mortar in the presence of liquid nitrogen. Immediately after grinding, the placenta powder was lysed on ice in RIPA buffer (Sigma-Aldrich) supplemented with a cocktail of protease and phosphatase inhibitors (Thermo Scientific). The total cellular protein concentration was determined using a BCA protein assay kit according to the manufacturer's instructions (Pierce, Thermo Scientific). The total cellular proteins (20 μg) were separated by a 10% SDS-PAGE gel and the separated proteins from the SDS-PAGE gel were transferred onto a polyvinylidene difluoride membrane (Bio-Rad). Nonspecific binding was blocked by membrane incubation in PBS with 5% nonfat dried milk and 0.05% Tween-20 for 1 h at room temperature. The membranes were probed with primary antibodies for 2 h at room temperature. The total levels of E-cadherin, endothelin-1, and CD68 were determined using the respective antibodies. β-actin was used as a loading control. Appropriate HRP-conjugated secondary antibodies were used to visualize the specific bands. The protein bands were visualized using ECL (Bio-Rad) according to the manufacturer's instructions. Images were taken using a ChemiDoc™ MP system (Bio-Rad).

Table 1. Demographic and clinical characteristics of the study groups

Characteristics	Preeclampsia (n=10)	Control (n=10)	*p
Maternal age (years)	28.4±5.7	29.4±3.8	0.518
Gestational age (weeks)	32.6±3.35	33.7±4.2	0.197
Body mass index (kg/m ²)	23.85±3.63	22.7±2.62	0.521
Systolic blood pressure (mmHg)	161.3±18	119.6±6.4	<0.001
Diastolic blood pressure (mmHg)	105.5±15	73.6±5.9	<0.001
Proteinuria (g/24 h)	0.42±0.13	-	-

Data are shown as the mean±SD.
*p values of <0.05 are presented in boldface

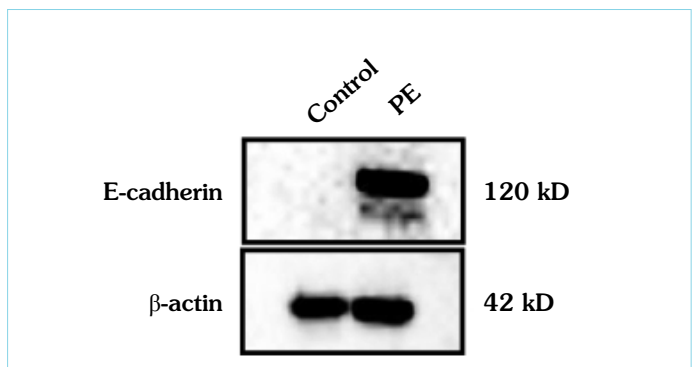


Figure 1. The expression of E-cadherin was significantly increased in preeclamptic placentas. Cell lysates were examined for the presence of E-cadherin, which was detected using anti-E-cadherin antibodies by western blot. The lower panel represents the loading control (β-actin). The image shown represents a single representative example of 10 separate experiments

RESULTS

In the present study, the expression levels of E-cadherin, endothelin-1, and CD68 were examined in preeclamptic placentas and normal placentas used as controls by western blot. PE patients were approximately matched for age, gestational age, and body mass index with normal pregnant women (Table 1). It was found that there was no detectable expression of E-cadherin or endothelin-1 in the control placentas (Figure 1, 2). However, the expression of E-cadherin and endothelin-1 was found to be dramatically increased in preeclamptic placentas in comparison to those derived from healthy women (Figure 1, 2). The results showed that whereas CD68 was expressed at low levels in normal placentas, the expression of CD68 was highly elevated in preeclamptic placentas (Figure 3). Taken together, the results showed that PE induces the expression of E-cadherin, endothelin-1, and CD68.

DISCUSSION

In this study, we reported that the expression of E-cadherin, endothelin-1, and CD68 is upregulated in preeclamptic placentas in comparison to control placentas.

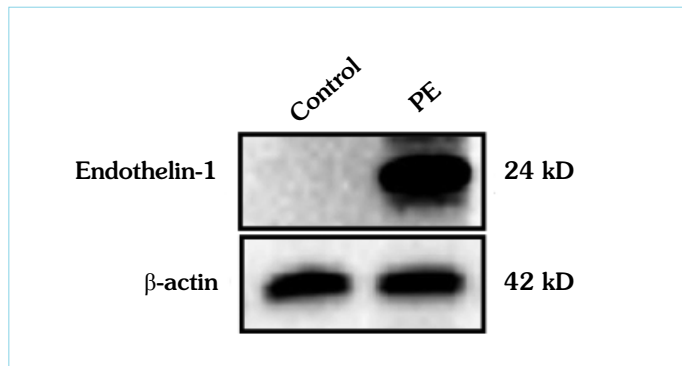


Figure 2. The expression of endothelin-1 was dramatically increased in preeclamptic placentas. Cell lysates were examined for the presence of endothelin-1, which was detected using anti-endothelin-1 antibodies by western blot. The lower panel represents the loading control (β -actin). The image shown represents a single representative example of 10 separate experiments

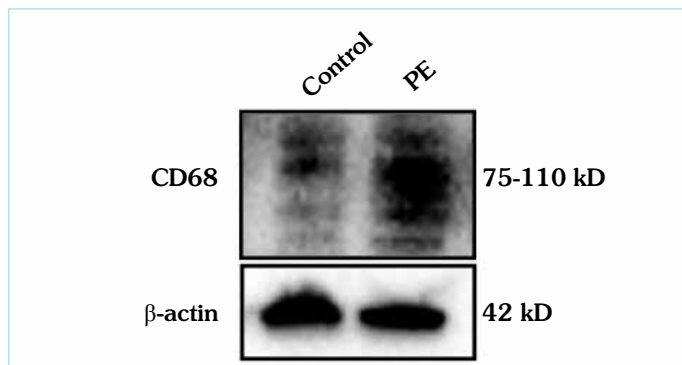


Figure 3. The expression of CD68 was markedly elevated in preeclamptic placentas. Cell lysates were examined for the presence of CD68, which was detected using anti-CD68 antibodies by western blot. The lower panel represents the loading control (β -actin). The image shown represents a single representative example of 10 separate experiments

E-cadherin, which is a classical cell-cell adhesion molecule, is expressed in villous cytotrophoblasts and its expression and location are associated with the morphology of trophoblasts and are important for healthy placental development (16). The expression of E-cadherin has been shown to be elevated in preeclamptic placentas (17). It has been reported that an elevation of the expression of E-cadherin promotes the proliferation of cytotrophoblasts and inhibits their differentiation into syncytiotrophoblasts in PE (18). In good agreement with previous studies, we found that the expression of E-cadherin in the placenta was increased as a result of PE. This finding suggests that an increase in the expression level of E-cadherin may play an important role in the pathogenesis of PE.

We observed that the expression of endothelin-1 was not at detectable levels in the control placentas; however, its expression was greatly increased in the placentas of PE patients. Endothelin-1, which is a vasoconstrictor, has been shown to be associated with maternal endothelial dysfunction, which is a major hallmark of PE (19). An increase in the expression of endothelin-1 results in increases in vasoconstriction, hypertension, and other clinical man-

ifestations of PE. Levels of endothelin-1 mRNA in trophoblasts were shown to be higher in PE patients than in healthy subjects, which suggests that endothelin-1 is associated with inadequate trophoblast invasion in PE (20). Furthermore, a study demonstrated that the plasma endothelin-1 level in patients with PE is correlated with the level of damage to the endothelium and the severity of the disease (21). It is conceivable that an increase in the expression of endothelin-1 is involved in the pathogenesis of PE and may be an important cause of hypertension, endothelial dysfunction, and impaired trophoblast invasion in PE.

The innate immune system is known to be over-activated in PE (22). During a healthy pregnancy, macrophages play a key role in the regulation of implantation, the apoptosis and invasion of trophoblasts, and remodeling of the spiral arteries (23, 24). In PE, the macrophage population is increased in the placenta and macrophage-induced apoptosis leads to defective trophoblast invasion and impaired remodeling of the uterine spiral arteries (25, 26). Our data showed that the expression of CD68 was highly elevated in preeclamptic placentas in comparison to normal placentas. An increased CD68 level indicates an increased number of macrophages. This finding supports the theory that the macrophage population may have a critical role in the pathophysiology of PE, and the immunomodulatory role of macrophages may alter trophoblast invasion and hinder remodeling of the spiral arteries associated with poor placentation.

CONCLUSION

We have demonstrated that the expression of E-cadherin, endothelin-1, and CD68 was increased in PE. Understanding the molecular factors involved in the pathophysiology of PE could help in the development of new approaches for the prediction and treatment of PE.

Ethics Committee Approval: Ethics committee approval was received for this study from local ethics committee.

Informed Consent: Informed consent was obtained from patients who participated in this study.

Peer-review: Externally peer-reviewed.

Authors' Contributions: Conceived and designed the experiments: SI. Performed the experiments: SI, MAT, RA. Analyzed the data: SI. Wrote the paper: SI, MAT. All authors have read and approved the final manuscript.

Acknowledgements: The authors thank Dr Müberra Namlı-Kalem for providing placental tissue samples.

Conflict of Interest: No conflict of interest was declared by the authors.

Financial Disclosure: The authors declared that this study has received no financial support.

REFERENCES

- Hutcheon JA, Lisonkova S, Joseph KS. Epidemiology of pre-eclampsia and the other hypertensive disorders of pregnancy. *Best Pract Res Clin Obstet Gynaecol* 2011; 25(4): 391-403. [CrossRef]
- Trogstad L, Magnus P, Stoltenberg C. Pre-eclampsia: Risk factors and causal models. *Best Pract Res Clin Obstet Gynaecol* 2011; 25(3): 329-42. [CrossRef]

3. American College of Obstetricians and Gynecologists. Hypertension in Pregnancy. Report of the American College of Obstetricians and Gynecologists' Task Force on Hypertension in Pregnancy. *Obstet Gynecol* 2013; 122(5): 1122-31.
4. Saleh L, Verdonk K, Visser W, van den Meiracker AH, Danser AH. The emerging role of endothelin-1 in the pathogenesis of pre-eclampsia. *Ther Adv Cardiovasc Dis* 2016; 10(5): 282-93. [\[CrossRef\]](#)
5. Sak S, Erdemoğlu M, Ağaayak E, Yalınkaya A, Gül T. Evaluation of serum Troponin I Levels in preeclampsia. *Dicle Med J* 2015; 42(2): 186-91. [\[CrossRef\]](#)
6. Verdonk K, Visser W, Van Den Meiracker A, Danser AH. The renin-angiotensin-aldosterone system in pre-eclampsia: the delicate balance between good and bad. *Clin Sci (Lond)* 2014; 126(8): 537-44. [\[CrossRef\]](#)
7. Velicky P, Knöfler M, Pollheimer J. Function and control of human invasive trophoblast subtypes: Intrinsic vs. maternal control. *Cell Adh Migr* 2016; 10(1-2): 154-62. [\[CrossRef\]](#)
8. Walentin K, Hinze C, Schmidt-Ott KM. The basal chorionic trophoblast cell layer: An emerging coordinator of placenta development. *Bioessays* 2016; 38(3): 254-65. [\[CrossRef\]](#)
9. Mutluay D. Essential transcription factors for mouse blastocyst stage embryos. *Scientific Works. Series C. Veterinary Medicine* 2015; LXI(1): 35-40.
10. Walentin K, Hinze C, Schmidt-Ott KM. The basal chorionic trophoblast cell layer: An emerging coordinator of placenta development. *Bioessays* 2016; 38(3): 254-65. [\[CrossRef\]](#)
11. Chaiworapongsa T, Chaemsaitong P, Yeo L, Romero R. Pre-eclampsia part 1: current understanding of its pathophysiology. *Nat Rev Nephrol* 2014; 10(8): 466-80. [\[CrossRef\]](#)
12. Schneider MR, Dahlhoff M, Horst D, Hirschi B, Trülzsch K, Müller-Höcker J, et al. A key role for E-cadherin in intestinal homeostasis and Paneth cell maturation. *PLoS One* 2010; 5(12): e14325. [\[CrossRef\]](#)
13. Rich S, McLaughlin VV. Endothelin receptor blockers in cardiovascular disease. *Circulation* 2003; 108(18): 2184-90. [\[CrossRef\]](#)
14. Schiffrin EL, Intengan HD, Thibault G, Touyz RM. Clinical significance of endothelin in cardiovascular disease. *Curr Opin Cardiol* 1997; 12(4): 354-67.
15. Gottfried E, Kunz-Schughart LA, Weber A, Rehli M, Peuker A, Müller A, et al. Expression of CD68 in non-myeloid cell types. *Scand J Immunol* 2008; 67(5): 453-63. [\[CrossRef\]](#)
16. Kokkinos MI, Murthi P, Wafai R, Thompson EW, Newgreen DF. Cadherins in the human placenta—epithelial- mesenchymal transition (EMT) and placental development. *Placenta* 2010; 31(9): 747-55. [\[CrossRef\]](#)
17. Li XL, Dong X, Xue Y, Li CF, Gou WL, Chen Q. Increased expression levels of E- cadherin, cytokeratin 18 and 19 observed in preeclampsia were not correlated with disease severity. *Placenta* 2014; 35(8): 625-31. [\[CrossRef\]](#)
18. Brown LM, Lacey HA, Baker PN, Crocker IP. E-cadherin in the assessment of aberrant placental cytotrophoblast turnover in pregnancies complicated by pre-eclampsia. *Histochem Cell Biol* 2005; 124(6): 499-506. [\[CrossRef\]](#)
19. Fiore G, Florio P, Micheli L, Nencini C, Rossi M, Cerretani D, et al. Endothelin-1 triggers placental oxidative stress pathways: putative role in preeclampsia. *J Clin Endocrinol Metab* 2005; 90(7): 4205-10. [\[CrossRef\]](#)
20. Napolitano M, Miceli F, Calce A, Vacca A, Gulino A, Apa R, et al. Expression and relationship between endothelin-1 messenger ribonucleic acid (mRNA) and inducible/endothelial nitric oxide synthase mRNA isoforms from normal and preeclamptic placentas. *J Clin Endocrinol Metab* 2000; 85(6): 2318-23. [\[CrossRef\]](#)
21. Bussen S, Sütterlin, Steck T. Plasma endothelin and big endothelin levels in women with severe preeclampsia or HELLP-syndrome. *Arch Gynecol Obstet* 1999; 262(3-4): 113-9. [\[CrossRef\]](#)
22. Borzychowski AM, Sargent IL, Redman CW. Inflammation and pre-eclampsia. *Semin Fetal Neonatal Med* 2006; 11(5): 309-16. [\[CrossRef\]](#)
23. Kim JS, Romero R, Cushenberry E, Kim YM, Erez O, Nien JK, et al. Distribution of CD14+ and CD68+ macrophages in the placental bed and basal plate of women with preeclampsia and preterm labor. *Placenta* 2007; 28(5-6): 571-6. [\[CrossRef\]](#)
24. Redman CW, Sargent IL. Pre-eclampsia, the placenta and the maternal systemic inflammatory response—a review. *Placenta* 2003; 24(Suppl A): 21-7. [\[CrossRef\]](#)
25. Reister F, Frank HG, Kingdom JC, Heyl W, Kaufmann P, Rath W, et al. Macrophage-induced apoptosis limits endovascular trophoblast invasion in the uterine wall of preeclamptic women. *Lab Invest* 2001; 81(8): 1143-52. [\[CrossRef\]](#)
26. Renaud SJ, Postovit LM, Macdonald-Goodfellow SK, McDonald GT, Caldwell JD, Graham CH. Activated macrophages inhibit human cytotrophoblast invasiveness in vitro, *Biol Reprod* 2005; 73(2): 237-43. [\[CrossRef\]](#)