



Nontuberculous Mycobacterial Infection in a Patient Diagnosed with Ankylosing Spondylitis

CASE REPORT

Nigar Dirican, Merve Pınar, Seven Erturk, Şule Atalay, Munire Çakır

ABSTRACT

Nontuberculous mycobacteria are common microorganisms in nature and are particularly found in soil and water. They cause pulmonary infections, lymphadenitis, disseminated infections, localized skin and soft tissue infections, tendon–bone–articular infections, and catheter infections. *Mycobacterium xenopi* is categorized as a slow-growing mycobacterium. Pulmonary infections caused by *M. xenopi* have been found to be associated with chronic obstructive pulmonary disease (COPD), underlying diseases such as bronchiectasis, and immunosuppression. This article aims to present an atypical mycobacterial infection in a patient in whom anti-tumor necrosis factor alpha therapy was being planned and who was followed up with diagnoses of ankylosing spondylitis and COPD.

Keywords: COPD, mycobacteria, ankylosing spondylitis

INTRODUCTION

Nontuberculous mycobacteria (NTM) were accepted to be pathogenic in the 1950s, with more than 150 classes identified since then (1). They are common microorganisms in nature and are particularly found in soil and water. They primarily cause pulmonary infections, lymphadenitis, disseminated infections, localized skin and soft tissue infections, tendon–bone–articular infections, and catheter infections (2). NTM have a broad clinical spectrum ranging from asymptomatic to life-threatening diseases. The incidence of infections resulting in significant mortality and morbidity rates has increased over the past decade (3). Moreover, their incidence is expected to increase until 2050, given the growing geriatric population and higher prevalence of nontuberculous mycobacterial infections among this population (4).

Mycobacterium xenopi is a slow-growing mycobacterium. It is isolated from bathing water, tap water, and soil and environmental water. Pulmonary infections are associated with underlying diseases such as chronic obstructive pulmonary disease (COPD), bronchiectasis, and immunosuppression.

This report presents an atypical mycobacterial infection detected in a patient followed-up with diagnoses of COPD and ankylosing spondylitis and in whom anti-tumor necrosis factor alpha (TNF α) therapy was being planned.

CASE REPORT

A 51-year-old male was referred to our polyclinic as he suffered from frequent high fever, productive cough, and dyspnea that continued for over a year. The patient was followed for 30 years with a diagnosis of ankylosing spondylitis, and the rheumatology clinic transferred the patient to our clinic because of a planned anti-TNF α therapy. He stated that he lived in France and that he had received antibiotics during his periods of fever without any sign of recovery. He had a smoking history of 35 pack/years and received bronchodilator therapy for COPD. Laboratory test results showed the whole blood count and erythrocyte sedimentation rate to be normal, and the C-reactive protein level was found to be 12 mg/L. Posteroanterior chest radiography revealed loss of volume at the right hemithorax, fibrotic alterations in the right apical, and a cavity-like formation in the left hemithorax (Figure 1). Thoracic computerized tomography (CT) detected sequel fibrotic alterations in the apical region of the right lung accompanied by traction bronchiectasis; an infiltrative formation of irregular densities in the lateral upper lobe of the left lung; and interrelated, thick, and irregular cavitory formations in the upper lobe (Figure 2). Sputum and bronchoalveolar lavage (BAL), which were presented three times, were stained with Ehrlich–Ziehl–Neelsen method and examined by microscopy. Direct examination revealed no acid-fast bacteria. The BACTEC MGIT 960 TB

Department of
Chest Diseases,
Süleyman Demirel University
Faculty of Medicine,
Isparta, Turkey

Submitted
07.01.2016

Accepted
08.02.2016

Correspondence
Dr. Nigar Dirican,
Department of
Chest Diseases,
Süleyman Demirel University
Faculty of Medicine,
Isparta, Turkey
Phone: +90 505 860 69 64
e.mail:
nigardirican@yahoo.com

©Copyright 2016
by Erciyes University Faculty of
Medicine - Available online at
www.erciyesmedj.com

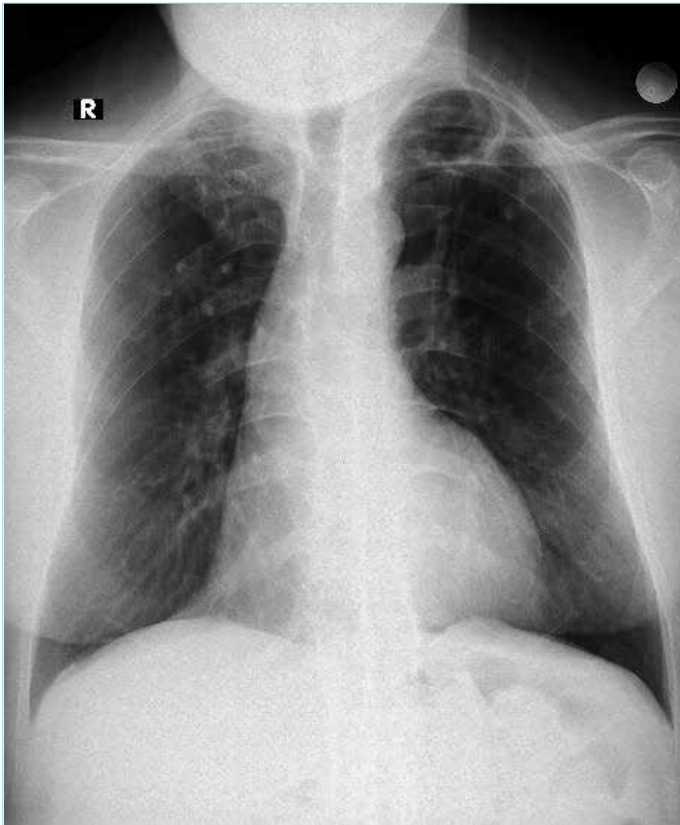


Figure 1. PA chest X-ray

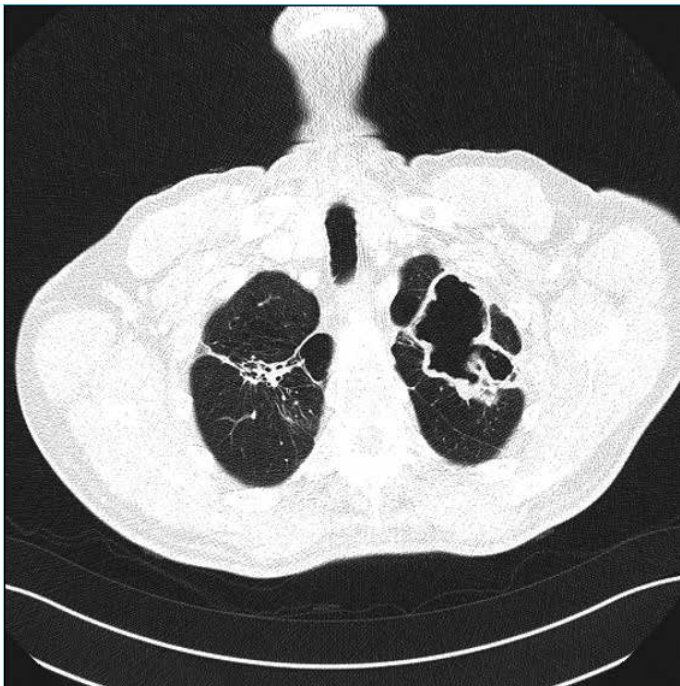


Figure 2. Thoracic CT
CT: computerized tomography

system (Becton Dickinson, Sparks, MD, USA) and Löwenstein-Jensen (LJ) (Becton Dickinson) media were used for tuberculosis cultures. Of two samples added to the BACTEC MGIT 960 system, one transmitted signals on day 35 and the other transmitted signals on day 37, which was followed by an identification process

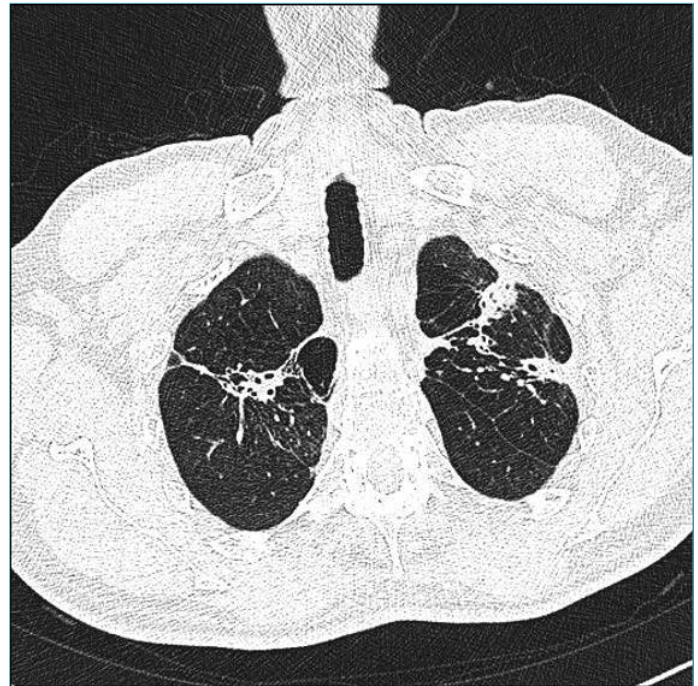


Figure 3. Control thoracic CT
CT: computerized tomography

that revealed NTM. No growth was detected in the LJ medium on day 57. Growths studied with the line probe assay were reported as *M. xenopi*. Triple therapy (clarithromycin, rifampicin, and ethambutol) was initiated for the patient. No fever was observed as of the first month of therapy, and he clinically responded to the therapy. The patient's sputum culture submitted in months 4 and 8 during the therapy period suggested no bacterial growth. After the first year, thoracic CT detected a reduction in the size of the cavity lesion in the left upper lobe (Figure 3).

DISCUSSION

M. xenopi represents an opportunistic mycobacterial pathogen that triggers infections with significant mortality and morbidity rates in individuals with normal and suppressed immune systems. It has a growing clinical importance. The incidence of pulmonary infections caused by *M. xenopi* remains unclear; however, in a large-scale study, it was reported that it comprised 8% of all NTM isolated from pulmonary samples (5).

Although *M. xenopi* is observed rather occasionally worldwide, it is a frequent cause of nontuberculous mycobacterial infections detected in Canada, the United Kingdom, and France (6). Our case is of particular importance in this regard as the patient mentioned that he had lived in France for a long time.

Nontuberculous mycobacterial-associated pulmonary infections are rare among young individuals and those without predisposing risk factors. It is more prevalent in patients with pulmonary diseases such as underlying COPD, bronchiectasis, pneumoconiosis, sequela tuberculosis, and malignancy. Risk factors also include chronic renal failure, HIV infection, steroid use, and diabetes mellitus. Our patient was an active smoker and was followed up with diagnoses of ankylosing spondylitis and COPD.

As nontuberculous mycobacterial strains are common in nature and environment, a strain might be detected as a result of environmental contamination, primarily non-sterile water resources. The gastrointestinal tract and direct inoculation are main intake routes alongside inhalation, which is the primary route. Not all patients with mycobacterial growth in the sputum or lavage fluid are considered to have nontuberculous mycobacterial pulmonary disease. Therefore, relevant diagnosis criteria must be set to determine which nontuberculous mycobacterial strain is of clinical importance (7). We considered nontuberculous mycobacterial growth as a factor as it was the case in our patient's three sputum cultures and BAL.

The radiological characteristics of NTM include cavitory lesions, nodules, bronchiectasis, and consolidation (8). Radiologically, cavity and large nodules (≥ 5 mm) have been reported to be strongly related to the microbiological criteria of *M. xenopi* (6). We detected bronchiectasis and bilateral apical cavitory lesions with irregular membranes in our patient's thoracic CT scan.

The study included 40 patients infected by *M. xenopi* and found COPD to be the most frequent comorbidity, which was associated with poor response to therapy. The patients did not exhibit immunosuppression or HIV infection. Chest radiography indicated largely unilateral and more frequent cavitory lesions (73.9%). The patients detected no radiological and clinical progression in three years of therapy; half of them experienced regression, and the rest presented no change (8).

As is the case with tuberculosis, anti-TNF α therapies are extremely potent and are new predisposing factors in the development of pulmonary infections associated with NTM. A recent report by Winthrop et al. (9) detected a significantly high NTM disease incidence among individuals who received anti-TNF α therapy in a group largely comprising patients with rheumatoid arthritis. Our patient was followed up with a diagnosis of ankylosing spondylitis, and he was referred to us for an anti-TNF α therapy planning. Therefore, one should act carefully when administering anti-TNF α therapy to patients with nontuberculous mycobacterial-associated pulmonary disease or suspected individuals (7).

Empirical therapy is not recommended for patients suspected of nontuberculous mycobacterial-associated pulmonary infection. Therefore, relevant diagnosis criteria must be verified to establish that the nontuberculous mycobacterial strain is of clinical importance. A recent guide has suggested that ethambutol, rifampicin, and clarithromycin are administered to patients with *M. xenopi*-associated pulmonary infections for a minimum of one year. One may substitute these medications with quinolones, preferably with moxifloxacin (7). However, optimum therapy regimens are yet to be established for many nontuberculous mycobacterial infections including those of *M. xenopi*. The failure of NTM to respond in vivo antibiotics, independent of in vitro susceptibility test results, represents the most important obstacle that prevents an effective therapy. Patients infected by *M. xenopi* have poor prognosis with five-year mortality rates of 51–69% after diagnosis (10).

CONCLUSION

Although diagnostics has witnessed important developments enabled by more sensitive laboratory techniques, to date, there is no reliable and effective therapy regimen. Currently, this is a growing issue for clinicians. Clinicians should take clinical and radiological characteristics into account and be attentive to nontuberculous mycobacterial infections for patients with underlying pulmonary diseases and particularly anti-TNF α therapy is planned.

Informed Consent: Written informed consent was obtained from the patient.

Peer-review: Externally peer-reviewed.

Authors' Contributions: Conceived and designed the experiments or case: ND. Performed the experiments or case: ND, MP, SE. Analyzed the data: ND, SA, MC. Wrote the paper: ND, MP. All authors have read and approved the final manuscript.

Conflict of Interest: No conflict of interest was declared by the authors.

Financial Disclosure: The authors declared that this study has received no financial support.

REFERENCES

1. Tortoli E. Microbiological features and clinical relevance of new species of the genus *Mycobacterium*. *Clinical Microbiology Reviews* 2014; 27(4): 727-52. [CrossRef]
2. Cassidy PM, Hedberg K, Saulson A, McNelly E, Winthrop KL. Nontuberculous mycobacterial disease prevalence and risk factors: a changing epidemiology. *Clin Infect Dis* 2009; 49(12): 124-9. [CrossRef]
3. Mirsaeidi M, Machado RF, Garcia JGN, Schraufnagel DE. Nontuberculous mycobacterial disease mortality in the United States, 1999–2010: a population-based comparative study. *PLoS ONE* 2014; 9: e91879. [CrossRef]
4. Mirsaeidi M, Farshidpour M, Ebrahimi G, Aliberti S, Falkinham III JO. Management of nontuberculous mycobacterial infection in the elderly. *European Journal of Internal Medicine* 2014; 25(4): 356-63. [CrossRef]
5. Hoefsloot W, van Ingen J, Andrejak C, Angeby K, Bauriaud R, Bemer P, et al. The geographic diversity of nontuberculous mycobacteria isolated from pulmonary samples: an NTM-NET collaborative study. *Eur Respir J* 2013; 42(6): 1604-13. [CrossRef]
6. Marras TK, Wagnetz U, Jamieson FB, Patsios DA. Chest computed tomography predicts microbiological burden and symptoms in pulmonary *Mycobacterium xenopi*. *Respirology* 2013; 18(1): 92-101. [CrossRef]
7. Griffith DE, Aksamit T, Brown-Elliott BA, Catanzaro A, Daley C, Gordin F. An official ATS/IDSA statement: diagnosis, treatment, and prevention of nontuberculous mycobacterial diseases. *Am J Respir Crit Care Med* 2007; 175(4): 367-416. [CrossRef]
8. Marusić A, Katalinić-Janković V, Popović-Grlje S, Janković M, Mazuranić I, Puljić I et al. *Mycobacterium xenopi* pulmonary disease Epidemiology and clinical features in non-immunocompromised patients. *J Infect* 2009; 58(2): 108-12. [CrossRef]
9. Winthrop KL, Chang E, Yamashita S, Iademarco MF, LoBue PA. Nontuberculous mycobacteria infections and antitumor necrosis factor- α therapy. *Emerg Infect Dis* 2009; 15(10): 1556-61. [CrossRef]
10. Andrejak C, Thomsen VØ, Johansen IS, Riis A, Benfield TL, Duhaat P et al. Nontuberculous pulmonary mycobacteriosis in Denmark: incidence and prognostic factors. *Am J Respir Crit Care Med* 2010; 181(5): 514-21. [CrossRef]