






This work is licensed under a Creative Commons Attribution-NonCommercial 4.0 International License.

## Successful Management of Post-traumatic High-Flow Priapism by Super-Selective Coil Embolization: A Case Report

Mohamed Ahmed Abd El Salam<sup>1</sup> , Shady Nabil Mashhour<sup>2</sup> , Omar Abdulsalam Azzazi<sup>1</sup> 

### ABSTRACT

Priapism is a rare andrological emergency characterized by a prolonged penile erection that is not provoked by sexual excitation or stimulation and lasts longer than 4 hours. There are three different types of this emergency that can be encountered in clinical practice based on the episode history and pathophysiology, including veno-occlusive (ischemic or low-flow priapism), arterial (non-ischemic or high-flow priapism), and stuttering priapism. High-flow priapism is the less common type, which accounts for approximately 5%–10% of cases. This type is caused mainly by trauma to the penis, perineum, or a pelvis fracture that may lead to an arterio-cavernous fistula or pseudoaneurysm with a subsequent uncontrolled arterial inflow to the penis. This type of emergency is under-reported, and a low number of cases have been documented. Therefore, the effectiveness, encountered risks, as well as management outcomes are still limited. Hereby, we report a case of a 29-year-old male who presented to the emergency department complaining of a persistent painless penile erection for 2 weeks following perineal trauma (falling astride). A multidisciplinary clinical evaluation and management by a selective embolization technique are discussed in this case report.

**Keywords:** High flow, non-ischemic, post-traumatic, priapism, selective embolization

**Cite this article as:**  
Abd El Salam MA,  
Mashhour SN, Azzazi OA.  
Successful Management of  
Post-traumatic High-Flow  
Priapism by Super-Selective  
Coil Embolization: A Case  
Report. Erciyas Med J  
2019; 41(2): 205-8.

### INTRODUCTION

Priapism is a rare andrological emergency with an estimated incidence of 1.5 per 100,000 males, which has bimodal peaks: the first peak affects mainly children with sickle cell disease aged 5–10 years, and the second peak affects sexually active adult males aged 20–50 years. It is characterized by a prolonged penile erection persisting for more than 4 hours, which is not related to sexual arousal. Generally, it can be classified into three main types: ischemic (low-flow or veno-occlusive), arterial (high-flow or non-ischemic), and stuttering (recurrent or intermittent) priapism (1, 2).

High-flow priapism is a rare type, accounting for 5%–10% of cases (3). Notably, high-flow priapism was first described by Burt et al. in 1960 when a man developed a persistent penile erection following traumatic coitus (4). The main precipitating cause is genito-perineal trauma or following a pelvis fracture leading to an arterio-cavernous fistula or pseudoaneurysm and uncontrolled arterial inflow with subsequent sinusoidal over-distension. The uncontrolled blood inflow and over-distension of lacunar spaces produces the compression of subtunical veins against the thick and tough tunica albugenia, causing a marked reduction of the venous outflow (5). High-flow priapism, also known as arterial or non-ischemic priapism, is characterized by a painless and prolonged penile erection following genital trauma. A penile duplex assessment is essential to differentiate between high-flow and low-flow priapism, whereas in high-flow priapism cavernosal arterial blood flow is exaggerated. In addition, blood gas analysis shows proper blood oxygenation as compared to low-flow priapism, which shows ischemic pattern (6, 7).

Conservative management is considered as the first step in the management of these cases, under watchful observation for 24–48 hours, during which perineal compression and application of ice are performed, aiming at the induction of cavernosal vasospasm to facilitate a clot formation and fistula obliteration (8, 9). However, if the condition does not improve, angiography along with selective arterial embolization is to be considered. Several materials have been used in this technique, including permanent (i.e., microcoils, polyvinyl particles, and acrylic glue) and temporary (i.e., autologous blood clots, gel foam, or sponge). It is worth mentioning that all of these occlusive agents are almost equal in their efficacy; however, permanent materials have a higher rate of complications, but a lower recurrence rate as compared to the temporary materials (10).

On the other hand, surgical ligation of the fistula should only be preserved in those patients who did not achieve detumescence after selective arterial embolization due to its inevitable side effects, including residual erectile dysfunction (as high as 50%), penile gangrene, cavernosal abscess, and gluteal ischemia. Interestingly, post-traumatic

<sup>1</sup>Department of Andrology,  
Sexology and STDs, Kasr  
Alainy Faculty of Medicine,  
Cairo University, Cairo, Egypt

<sup>2</sup>Department of Diagnostic and  
Interventional radiology, Kasr  
Alainy Faculty of Medicine,  
Cairo University, Cairo, Egypt

**Submitted**  
15.02.2019

**Accepted**  
19.03.2019

**Available Online Date**  
13.05.2019

**Correspondence**  
Mohamed Ahmed Abd El Salam,  
Andrology, Sexology & STDs,  
Faculty of Medicine, Cairo  
University, (9) Montaser  
buildings, Gamal AbdEl Naser  
St., 11731, Hadayek Helwan,  
Cairo, Egypt  
Phone: +20/0223756219  
e.mail: moh\_756@yahoo.com

©Copyright 2019 by Erciyas  
University Faculty of Medicine -  
Available online at  
www.erciyasmedj.com

high-flow priapism is rare as a urologic emergency, and the cases mentioned in the literature are under-reported. We report a case of a post-traumatic high-flow priapism complicated by arterio-cavernous fistula after blunt perineal trauma that was managed with selective arterial embolization.

## CASE REPORT

We report a case of a 29-year-old male patient who presented to the emergency department in our hospital complaining of prolonged painless penile erection for about 2 weeks following a blunt trauma to the perineum after falling astride. On clinical examination, the vital signs were normal, but the penis was semi-erected, non-tender, and proper capillary refill. A blood gas analysis of the cavernosal blood was conducted, and it showed normal oxygenation with no signs of an acid-base imbalance, as shown in Table 1. In addition, penile duplex examination showed the accentuation of blood flow in both the cavernosal arteries. All the above findings denoted a case of post-traumatic high-flow priapism. The patient was admitted for watchful expectancy and conservative treatment, but no detumescence happened for 2 weeks. Afterwards, he was sent to the interventional radiology department to undergo angiography to assess the presence of arterio-cavernosal fistula or pseudoaneurysm.

### Selective Embolization Technique

The patient was draped and prepped on both groins according to standard sterilization techniques. A 5 Fr. Sheath (Cordis, Miami, Florida, USA) was placed in the right femoral artery using the Seldinger technique under local anesthesia (lidocaine 1%). Diagnostic angiography of the left internal iliac and right internal iliac arteries using a standard 5Fr. Cobra catheter (Imager, Boston Scientific Corporation, USA) was performed.

Angiography showed a fistulous communication between the right bulbo-urethral artery and corpora cavernosa with intense arterial blush over the right corpora (Fig. 1). The feeding artery was superselectively catheterized using a 2.7 Fr. microcatheter (Progreat Terumo Medical Corporation, Tokyo) down to the fistulous site (Fig. 2), further confirming the fistulous nature. Two soft coils, 3 mm x 6 cm and 2 mm x 4 cm (IDC Boston Scientific Corporation, USA), were deployed. Afterwards, the microcatheter control angiogram and right internal iliac angiogram confirmed a complete closure of the fistula (Fig. 3), and immediate partial detumescence was observed.

Then, the patient was discharged after 24 hours from selective embolization, where he was prescribed anti-fibrotic measures (Pentoxiphiline 400 mg SR tab twice daily, Vitamin E 1000 mg cap once daily, and Sildenafil 50 mg tab once daily) to be followed up after a 1- and 3-month interval. Interestingly, the patient regained normal morning erections as well as coital erections. In addition, penile duplex assessment was performed 3 months after the selective embolization showing normal penile hemodynamics and good erection in response to 20 µg PGE1.

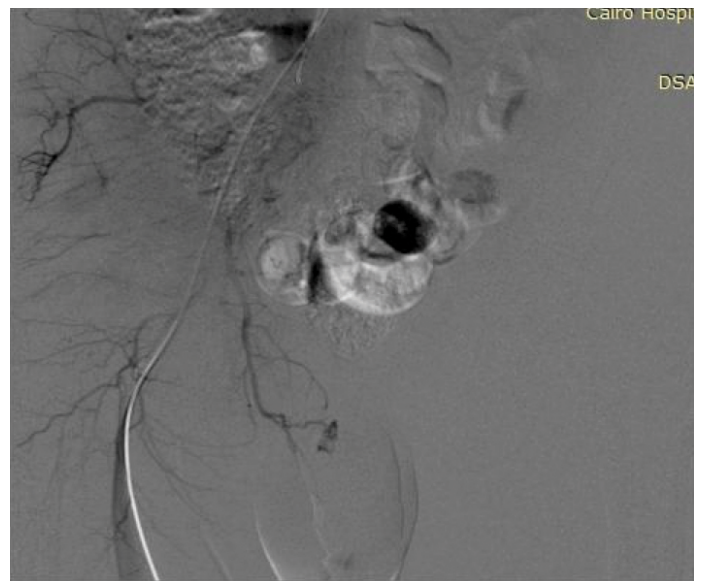
## DISCUSSION

High-flow priapism is a less common type of priapism caused by genito-perineal trauma with laceration of the cavernous artery, leading to the formation of arterio-cavernosal fistula with subse-

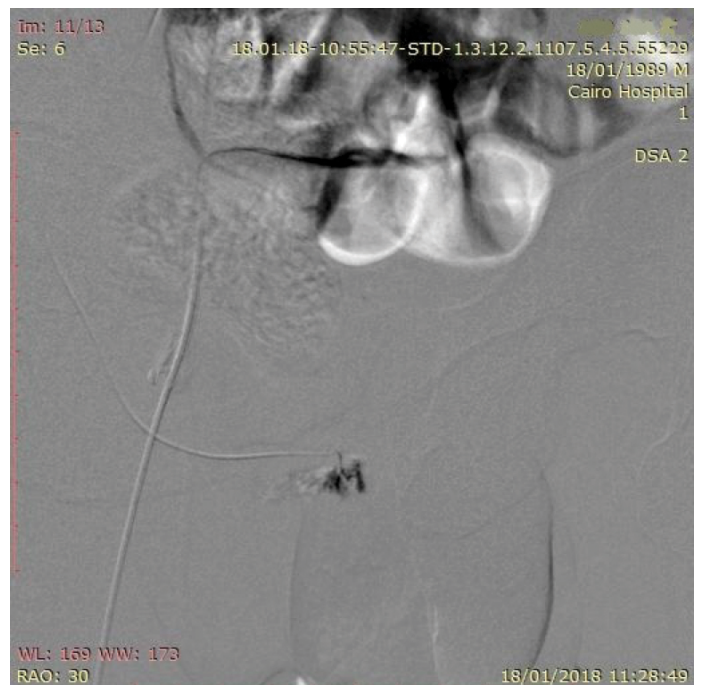
**Table 1.** Blood gas analyses of aspirated blood from corpora cavernosa

PH	PCO <sub>2</sub>	PO <sub>2</sub>	SO <sub>2</sub> %	HCO <sub>3</sub>	BE
7.44	39 mmHg	90 mmHg	97%	26.5	2.3 mmol/L

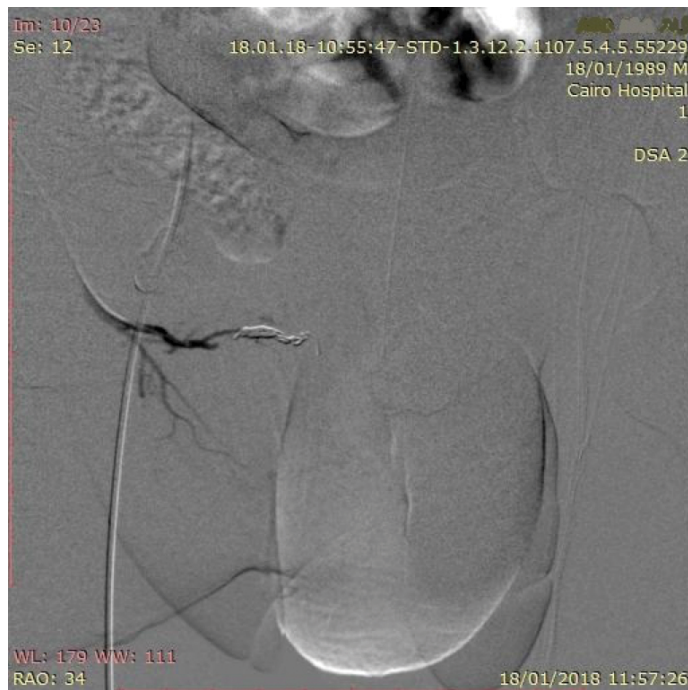
PH: Hydrogen ion concentration; PCO<sub>2</sub>: Partial pressure of carbon dioxide; PO<sub>2</sub>: Partial pressure of oxygen; SO<sub>2</sub>: Oxygen saturation; HCO<sub>3</sub>: Bicarbonate level; BE: Base excess (positive number) or base deficit (negative number)



**Figure 1.** Angiography showing a fistulous communication between the right bulbo-urethral artery and corpora cavernosa



**Figure 2.** Super-selective catheterization of the feeding artery using a 2.7Fr microcatheter down to the fistulous site



**Figure 3. Confirmation of fistula closure by microcatheter control angiogram and right internal iliac angiogram**

quent uncontrolled arterial inflow to the lacunar spaces of the cavernous bodies (3). Clinical assessment, penile duplex assessments of penile hemodynamics, as well as blood gas analysis of blood aspirate from corpora cavernosa, are essential to confirm the diagnosis and differentiate high-flow from low-flow and stuttering priapism (2, 6).

The management of high-flow priapism is a step-ladder approach, whereas conservative management is the first step of management, including perineal compression and ice compresses, with an overall spontaneous achievement of detumescence in approximately 60% of cases (8, 9). If there is no improvement, arteriography is the second line of management to confirm diagnosis, localize the fistula or pseudoaneurysm, as well as to obliterate it using different materials (10). To date, there have been many debates concerning the best material used for embolization; however, there is a general consensus on the superiority of temporary materials (11, 12), such as autologous blood clots, gelfoam, or sponge, with a minimal risk concerning complications, but unfortunately recurrences may be encountered. On the other hand, permanent materials, such as microcoils, polyvinyl particles, and acrylic glue, can be used to prevent the recurrence; however, these may carry a higher risk of complications, especially when the embolization is performed in a bilateral fashion (11–17). Few nonrandomized studies have reported success rates of selective embolization technique up to 89%; however, there are no robust data to demonstrate the relative merits of different substances. Several reports have mentioned potential complications due to selective embolization, which are relatively high with the use of permanent materials and in bilateral occlusion, including erectile dysfunction, penile gangrene, gluteal ischemia, cavernositis, and perineal abscess (18, 19).

Our patient showed no improvement in response to conservative treatment; thus, angiography was performed to confirm the diag-

nosis and obliterate the fistula with a selective arterial embolization. Interestingly, spontaneous penile detumescence was achieved after this procedure, and the patient regained normal erectile function, as well as normal penile hemodynamics, as evident by the penile duplex evaluation after 3 months. In addition, the patient reported no post-embolization complications.

## CONCLUSION

High-flow priapism is a less common type of priapism that may be encountered due to genito-perineal trauma, leading to uncontrolled arterial blood flow with subsequent prolonged painless penile erection. Notably, clinical assessment, penile duplex evaluation of penile hemodynamics, as well as blood gas analysis of the cavernosal aspirate, is essential in making a proper diagnosis. Conservative management is the first step of treatment; however, if no detumescence is achieved, selective arterial embolization should be considered. Finally, surgical ligation of the fistulous communication should be attempted only in case of therapy embolization failure due to its unfavorable outcomes.

**Informed Consent:** A written informed consent was obtained from the patient who participated in this case report.

**Peer-review:** Externally peer-reviewed.

**Author Contributions:** All authors have actively participated in this case report, including diagnosis and management. In addition, all authors have participated in case report writing, revision and approved the final version of the manuscript.

**Conflict of Interest:** There is no conflict of interest to be declared.

**Financial Disclosure:** The authors declared that this study has received no financial support.

## REFERENCES

1. Broderick GA, Kadioglu A, Bivalacqua TJ, Ghanem H, Nehra A, Shamloul R. Priapism: pathogenesis, epidemiology, and management. *J Sex Med* 2010;7(1 Pt 2): 476–500. [CrossRef]
2. Salonia A, Eardley I, Giuliano F, Hatzichristou D, Moncada I, Vardi Y, et al. European Association of Urology guidelines on priapism. *Eur Urol* 2014; 65(2): 480–9. [CrossRef]
3. Hakim LS, Kulaksizoglu H, Mulligan R, Greenfield A, Goldstein I. Evolving concepts in the diagnosis and treatment of arterial high flow priapism. *J Urol* 1996; 155(2): 541–8. [CrossRef]
4. Burt FB, Schirmer HK, Scott WW. A new concept in the management of priapism. *J Urol* 1960;83: 60–1. [CrossRef]
5. Montague DK, Jarow J, Broderick GA, Dmochowski RR, Heaton JP, Lue TF, et al. American Urological Association guideline on the management of priapism. *J Urol* 2003; 170(4 Pt 1): 1318–24. [CrossRef]
6. Muneer A, Alhajjar H, Ralph D. Recent advances in the management of priapism. *F1000Research*. 2018;7:37. [CrossRef]
7. Burnett AL, Sharlip ID. Standard operating procedures for priapism. *J Sex Med* 2013; 10(1): 180–94. [CrossRef]
8. Ilkay AK, Levine LA. Conservative management of high-flow priapism. *Urology* 1995; 46(3): 419–24. [CrossRef]
9. Arango O, Castro R, Dominguez J, Gelabert A. Complete resolution of post-traumatic high-flow priapism with conservative treatment. *Int J Impot Res* 1999; 11(2): 115–7. [CrossRef]
10. Kim KR. Embolization Treatment of High-Flow Priapism. *Semin Intervent Radiol* 2016; 33(3): 177–81. [CrossRef]



11. Shigehara K, Namiki M. Clinical Management of Priapism: A Review. *World J Mens Health* 2016; 34(1): 1–8. [\[CrossRef\]](#)
12. Numan F, Cakirer S, Işlak C, Oğüt G, Kadioğlu A, Cayan S, et al. Post-traumatic high-flow priapism treated by N-butyl-cyanoacrylate embolization. *Cardiovasc Intervent Radiol* 1996; 19(4): 278–80. [\[CrossRef\]](#)
13. Sánchez-López S, González-Gómez S, Di Lizio-Miele K, González-Gómez J. High-flow priapism treated with superselective transcatheter embolization using polyvinyl alcohol particles. *SAGE Open Med Case Rep* 2017; 5: 2050313X17693179. [\[CrossRef\]](#)
14. Jarungkiattikhajorn W. Post-Traumatic High-Flow Priapism Treated with Gelatin Sponge Embolization: A Case Report. *Bangkok Med J* 2014; 8: 75–8. [\[CrossRef\]](#)
15. Wear JB Jr, Crummy AB, Munson BO. A new approach to the treatment of priapism. *J Urol* 1977; 117(2): 252–4. [\[CrossRef\]](#)
16. Numan F, Cantasdemir M, Ozbayrak M, Sanli O, Kadioglu A, Hasanefendioglu A, et al. Posttraumatic nonischemic priapism treated with autologous blood clot embolization. *J Sex Med* 2008; 5(1): 173-9.
17. Liu BX1, Xin ZC, Zou YH, Tian L, Wu YG, Wu XJ, et al. High-flow priapism: superselective cavernous artery embolization with microcoils. *Urology* 2008; 72(3): 571–3; discussion 573–4. [\[CrossRef\]](#)
18. Tønseth KA, Egge T, Kolbenstvedt A, Hedlund H. Evaluation of patients after treatment of arterial priapism with selective micro-embolization. *Scand J Urol Nephrol* 2006; 40(1): 49–52. [\[CrossRef\]](#)
19. Görlich J, Ermis C, Krämer SC, Fleiter T, Wisianowsky C, Basche S, et al. Interventional treatment of traumatic priapism. *J Endovasc Ther* 2002; 9(5): 614–7. [\[CrossRef\]](#)