



Tick in Both External Auditory Canals: An Extremely Rare Case Report

Deniz Avcı

ABSTRACT

Foreign bodies in the external auditory canal (EAC) are common conditions experienced in the otorhinolaryngology practice. The most commonly implicated foreign bodies in EAC include cotton bud, paper, legume, fruit seed, nuts, toy parts, pen tip, and rubber. However, living objects are rarely reported. The presence of a tick in both EACs is extremely rare. In this report, we present a 55-year-old female patient who was detected with tick in both EACs, which is an extremely rare case in the literature. In the patients presenting with the symptoms of foreign bodies in EAC, living objects should be kept in mind, particularly those lead to serious morbidity and mortality such as ticks that are mostly presented by people living in rural areas. Doctors in endemic and rural areas should be more careful about this issue.

Keywords: External auditory canal, foreign body, tick

INTRODUCTION

Foreign bodies in the external auditory canal (EAC) are common conditions experienced in the otorhinolaryngology practice, particularly in children aged below 5 years. In adults, however, these conditions occur less frequently, mostly after ear picking and trauma (1).

The most commonly implicated foreign bodies in EAC include cotton bud, paper, legume, fruit seed, nuts, toy parts, pen tip, and rubber. However, living objects are rarely reported (1). The presence of a tick in both EACs is extremely rare (2).

In this report, we present an adult patient who was detected with tick in both EACs, which is an extremely rare case in the literature.

CASE REPORT

A 55-year-old female patient presented to our clinic in July 2018 with a three-day history of pain, pruritus, aural fullness, a sensation of the presence of a foreign body within EAC, and occasional bleeding in both ears. The otoendoscopic examination revealed engorged living ticks with tick larvae, tick feces, and blood clots in both EACs (Fig. 1). Under otoendoscopy without anesthesia, both tick bodies were removed in one piece by grasping the ticks at their heads using alligator forceps without crushing the ticks' abdomen causing any complications (Fig. 2). After the removal of the ticks, both tympanic membranes were found to be intact. Subsequently, to prevent the development of new ticks from the larvae and as a prophylaxis for otitis externa, both EACs were rinsed with 96% alcohol solution (Biorad; necm kimya, Istanbul, Turkey), and then the fluid was aspirated. In doing so, both the larvae and the tick feces were also removed from both EACs. Topical ciprofloxacin eardrop (Siprogut; Bilim, Istanbul, Turkey) was prophylactically administered to the patient. Patient history revealed that the patient lived in a rural area, dealt with livestock, and had no systemic symptoms suggestive of Crimean-Congo hemorrhagic fever (CCHF) such as fever and hemorrhage. Moreover, the patient indicated that she never noticed the insertion of the ticks into her ears. Routine laboratory tests including complete blood count (CBC), biochemical analysis, creatine phosphokinase (CPK), bleeding times, and international normalized ratio (INR) were normal. After the completion of the intervention in our clinic, the patient was referred to the Infectious Diseases clinic. In that clinic, the patient was informed about tick-borne infections and their symptoms. Thereafter, the patient was followed up at polyclinic visits for two weeks; and no disease was observed throughout this period. The ticks removed were analyzed in the Department of Parasitology and were both revealed to be adult female ear ticks (*Otobius megnini*) belonging to the Argasidae family. Written informed consent for the case presentation was obtained from the patient.

Cite this article as:
Avcı D. Tick in Both External Auditory Canals: An Extremely Rare Case Report. Erciyes Med J 2019; 41(2): 215-7.

Department of
Otorhinolaryngology, Nevşehir
State Hospital,
Nevşehir, Turkey

Submitted
04.03.2019

Accepted
13.03.2019

Available Online Date
12.05.2019

Correspondence
Deniz Avcı,
Department of
Otorhinolaryngology,
Nevşehir State Hospital,
50130 Nevşehir, Turkey
Phone: +90 506 584 95 67
e.mail:
deniz.avci@hotmail.com

©Copyright 2019 by Erciyes
University Faculty of Medicine -
Available online at
www.erciyesmedj.com

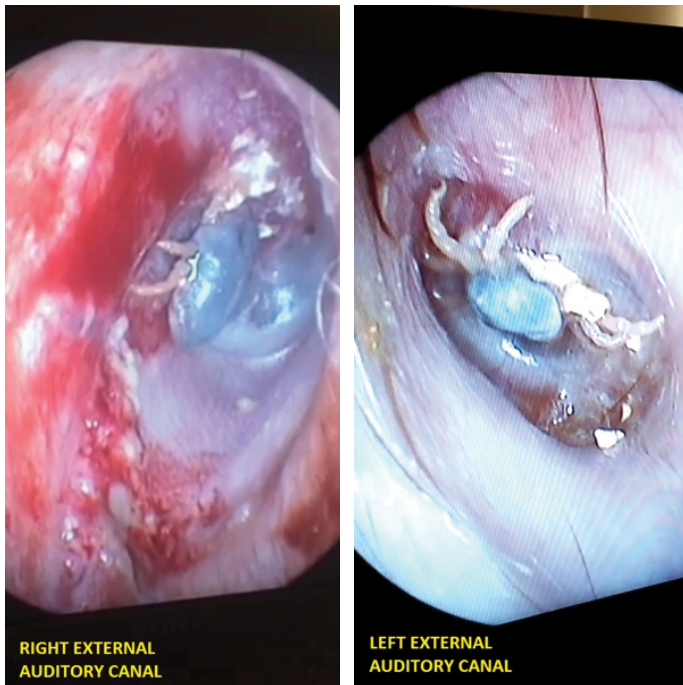


Figure 1. Tick in right and left external auditory canals

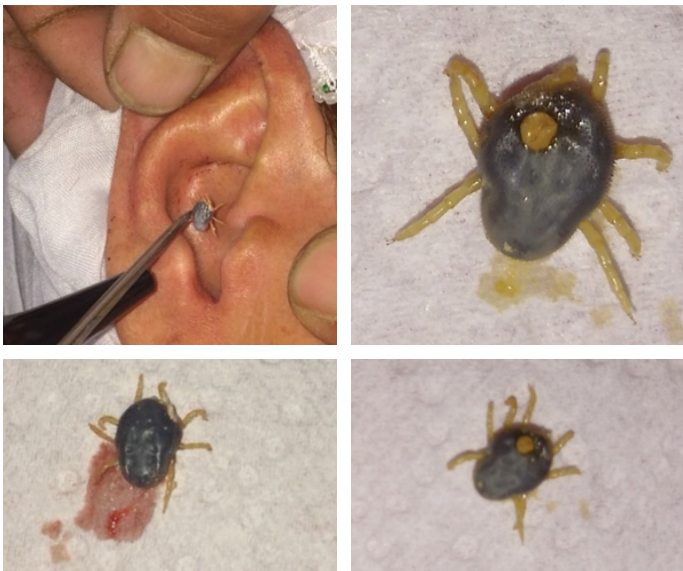

Figure 2. Removal of the ticks from the external auditory canals and macroscopic view of the ticks

DISCUSSION

Foreign bodies in EAC represent the most common type of foreign bodies encountered in the otorhinolaryngology practice. These foreign bodies can be asymptomatic and may present with symptoms including pain, tinnitus, ear discharge, bleeding, hearing loss, aural fullness, and ear congestion (3).

Successful removal of a foreign body in EAC requires appropriate equipment, good patient cooperation, and more importantly, examination of EAC by an otorhinolaryngologist. Olajuyin et al. (3) evaluated 136 patients, and they reported that the rates of complications after the removal of ticks by otorhinolaryngologists and

non-otorhinolaryngologists were 15.7% and 68.1%, respectively. Rigid endoscopy has recently emerged as a popular and practical technique in the removal of foreign bodies in EAC. Accordingly, we used a 0-degree rigid endoscope for the removal of the ticks in our patient.

Common complications occurring after the removal of foreign bodies in EAC include EAC laceration, bleeding, otitis externa, tympanic membrane perforation, and ossicular injury (3). In our patient, no complication was observed after the removal of the ticks.

Literature reviews indicate that the presence of a tick in EAC is an extremely rare entity (2). When PubMed and Web of Science database were scanned with keywords “tick” and “external auditory canal”, 33 cases in PubMed database and 11 cases in Web of Science database were obtained. Meaningfully, we present a rare anatomic localization of tick in this report, and our patient was an interesting case since she presented with a tick in both EACs. Therefore, we believe that this case report will contribute to the literature. Its symptoms become noticeable after the tick becomes engorged by sucking blood. In none of the cases reported in the literature, tick-borne infection has been observed following successful removal of the ticks from EAC (2). Similarly, no infection was observed in our patient after the removal of the ticks.

Almost all ticks belong to one of two major families, Argasidae and Ixodidae. Ticks are spread life-threatening infectious diseases such as typhus (*Rickettsia conorii*), Q fever (*Coxiella burnetii*), tularemia (*Francisella tularensis*), Lyme disease (*Borrelia burgdorferi*), and CCHF (Nairovirus). In particular, the incidence of CCHF has recently increased in Turkey, with a peak incidence seen in June and July and a reported mortality of 15%–70% in human populations. The CCHF virus is transmitted to people either by tick bites or through contact with infected animal blood or tissues. On the other hand, bites are mostly seen in the people working at slaughterhouses, living in rural areas, and dealing with livestock (4, 5).

Literature indicates that a tick bite in EAC can result in tinnitus, facial nerve palsy, and taste disorder, though rarely (6–8).

When removing a tick in EAC, the tick should be removed in one piece by grasping at its head or at its legs, if its head is embedded in the skin, without crushing its abdomen with alligator forceps (7). In our patient, the removal of both ticks was achieved by following the procedure mentioned above. In addition, acetone, ethanol, and isopropyl alcohol effectively remove and kill ticks from the external auditory canal (9).

CONCLUSION

Living objects should be kept in mind in the patients presenting with the symptoms of foreign bodies in EAC, particularly the living objects that lead to serious morbidity and mortality such as ticks that are mostly presented by people living in rural areas. To protect against ticks, individuals should obey the physical, environmental, and personal safety precautions and should prefer lighter-colored and, if possible, covered clothing. Prior to the removal of a tick in EAC, the EAC should be definitely examined by an otorhinolaryngologist; and the otorhinolaryngologist should also take personal measures to prevent the risk of complications. Doctors in endemic and rural areas should be more careful about this issue.

Informed Consent: Written informed consent was obtained from the patient who participated in this case.

Peer-review: Externally peer-reviewed.

Conflict of Interest: The author of this paper has no conflicts of interest.

Financial Disclosure: The author declared that this case has received no financial support.

REFERENCES

1. Yaroko A, Irfan M. An annual audit of the ear foreign bodies in hospital universiti sainsmalaysia. *Malays Fam Physician* 2012; 7(1): 2–5. eCollection 2012.
2. Iwasaki S, Takebayashi S, Watanabe T. Tick bites in the external auditory canal. *Auris Nasus Larynx* 2007; 34(3): 375–7. [\[CrossRef\]](#)
3. Olajuyin O, Olatunya OS. Aural foreign body extraction in children: a double-edged sword. *Pan Afr Med J* 2015; 20: 186. [\[CrossRef\]](#)
4. Keles E, Karlidag T, Isik O, Saki CE. Tick in the External Ear Track: Case Report. *Firat Tıp Derg* 2010; 15(2): 110–2.
5. Lee MY, Jung JY. A Case of Contrast Enhanced Cystic Mass of External Ear Canal Diagnosed as Engorged Hard Tick. *J Audiol Otol* 2018; 22(3): 167–9. [\[CrossRef\]](#)
6. Sung WJ, Kim YH. A Case of Engorged Female Hard Tick in the External Auditory Canal of an Infant. *Korean J Parasitol* 2017; 55(5): 565–8. [\[CrossRef\]](#)
7. Kularatne SAM, Fernando R, Selvaratnam S, Narampanawa C, Weerakoon K, Wickramasinghe S, et al. Intra-aural tick bite causing unilateral facial nerve palsy in 29 cases over 16 years in Kandy, Sri Lanka: is rickettsial aetiology possible? *BMC Infect Dis* 2018; 18(1): 418.
8. Ness B, Steger J, Della-Giustina D. “I can’t taste ice cream”: an unusual case of tinnitus and dysgeusia. *Pediatr Emerg Care* 2004; 20(12): 832–4. [\[CrossRef\]](#)
9. Orobello NC, Dirain CO, Kaufman PE, Antonelli PJ. Efficacy of common reagents for killing ticks in the ear canal. *Laryngoscope Investig Otolaryngol* 2018; 3(6): 492–5. [\[CrossRef\]](#)