



Tick-Borne Encephalitis in Kazakhstan: A Case Report

Saule Maukayeva , Saya Karimova 

ABSTRACT

Tick-borne encephalitis (TBE) exists over a wide geographical area worldwide. In here, a clinical case with TBE was presented. A 34 years old man complained of weakness, high fever with chills, body aches, headache, malaise. He was hospitalized in the Infectious Diseases clinic. He gave a history of the visit to an endemic area of TBE. Laboratory examination showed leukocytosis, neutrophilosis and ESR acceleration. Upon the clinical diagnosis of “Fever of unknown origin” levofloxacin and metronidazole, ceftazidime were started. On the third day of treatment, neurological symptoms of encephalitis developed. The patient was transferred to the intensive care unit. ELISA test for TBE virus IgM was positive. Cerebrospinal fluid (CSF) revealed serous meningitis. TBE was diagnosed. Treatment with human immunoglobulin TBE, glucocorticoid, and diuretics were administered. The outcome of the disease was favorable. The physicians should be aware about the clinical presentations of TBE in endemic areas.

Keywords: Tick-borne encephalitis, clinical case, epidemiology

INTRODUCTION

Tick-borne encephalitis (TBE) exists over a wide geographical area (1). Disease occurs throughout the northern hemisphere and mirrors the geographical distribution of the usual vector, Ixodes species ticks (2). Most cases occur in areas below an altitude of 750 meters (3). TBE is prevalent in forested areas of Europe and northeastern Asia and typically arises from infection involving one of three TBEV subtypes, namely the European (TBEV-Eu), the Siberian (TBEV-Sib), or the Far Eastern (TBEV-FE) subtypes (4). Tick-borne encephalitis is currently endemic in 27 regions of European countries (5). In the disease-endemic countries, the annual incidence of the disease ranges from <1 to >20 cases per year, per 100,000 population (6). Natural foci of tick-borne encephalitis are located in Central and Eastern Europe (e.g., Italy, France, Switzerland, Hungary, Poland, Germany, the Czech Republic, Slovakia and Albania). The Baltic countries and the Russian Federation are characterized by a tendency to expand risk zones and incidence increase. Asian countries with reported TBE cases or virus activity include China, Japan, Kazakhstan, Kyrgyzstan, Mongolia, and South Korea (3, 7, 8). In here, a clinical case with TBE was presented and summarized the distribution of TBE cases recorded in Kazakhstan.

CASE REPORT

A 34-year young man complained of severe weakness, fever (39,40 C) with chills, body aches, headache, malaise for three days in July. The onset of the disease was acute with headache, fever. Symptoms persisted despite taking Ibuprofen. The patient was hospitalized in the Infectious Diseases clinic in Ust-Kamenogorsk (East Kazakhstan). The case had no a history of infectious diseases. He gave a history of visit to an endemic area of tick-borne encephalitis for Week 6 days ago. On the admission, T was 37,10 C, the patient’s vital signs were normal. He was inactive and sluggish. Laboratory examination showed leukocytosis, neutrophilosis, and ESR acceleration (Table 1). Upon the clinical diagnosis of “Fever of unknown origin”, Intravenously, levofloxacin 500 mgx2 per day and Metronidazole 500 mgx2 per day, Ceftazidime 2,0x2 per day were started together with intravenous fluid infusions. On the third day of the treatment, agitation and confusion developed. The patient was transferred to the intensive care unit. The patient’s condition was severe and deteriorated. Neurological symptoms developed, including adynamia, tremors in the hands and nystagmoid. Sluggish in Romberg pose was seen. Finger nose test was present with a tremor in the left. The patient was asthenic, undefined neck rigidity was observed. Kernig symptoms were also positive. ELISA test for TBE virus IgM was positive. Cerebrospinal fluid (CSF) was slightly turbid, showed cytolysis with 489 leukocytes per mm³, with polymorphonuclear leukocytes 300 and mononuclear leukocytes 189 and protein 0,66g\l. Treatment with human immunoglobulin TBE 0,1 ml\kg twice for six days i\m, glucocorticoid, diuretics were administered. After three days of the therapy, the patient was transferred to

Cite this article as:
Maukayeva S, Karimova S.
Tick-Borne Encephalitis in
Kazakhstan: A Case Report.
Erciyas Med J 2020;
42(2): 226-8.

Department of Infectious
Diseases and Immunology,
Semey Medical University,
Semey, Kazakhstan

Submitted
19.12.2019

Accepted
25.12.2019

Available Online Date
01.04.2020

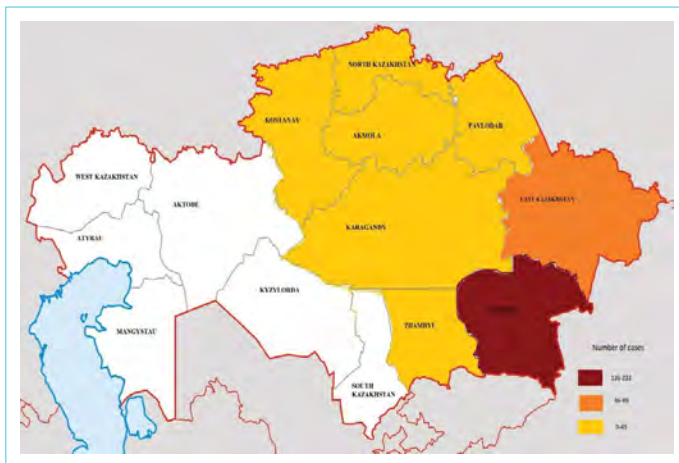Correspondence
Saule Maukayeva,
Department of Infectious
Diseases and Immunology,
Semey Medical University,
Semey, Kazakhstan
Phone: +87011069613
e-mail: solly66@mail.ru

©Copyright 2020 by Erciyas
University Faculty of Medicine -
Available online at
www.erciyesmedj.com

Table 1. A summary of the case laboratory test results according to hospital days

Laboratory test	Hospitalization days						
	1 day	3 day	4 day	5 day	6 day	7 day	13 day
WBC (X10 ⁹ /L)	19.2	12	12.2	7.9	7.4	11	12.7
Neutrophils (%)	86					81	54
Monocytes (%)	7.6					8	12
Lymphocytes (%)	6.4					11	34
Haemoglobin (g/L)	154	124	131	112	124	144	136
Thrombocytes (X10 ⁹ /L)	293	230	228	227	234	267	248
RBC (X10 ¹² /L)	4.87	4.03	4.19	3.74	4.01	4.29	3.95
Haematocrit	43.8					37	34.7
ESR (mm/h)	42	29	30	41	27	28	4
ALT (U/L)	28.79	22.1	52	25.1	28.3	33.3	67
AST (U/L)	21.22	62.1	26.7	67.71	57.9	54.4	37.1
Amylase (U/L)	61.9	61	52	52.5	55	34	47
Glucose (mmo/L)	6.53	5.6	8.8	5.1		4.96	4.4
Creatinine (mcmol/L)	86.09	75.45	58.25	72.36	74.71	96.4	100.7
BUN (mmol/L)	3.67	2.52	1.53	2.97	2.72	4.48	4.7
Protein (g/L)			66.41	54.24	57.2	60.5	
Tbil (mcmol/L)	16.27	8.0	9.0	13		9.76	13
TT (sec)		16	16.5	16.6	11.2	15.9	
INR		1.04	1.07	1.08	1.1		
Fibrinogen (g/L)		2.78	2.64	3.18	3.38		
APTT (sec)						31.8	

WBC: White blood cell count; ESR: Erythrocyte sedimentation rate; Tbil: Total bilirubin; TT: Thromboplastin time; APTT: Activated partial thromboplastin time; INR: International normalized ratio; BUN: Blood nitrogen urea

**Figure 1.** Distribution of tick-borne encephalitis in Republic of Kazakhstan

the Infectious Diseases clinic. Acute onset of symptoms, toxemia, meningoencephalitis syndrome, epidemiological history, inflammation in CSF, Positive ELISA test to TBEV supported a clinical diagnosis of tick-borne encephalitis with meningoencephalitis and severe form. The outcome of the disease was favorable. Patient consent was obtained for this study.

DISCUSSION

Active foci of tick-borne encephalitis verified by the isolation TBE virus have been established in Kazakhstan (Fig. 1). Almaty, East Kazakhstan regions and Almaty city with a population of 3 million 572.3 thousand people have a total area 500.1 thousand km². The share of these regions, including Almaty, accounts for 96.3±0.7% of the incidence of the republic. However, in the 1970s, TBE was recorded in other areas (North Kazakhstan, Pavlodar, Akmola and others), but in recent years, no cases were detected in these areas. TBE in Kazakhstan is characterized by sporadicity, and seasonality depends on the tick activity. The natural foci of tick-borne encephalitis in our republic belong to the mountain belt of the Tien Shan, Dzhungarsky and Zailiysky Alatau, Tarbagatai, the valleys of the Aksu, Tentek, Irtysh, Ulba and Bukhtarma rivers, characterized by lush vegetation and a high number of ixodid ticks. There are several independent endemic foci of tick-borne encephalitis in these territories: Zyryanovsky, Katon-Karagai, Leninogorsk, Sarkand, Talgar, Enbekshikazakh and others, separated by huge distances from each other (9). There are three types of foci of the disease: I type - natural foci in the wild; Type II - transitional foci with a changed composition of biocenosis components as a result of human activities; Type III - anthropogenic (secondary) foci in territories near settlements (10). The epidemiological situation of tick-

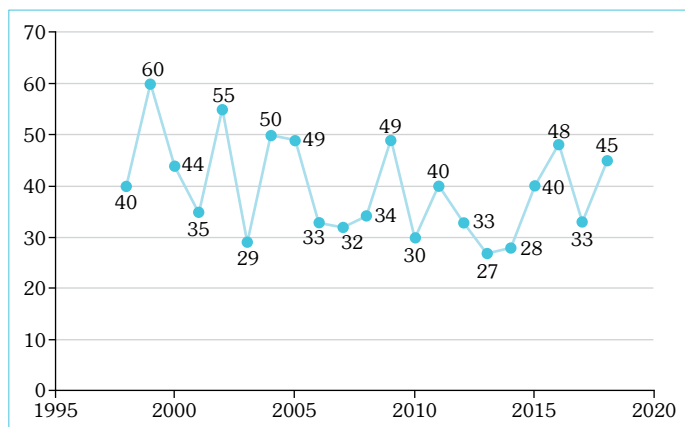


Figure 2. Cases of tick-borne encephalitis in the Republic of Kazakhstan

borne encephalitis in Kazakhstan remains tense. There is no downward trend in incidence. In Kazakhstan, from 22 to 60 cases of tick-borne encephalitis are registered annually (9). In recent years (1998–2018), 834 cases of TBE were reported in Kazakhstan (Fig. 2). The clinic of TBE is biphasic in 72% to 87% of the patients. In the fever-myalgia phase (or first phase), patients may present with fever (99%), fatigue (63%), general malaise (62%), headache and body pains (54%), nausea. Typical duration of this phase is five days (range 2–10 days). Following the fever-myalgia phase, there is typically a 7-day (range 1–21 days) symptom-free interval before the second phase. In the central nervous system (CNS) phase (or second phase), patients may present with mild meningitis to severe encephalitis, with or without myelitis and spinal paralysis; altered consciousness (approximately 33%); cranial and spinal nerve palsies (3% to 13%); cranial nerve involvement mainly associated with ocular, facial, and pharyngeal motor function (10). The typical duration of this second phase is 7 to 10 days. Improvement starts to occur spontaneously (11).

CONCLUSION

TBE in Kazakhstan spreads in Almaty, East Kazakhstan regions and Almaty city and characterized by the sporadic appearance and showing seasonal changes associated with the tick activity. The epidemiological situation of TBE remains a common public health problem in the certain part of Kazakhstan. There is not any decrease in the incidence. To successfully control tick-borne encephalitis, it is necessary to introduce a new prevention strategy, as a result of which mass vaccinations of the population of highly

endemic territories, emergency immunoglobulin prophylaxis, and acaricidal treatment will be carried out.

Informed Consent: Written informed consent was obtained from patients who participated in this study.

Peer-review: Externally peer-reviewed.

Author Contributions: Concept – SM; Design – SM; Data Collection and/or Processing – SK; Analysis and/or Interpretation – SM; Literature Search – SK; Writing – SK; Critical Reviews – SM.

Conflict of Interest: There is no conflict of interest in this study.

Financial Disclosure: The authors declared that this study has received no financial support.

REFERENCES

- Kaiser R. Tick-borne encephalitis. *Infect Dis Clin North Am* 2008; 22(3): 561–75. [CrossRef]
- Barlow G, Irving WL, Moss PJ. Infectious diseases and tropical medicine. In: Kumar P, Clark M, editors. *Kumar & Clark's clinical medicine*. 9th ed. London: Elsevier; 2016.
- Fischer M, Gould CV, Rollin PE. *Yellow Book*. Chapter 4 -Tickborne Encephalitis. July 2015. Available from: <https://wwwnc.cdc.gov/travel/yellowbook/2020/travel-related-infectious-diseases/tickborne-encephalitis>.
- Ruzek D, Avšič Županc T, Borde J, Chrdle A, Eyer L, Karganova G, et al. Tick-borne encephalitis in Europe and Russia: Review of pathogenesis, clinical features, therapy, and vaccines. *Antiviral Res* 2019; 164: 23–51. [CrossRef]
- Jelinek T. TBE—update on vaccination recommendations for children, adolescents, and adults. *Wien Med Wochenschr* 2012; 162(11-12): 248–51. [CrossRef]
- Hawker J, Begg N, Blair I, Reintjes R, Weinberg J, Ekdahl K. *Communicable disease control and health protection handbook*. 3rd ed. Oxford: Blackwell; 2012. [CrossRef]
- Shin AL, Egemberdieva RA. Clinical and epidemiological manifestations of tick-borne encephalitis in Kazakhstan. [Article in Russian] *Vestnik KazNMU* 2016; 2:48–5.
- Yu Z, Wang H, Wang T, Sun W, Yang X, Liu J. Tick-borne pathogens and the vector potential of ticks in China. *Parasit Vectors* 2015; 8: 24.
- Maykanov NS, Karagoysheva SK, Davletov SB, Akimaliev GS. Natural sites of tick-borne encephalitis in Kazakhstan. [Article in Russian]. *Periodicals of WKSU*, 2012.
- Lindquist L, Vapalahti O. Tick-borne encephalitis. *Lancet* 2008; 371(9627): 1861–71. [CrossRef]
- Taba P, Schmutzhard E, Forsberg P, Lutsar I, Ljøstad U, Mygland Å, et al. EAN consensus review on prevention, diagnosis and management of tick-borne encephalitis. *Eur J Neurol* 2017; 24(10): 1214–e61.