



This work is licensed under a Creative Commons Attribution-NonCommercial 4.0 International License.

Full Recovery of a Child with Fulminant Myocarditis after Levosimendan Therapy

Mustafa Argun¹ , Işın Sönmez² , Hasan Samsa² , Onur Yılmaz² , Mustafa Yılmaz³

ABSTRACT

Background: Fulminant myocarditis is a rare, life-threatening condition. Decompensated heart failure caused by fulminant myocarditis is managed with inotropic agents, mechanical ventilation, and mechanical circulatory support. Levosimendan is a novel inotropic agent that also has vasodilatory and cardioprotective properties. However, information about levosimendan use in children is limited in the literature.

Case Report: We report the full recovery of a 3.5-year-old male patient with an inotrope-resistant heart failure treated with levosimendan therapy who was diagnosed as having fulminant myocarditis after presenting with acute decompensated heart failure and low cardiac output.

Conclusion: Levosimendan therapy may offer an effective treatment for children with acute decompensated heart failure secondary to fulminant myocarditis resistant to standard therapy.

Keywords: Fulminant myocarditis, levosimendan, child

Cite this article as:
Argun M, Sönmez I, Samsa H, Yılmaz O, Yılmaz M. Full Recovery of a Child with Fulminant Myocarditis after Levosimendan Therapy. Erciyes Med J 2021; 43(5): 505-7.

INTRODUCTION

Fulminant myocarditis (FM) is a condition associated with a high mortality and morbidity risks, that results from myocardial inflammation mostly of viral origin and leads to acute heart failure (HF) (1). Herein, we report the case of a patient with severe HF resistant to other inotropics who was diagnosed as having FM on the basis of the presence of acute pulmonary edema and symptoms attributable to low cardiac output caused by acute HF. We also discuss levosimendan use in children with reference to available literature data.

CASE REPORT

A 3.5-year-old male patient presented to our clinic with cough and hoarseness. On physical examination, his general condition was good. He had stridor but had otherwise normal breath sounds on auscultation. His heart rate was 140 bpm and blood pressure was 85 (25th–50th percentile)/55 mmHg (50th–90th percentile). He underwent close follow-up and received cold vapor, oxygen by mask, intravenous (IV) dexamethasone, IV fluid, and vital sign monitoring. However, he developed dyspnea, tachypnea, and sinus tachycardia later in the clinical course. As arterial blood gas analysis revealed decompensated respiratory and metabolic acidosis, and he developed bradycardia, he was intubated and connected to a mechanical ventilator 6 hours after admission. His posteroanterior chest radiography revealed diffuse consolidation consistent with pulmonary edema and cardiomegaly. His electrocardiogram showed sinus tachycardia and ST depression, and T negativity at II, III, aVF, and V₄₋₆ derivations (Fig. 1). Transthoracic echocardiography (TTE) revealed left ventricular dilatation, second-degree mitral regurgitation, severe left ventricular systolic dysfunction (EF; 37%), and normal coronary artery origin. The troponin level was 2.3 ng/ml (normal range, 0–0.1 ng/ml); and N-terminal B-type natriuretic peptide (NT-pro BNP) level, >35,000 pg/dl (normal range, 0–125 pg/ml). Adrenaline (0.1 µg/kg/min infusion) and milrinone (50 µg/kg loading dose over 60 minutes followed by 0.5 µg/kg/min infusion) were administered as inotropic support; IV furosemide (1 mg/kg/dosage 2 or 3 times a day) and spironolactone (1 mg/kg/day dosage) via a nasogastric tube for diuretic treatment; and methylprednisolone (1 mg/kg/day IV) and IV immunoglobulin (1 gram/kg) therapy for immune system modulation. The polymerase chain reaction examination of a nasal swab sample revealed influenza A positivity. Oseltamivir phosphate therapy was commenced via an oral route as antiviral treatment. The patient later developed ventricular tachyarrhythmias treated with IV amiodarone and cardioversion. Despite all the above-mentioned therapies, the patient had persistent tachycardia. In addition, he developed oliguria, worsened renal function, and persistently reduced cardiac systolic function. Therefore, he was treated with levosimendan (12 µg/kg loading dose over 10 minutes followed by 0.1 µg/kg/min infusion for 24 hours) on the third day of admission. His left ventricular systolic function began to recover 24 hours after levosimendan loading. His reduced urine output increased clinically, and

Submitted
20.09.2020

Accepted
03.11.2020

Available Online
04.08.2021

Correspondence

Mustafa Argun,
Health Sciences University
Faculty of Medicine, Kayseri
City Training and Research
Hospital, Department of
Pediatric Cardiology,
Kayseri, Turkey
Phone: +90 352 315 77 00
e-mail:
dr.margun@hotmail.com

©Copyright 2021 by Erciyes
University Faculty of Medicine -
Available online at
www.erciyesmedj.com

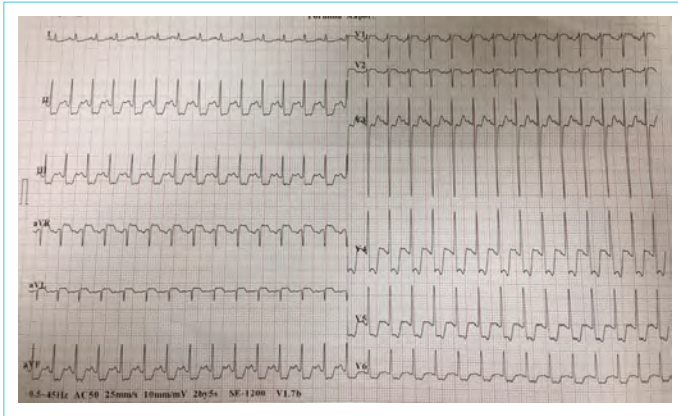


Figure 1. Electrocardiogram showing sinus tachycardia, ST depression, and T negativity at the II, III, aVF, and V₄₋₆ derivations

the signs of pulmonary and systemic congestion and tachycardia subsided. He was extubated on the seventh day of mechanical ventilation. His inotropic support was tapered and then stopped. At the end of the second week, a TTE examination showed normal systolic cardiac function and no valvular regurgitation. Cardiac MRI examination and catheterization procedure were not required. The patient was discharged as cured and sent home with a prescription of oral amiodarone treatment for ventricular tachycardia prophylaxis. Informed consent was obtained from the family.

DISCUSSION

The main cause of acute myocarditis in children is viral infections. Enterovirus, adenovirus, parvovirus, and herpes virus are the most common pathogens (2). While influenza A is known to be a rare etiological cause of acute myocarditis, Matsuura et al. (3) reported that it was one of the most common pathogens among 50 children with myocarditis in whom the causative virus was identified. Patients with FM may present with acute decompensated HF, cardiogenic shock, ventricular arrhythmia, or cardiac arrest. In children with FM, cardiovascular collapse has been reported as the main cause for performing cardiopulmonary resuscitation and mechanical ventilation use (4). The mortality rates in acute FM are much higher than those in acute myocarditis. Moreover, a significant proportion of those who survive will develop dilated cardiomyopathy, where heart transplant will be the ultimate treatment option (5).

DiFlippo (2) reported that a better understanding of pathological mechanisms, using novel diagnostic techniques, applying target-oriented therapies, and using mechanical circulatory support may improve the prognosis of children with myocarditis. In addition to the approach, we opine that myocarditis should be kept in mind in differential diagnosis to prevent diagnostic delay and that appropriate selection of inotropic agents with favorable effects on hemodynamics for treatment would contribute to improved survival rates.

FM should be considered in the differential diagnosis of cases with signs such as disproportionate tachycardia as compared with respiratory distress, respiratory difficulty, hepatomegaly, low cardiac output, high NT-pro BNP and troponin I levels, ST-T changes in ECG, and cardiomegaly and pulmonary edema on posteroanterior chest radiography.

We initially preferred to use milrinone, an effective inotropic agent that also possesses vasodilator and lusitropic actions, and adrenaline, an inotrope with vasodilatory effects at lower doses and vasoconstrictor action at higher doses (>0.1 µg/kg/min). Hence, we aimed to lower afterload by reducing the systemic vascular resistance already heightened in HF to exert an inotropic action on severely reduced cardiac systolic function. Although we applied a loading dose of milrinone, we did not observe hypotension, which is a possible side effect of the therapy.

We are of the opinion that in cases with persistently decompensated HF resistant to standard therapy, full clinical recovery achieved after administering levosimendan may be a result of the mechanism of action of levosimendan, which is distinct from those of the other medications used, and of a synergistic action with those medications.

Levosimendan exerts an inotropic action by increasing the sensitivity of troponin C to calcium in myocardial cells and a vasodilator action by opening adenosine triphosphate-sensitive potassium channels in smooth muscle cells. In addition, experimental studies have shown that it effectively protects myocardial cells by opening adenosine triphosphate-sensitive potassium channels in mitochondria (6). In conclusion, levosimendan administration augments contraction without affecting ventricular relaxation and increasing myocardial oxygen consumption while augmenting cardiac output by reducing systemic vascular resistance. Currently, the levosimendan pharmacokinetics in children is not well known (7).

Few studies about levosimendan use in children have reported good tolerance of the medication, and only transient hypotension and tachycardia may have developed at the beginning of infusion (8). Pedrosa et al. (9) reported that they achieved safe and effective outcomes when they administered levosimendan without a loading dose in 32 patients assigned to three different groups, namely those who had received cardiac surgery, those who had severe HF due to dilated cardiomyopathy, and those with severe HF secondary to other causes. Kushwah et al. (10) reported a similar improvement as in our case after levosimendan use in a 12-year-old girl with HF refractory to standard therapy.

CONCLUSION

Levosimendan therapy may offer an effective treatment for children with acute decompensated HF secondary to FM that is resistant to standard therapy. We believe that more experience about the use of the drug would broaden the range of clinical indications for its use and thus may minimize the need for mechanical circulatory support.

Informed Consent: Written informed consent was obtained from patients who participated in this study.

Peer-review: Externally peer-reviewed.

Author Contributions: Concept – MA; Design – MA, IS, HS; Materials – MA, HS, IS, MY; Analysis and/or Interpretation – MA, MY; Literature Search – MA, IS, OY; Writing – MA, IS, OY; Critical Reviews – MA, MY.

Conflict of Interest: The authors have no conflict of interest to declare.

Financial Disclosure: The authors declared that this study has received no financial support.

REFERENCES

1. Howard A, Hasan A, Brownlee J, Mehmood N, Ali M, Mehta S, et al. Pediatric myocarditis protocol: An algorithm for early identification and management with retrospective analysis for validation. *Pediatr Cardiol* 2020; 41(2): 316–26. [\[CrossRef\]](#)
2. Di Filippo S. Improving outcomes of acute myocarditis in children. *Expert Rev Cardiovasc Ther* 2016; 14(1): 117–25. [\[CrossRef\]](#)
3. Matsuura H, Ichida F, Saji T, Ogawa S, Waki K, Kaneko M, et al. Clinical features of acute and fulminant myocarditis in children- 2nd Nationwide survey by Japanese Society of Pediatric Cardiology and Cardiac Surgery. *Circ J* 2016; 80(11): 2362–8. [\[CrossRef\]](#)
4. Şık G, Annayev A, Demirbuğa A, Deliceo E, Aydın S, Erek E, et al. Extracorporeal membrane oxygenation for the support of pediatric patients with acute fulminant myocarditis. *Turk J Pediatr* 2019; 61(6): 867–72. [\[CrossRef\]](#)
5. Veronese G, Ammirati E, Cipriani M, Frigerio M. Fulminant myocarditis: Characteristics, treatment, and outcomes. *Anatol J Cardiol* 2018; 19(4): 279–86. [\[CrossRef\]](#)
6. Farmakis D, Alvarez J, Gal TB, Brito D, Fedele F, Fonseca C, et al. Levosimendan beyond inotropy and acute heart failure: Evidence of pleiotropic effects on the heart and other organs: An expert panel position paper. *Int J Cardiol* 2016; 222: 303–12. [\[CrossRef\]](#)
7. Wang A, Cui C, Fan Y, Zi J, Zhang J, Wang G, et al. Prophylactic use of levosimendan in pediatric patients undergoing cardiac surgery: a prospective randomized controlled trial. *Crit Care* 2019; 23(1): 428. [\[CrossRef\]](#)
8. Nieminen MS, Fruhwald S, Heunks LM, Suominen PK, Gordon AC, Kivikko M, et al. Levosimendan: current data, clinical use and future development. *Heart Lung Vessel* 2013; 5(4): 227–45.
9. Vilaboa Pedrosa C, Martínez Roca C, Yáñez Gómez P, Martín Herranz MI. Experience with levosimendan in 32 paediatric patients. *Pediatr Cardiol* 2015; 36(5): 1038–41. [\[CrossRef\]](#)
10. Kushwah S, Kumar A, Sahana KS. Levosimendan. A promising future drug for refractory cardiac failure in children?. *Indian Heart J* 2016; 68(Suppl 1): S57–S60. [\[CrossRef\]](#)